

A Rare Case of Myopathy

Afatih E.M Ahmed¹, F.A.E Suliman², Michael Smith³



Abstract:

A young Saudi lady presented with gradual worsening of muscle weakness and skeletal stiffness. Her sister has a similar condition. The clinical picture was very consistent with diagnosis of Rigid Spine Syndrome. This impression was further substantiated by the result of muscle biopsy.

This syndrome was not clearly understood and probably not so rare either. This negative picture was basically imposed by under reporting and lack of large studies.

Key words: Rigid Spine Syndrome, Saudi Arabia.

Introduction

Rigid Spine Syndrome [RSS] is relatively new disease consisting mainly of proximal muscle weakness as an initial presenting feature¹. Later on the disease evolve leading to progressive limitation of trunk and neck movement. Various means of inheritance² and histological patterns had been described³. Beside its effect on movement the syndrome usually cause skeletal deformity which ultimately jeopardize breathing and may cause serious cardiac arrhythmias⁴.

This may be the first case from Saudi Arabia and other Arab countries.

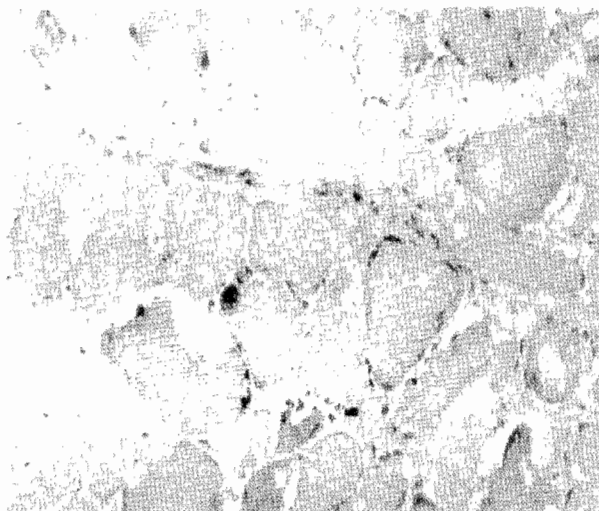
A 19 year young Saudi lady presented with progressive shortness of breathing for some years. She was born normally after full term pregnancy. Early in her childhood she was noted to have limited mobility of the neck otherwise had normal milestones till she was eight years old, when she started to develop progressive kyphoscoliosis, muscular weakness and atrophy. This gradually affected her mobility then breathing over the years. When seen she could only walk few steps using Zimmer's frame and connected to a portable home ventilator from which she can wean herself maximally one hour a day. She had spinal surgery in attempt to rectify her kyphoscoliosis in a reputable center in USA but unfortunately with little success.

Nevertheless with this limitation, this young lady has attended school with excellent academic results emphasizing the supportive role of the family.

Her elder sister has a similar problem with severe kyphoscoliosis and muscle weakness but was less handicapped as she could walk unaided and needed the ventilator only during sleep.

Her paternal grandmother had limited mobility of her neck but the rest of the family members were normal.

Fig. Muscle biopsy showing mixture of atrophic muscle fibres and cytoplasmic vacuolations. The connective tissue is not increased (EVG 400x)



The clinical course of this patient and her family presented the typical picture of rigid spine syndrome. The histopathology of her muscle biopsy which was taken intraoperatively in USA supported the diagnosis. It showed reduction of type II fibers, cytoplasmic vacuolation and inflammatory infiltrate with mononuclear cells. Other investigations CBC, ESR, LFT, Urea, Electrolytes, CPK and LDH were all normal, she refused EMG, and also the family refused screening with EMG and muscle enzymes.

1. Consultant General & Respiratory Physician. Military Hospital – Omdurman, Sudan.

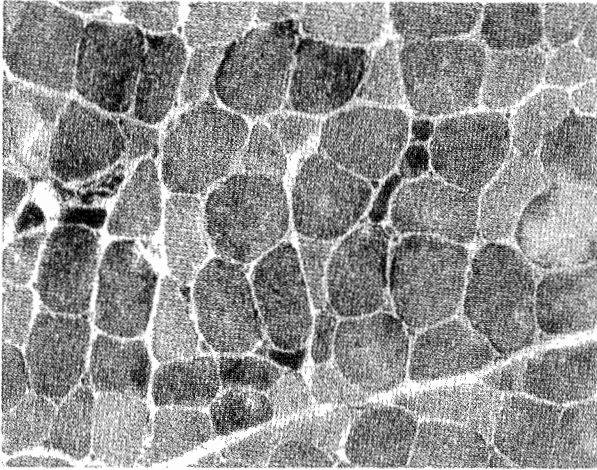
2. Consultant General & Cardiology Physician. Ahmed Gasim Hospital Sudan

3. Consultant Spinal Surgeon Suite 602. Riverside Professional Building 606 24th AVE. South Minneapolis Minnesota 5545-1499

Correspondence to: Dr. Afatih E.M Ahmed, P.O Box 1353. Khartoum North. Sudan

E.mail: Elfateha@yahoo.com

Fig. Muscle biopsy showing mostly darkly stained type 1 fibres. Very few type 2 fibres (lightly stained fibres) are seen. (NADH, 400x)



penetrance² as demonstrated by our case history. It usually presents with muscle weakness which commonly involves the distal muscles, but the proximal groups may also be affected. Breathing is usually affected due to kyphoscoliosis. However, serious consequences will arise when respiratory muscles become involved. Patients could easily develop type 2 respiratory failure following chest infections⁵. Muscle biopsy usually shows protean histological features like increase of inclusion bodies in the cell cytoplasm some muscles necrosis with fibrosis, other feature in disproportion of the muscle fibers e.g increase in type I and lack of type II fibres^{5,6}.

Because different ways of presentation were described, it has been suggested that the rigid spine syndrome may represent different patterns of diseases rather than a single entity. Examples of the various ways of presentations are

fatal cardiomyopathy⁷, selective respiratory muscles involvement with relative sparing of other muscles group. Other rare feature is the association with enzymatic deficiency like acid maltose⁸. Like most other myopathies specific treatment is not available and management is largely supportive. The prognosis depends on the severity of muscle and other organs involvements.

Conclusion

This syndrome is probably more common than people think. Its true nature and etiology remains unclear which emphasize the need for further research.

References

1. Dubowitz V. A muscle syndrome in search for a name Proc-R-Soc-Med. 1973 66(3):219-20
2. Vaneste JA, August IJN. The rigid spine syndrome in two sisters; J. Neurol, Neurosurg, psychiatry. 1988 Jan, S1 (1): 131-5.
3. Efthimiou J, McLelland J, Round J, et al, Diaphragmatic paralysis causing respiratory failure in an adult with rigid spine syndrome. Am Rev Respir dis 1987; 136 (6): 1583-5
4. Poewe W, Willeit H, Sluga E, et al. The rigid spine syndrome—a myopathy of uncertain nosological position. J Neurol Neurosurg Psychiatry 1985;19:105-108
5. Ras GJ, Van Staden M, Shults C et al. Respiratory manifestation of RSS. Am J Respir crit care Med 1994; 150 (2): 540-6
6. Lorio-G, Lus-G, Cutillo C, et al. Histopathological and heterogeneity and cytopathological similarity in different muscles of two brothers with rigid spine syndrome. J Neuro Sci 1989 ; 94:107-14
7. Khan Y, Heckmoh, JZ, Dubowitz VA. Supportive ventilatory treatment in patient with muscle disorders. Arch Dis Child 1986; (74): 195-2
8. Fadic R, Waclawik Aj, Brook BR. Rigid spine syndrome due to acid maltase deficiency. Bibliography circulation – Muscle and nerve 1997; 20(3):364