

## Use of Diode Laser (810) nm In Frenectomy Awooda E M<sup>1</sup>, Osman B<sup>2</sup>, Nadia A Yahia<sup>3</sup>

### Abstract

**Introduction:** Frenula consist of a mucosal fold in the labial, buccal and occasionally the lingual surface of the alveolar ridge. Their high attachment may cause orthodontic problem eg. (Diastima), prosthodontic problems eg. (Poor retention of denture), periodontic problems (gingival recession and inflammation) and speech problem (tongue tied in ligual frenum). The removal of frenum could be done by surgical excision using scalpel through different techniques eg. (Vertical, Z plasty and hemostat). Modern technology now offers an alternative mode of treatment like laser surgery .

**Material and Method:** eight patients (14-75 years old) with freni indicated for excision were referred for laser clinic in police hospital . Laser used was diode with wavelength (810) nm (Oralaser Jet 20 - Germany ), energy 1.8 Jul/sec and frequency 10,000 Hz using PPR1 (pulse pause relation) program with fiber tip diameter of 400 micron in contact mode. Laser safety measures were followed.

**Results:** showed dry and bloodless field during operation, no post operative swelling, no pain or discomfort, with normal healing process.

**Conclusion:** as these were first cases to be treated by laser in Sudan, we suggest and stimulate the use of laser for soft tissue surgery because of its time saving, patients comfort and easy manipulation.



### Introduction

Frenum consists of mucosal folds in the labial, buccal, and occasionally the lingual surface of the alveolar ridge, they act as flexible checkreins limiting the movement of the lips, cheeks and sometimes the tongue<sup>1</sup>. The proceedings of the World Workshop in Clinical Periodontics have outlined the rationale for the use of frenectomy<sup>2</sup>. It should be considered in areas where there are restrictive problems associated with lip and tongue movement, closure of midline diastema due to orthodontic treatment<sup>3</sup>, purely aesthetic problems, attachments in edentulous ridges compromising prosthesis, pulling gingiva lead to inflammation and pocket formation and tongue tie leading to speech problem<sup>1</sup>. Until recently the classical or conventional frenectomy (surgically by scalpel and suturing) was the only way to remove the aberrant frenum. Modern technology now offers an alternative mode of treatment, like laser surgery<sup>4</sup>.

The word laser is an acronym for Light Amplification by Stimulated Emission of Radiation. The hypothetical origins and conceptual basis of a laser were initiated by Einstein in 1917<sup>5</sup>. When laser light incident on a tissue surface, it can be reflected, scattered, absorbed or transmitted<sup>6</sup>.

There are different types of lasers according to their different wavelengths and their interaction with tissues. They can be used for hard and soft tissues in oral cavity. In soft tissue procedures (gingivectomy, frenectomy, lesion removal) CO<sub>2</sub>, Nd:YAG, Argon, Er:YAG and Diode laser were used<sup>7,8</sup>. Diode laser is a semi conductor (Gallium Aluminum Arsenide (GA Al As) used in surgery. It emit coherent monochromatic light of wavelength between (810-900) nanometer i.e. near infrared. This radiation is absorbed in dark media, as in hemoglobin and therefore has a remarkable surgical cutting efficiency in well vascularised tissues<sup>9,10</sup>.

The main objective of this study is to use Diode laser (810 nm) in frenectomy. Specific objectives to evaluate cutting efficiency, post operative pain, swelling and healing process.

### Materials and Methods

In this study eight patients were included, four females and four males, age range between 16-75 years. They were selected randomly as they were referred for frenectomy as indicated for gingival and periodontal problem (gingival recession) in two cases, prosthetic problem (Retention and stability of complete denture) for five cases and one case with tongue tie. They were referred from different Dental Departments in Police Hospital.

All the treatment done in Police Hospital ( Laser Clinic) from February to July 2005 by the first author.

### Methods

Medical and Dental history were taken. Verbal and written consents were given to all patients and they accepted the treatment.

1. Lecturer in Restorative Dentistry. Academy of Medical Science and Technology. Faculty of Dentistry.

2. Assistant Prof. LASER PHYSICS, Sudan University of Science and Technology.

3. Associate Prof. Faculty of Dentistry U of K

Correspondence: Elhadi M.Awooda. e-mail:

DR.Alhadi@yahoo.com

pain a local anesthesia may be administered. After excision no sutures were used, no wound dressing or pack was applied; no medicament or analgesics were prescribed.

**Diode Laser 810 nm:**

The laser device used in the study was the *Ora-laser Jet-20* (Germany). It is (Ga Al As) diode-laser emitting 810nm. Maximum out-put power was 20 watt.

**Laser parameters in the study were:**

Glass fiber 400 µm diameter, power 20 watt at fiber tip, energy 1.8 Joule/sec , frequency 10,000Hz, cutting efficiency and intra operative appearance was monitored.

Follow up was done for three days, one and four weeks. Photographs were taken for all visits to see the difference.

All patients' individual postoperative pain was evaluated. Clinical aspects of wound healing were evaluated. Safety measures were taken for Dentist, assistance and patient by wearing the recommended protective goggles.

**Results**

Descriptive results as shown in photographs 1& 2

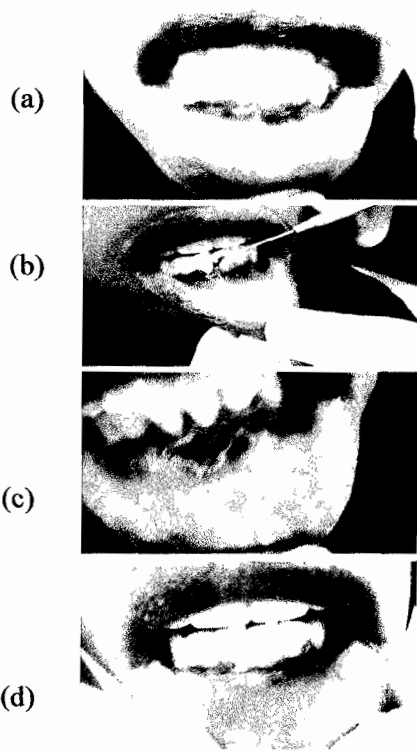


Fig 1: 14 years old female with lower labial frenum causing gingival inflammation and recession; removed by (PPR1) program Diode laser. (a and b) Preoperative. (c) Postoperative, (d) seven days postoperatively.

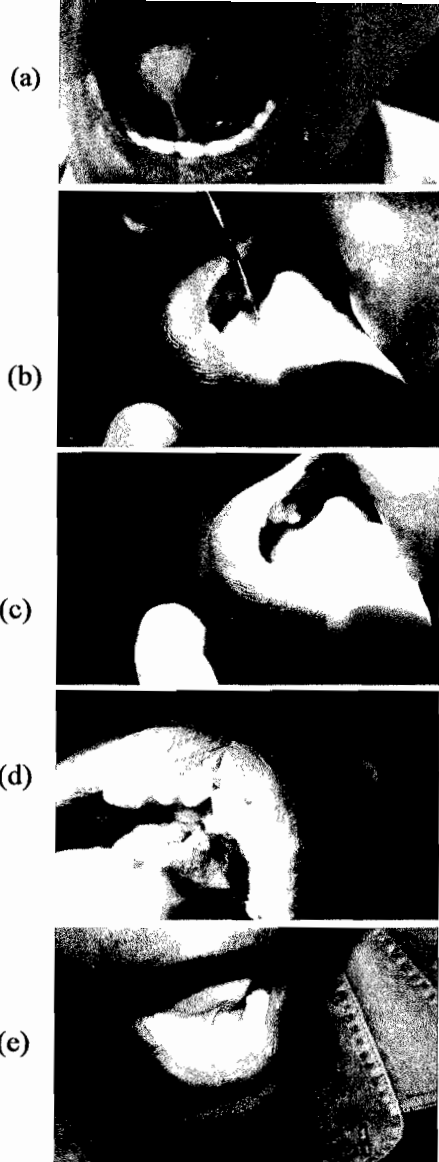


Fig 2: 16 years old male with lingual frenum causing tongue tie. Laser frenectomy by PPR1 program and tip fiber 400 microns. (a) preoperative (b) during operation (c) postoperatively. (d and e) seven days postoperatively.

**Operative findings:**

The tissues have a very bright aspect and charring was significantly less visible. All patients showed sufficient coagulation in cutting region. No bleeding occurred during the procedure. No pain during operative procedure for all groups.

**Post operative:**

All patients reported of no or minimal postoperative pain or discomfort except for two patients, one experienced pain after the first day and pain and swelling for the other one. After three days all wounds had fibrin layers .The above

two cases showed redness in the periphery of the wound. At one week follow up we found good wound healing with faster epithelisation rate.

After four weeks the excision sight could not be distinguished. Scarring was not visible.

### Discussion

Photo thermal interaction with the tissue is the basis of surgical laser. In this process radiant light is absorbed by the tissue and transformed to heat energy changing tissue structure<sup>11</sup>. The amount of light absorbed depends on a number of factors such as wavelength of laser radiation, output power at the laser tip, optical properties and composition of the target tissue<sup>9</sup>. This laser machine with 20 watt and 10.000 Hz pulsation gives different energy values, like 6.6 Joules/sec. has the best cutting momentum, and 3.3 Joule/sec and 2.5 Joule/sec were similar but 1.8 Joule/sec showed slight slower speed but high output at fiber tip which helps cutting efficiency<sup>12</sup>. For the treated cases we used energy of 1.83J/second that gave best dry field (no bleeding) with good cutting efficiency and decreased post operative (d) complications. While bleeding in conventional method (scalpel) obscure the operative field and increases the fear of surgery especially in children and patients with bleeding disorders. As a result of the ability to perform the treatment without inflicting pain, it is an essentially stress free procedure for both the patient and the clinician. There was no postoperative pain the patient did not require a prescription for analgesic, unlike conventional way where there is postoperative pain duo to damaging effect of scalpel, suturing, edema and swelling . The pain and discomfort that was experienced by two of our patients could be due to secondary infection this is similar to the results found in the study done by Mereer<sup>13</sup>, they were treated by antibiotic and analgesic. There was no need to place sutures or pack, this decreased the need for postoperative visits. These results were similar to the findings of pick<sup>8</sup>. Regarding absence of scarring, one of the mechanisms suggested for the associated reduction in scarring is the slightly prolonged healing time while healing in conventional surgery is faster this is similar to the study conducted by Fisher<sup>14</sup>.

### Recommendation

In our opinion whenever indicated frenectomy should be performed via laser therapy, it has clinical relevance and sound biologic rationale that offers significant benefits to the patient and to the Dentist. More training and workshops are needed in this field of treatment.

### Acknowledgment

Great thanks and appreciation for the Institute of Laser (Sudan University of Science and Technology) for their laser device, special thanks to Prof. Nafia Abdu Allateef, Dr Mobarik Almahal and Dr. Ahmed Sabah Alkeer for their great help.

### References

- 1- Daniel W. Soft Tissue Surgery. Lee F. Text Book of Practical Oral Surgery. Philadelphia, 1972 : (1) 192-197.
- 2- Proceeding of workshop on Clinical Periodontics. VII – 19.July 1989, Prenceton, Newjersy.
- 3- Grabber T M. Orthodontics principles and practice .W.B. Saunders Co., 1966 p. 352.
- 4- Epstein S R, Stuart R. The frenectomy: Comparison of classic versus laser technique .Practical Periodontic and Aesthetic Dentistry 1991. 3(5): 27-30.
- 5- Catone G A. and Alling C.C. Laser application in Oral and Maxillofacial Surgery. 1997. W. B. Saunders Company, Philadelphia.
- 6- Dederich D.N, Laser tissue interaction. JADA 1993; 124 (2) 57-61.
- 7- Weesner B .W. Laser in Dentistry (Hand out for American Association for Dental Research). 1998.
- 8- Pick RM, Colvard MD. Current status of laser in soft tissue dental surgery. J Periodontol 1993; Jul; 64(7): 589-602.
- 9- Fisher JC: Qualitative and Quantative tissue effects from important surgical laser. Laser Surg Gyn 1993; (1) 58-81.
- 10- Gontijo I., Navarro RS, Hypek P, Ciamponi AL and Hadded AE. The application of diode laser and Er:YAG laser in labial frenectomy in infant patients. J Dent Child (Chic) 2005; 72 (1):10-5.
- 11- Carruth J A , McKenzie A L :The production of Surgical laser lesions . Science and Clinical Practice 1985; I :51-80.
- 12- Gutknecht N, Van Gogswaurdt D., Conrads ,G., et al. Diode laser irradiation and its effect in Root Canal and Wall Dention. Clin Laser Med Surg 2000; 18: 57-60.
- 13- Mereer ,C . (1) 1996 Laser in Dentistry: A Review Part I .Dental Up Date: vol 23 (2): 74-80.
- 14- Fisher S .E, Frame J.W., Brown, R.M et al. A comparative histological study of wound healing following CO2 laser and conventional surgical excision of canine buccal mucosa. Arch Oral Biol 1983; vol 28: 287- 291.