

Evaluation of Azithromycin in Treatment of Acne Vulgaris Compared to Doxycycline

Ibrahim S¹, Sania A I Shaddad², Elkhalfa O S³, Abdelmarouf H M⁴

Abstract

Introduction: Acne vulgaris is the most common dermatological disorder in adolescence. Treatment is essential to prevent physical and psychological scarring. Although many treatments for acne are available, effective management has become increasingly challenging with the emergence of antibiotic-resistant strains of *Propionibacterium acnes*.

Aim: The aim of this study is to evaluate the efficacy of oral azithromycin in acne by comparing its effect with the most common therapy used for acne; doxycycline.

Method: An opened label randomized comparative study was carried out in 40 patients of mild, moderate and severe acne vulgaris divided into two groups, group (A) 20 patients received azithromycin capsules in a specified and scheduled dose regimen and group (B) 20 patients administered doxycycline tablets as a usual regimen of therapy.

Results: The results obtained from oral azithromycin therapy when compared with oral doxycycline showed that there was statistically no difference between the two drugs in response at end of 22 weeks. The overall efficacy measured in terms of reduction of the severity of condition was up to 83% with azithromycin compared to 50% with doxycycline. In assessment of adverse effects and dropped-out rates the higher dropped-out rate was found in doxycycline group. Also the patients' opinion as an outcome measure confirmed that most of patients felt much better with azithromycin.

Conclusion: The conclusion from the present study is that oral azithromycin provides additionally effective and safe treatment option to the patients, and benefits may be further extended to those patients not responding to currently recommended antibiotic therapy.

Key words: skin; pilosebaceous; *Propionibacterium acnes*, management.



Introduction

Acne vulgaris is a skin disorder of the pilosebaceous of the face, chest and back that generally develops in adolescence and improves in adulthood. The lesions usually start as open or closed comedones and evolve into an inflammatory papules and pustules that either resolve as macules or become secondary pyoderma, which result in various sequelae. Effective treatment is essential to prevent physical and psychological scarring.

Doxycycline and erythromycin are the classical regimen of therapy. Azithromycin is a relatively new macrolide antimicrobial agent¹. Pharmacokinetic properties of azithromycin include: good absorption, extensive distribution into tissues and a high concentration within cells (including phagocytes); these result in a much greater tissue concentration, and penetration when

compared to doxycycline. Based on side effects profile and drug interactions doxycycline has many limitations in use in pregnant females, planning pregnancy or nursing a child. Also it has higher toxicity than azithromycin especially when managing acne which required long term treatment (at least 6 months)².

Objectives

The objective of this study is to evaluate the effect of oral azithromycin as compared to doxycycline in treatment of acne vulgaris.

Materials and methods

This study was carried out during the period from March to September 2003 in the Dermatology Department, Omdurman Teaching Hospital-Sudan. Forty adolescent and post-adolescent (aged between 16-40 years) patients suffering from inflammatory acne vulgaris were randomly selected from a pool of patients with the same disease coming to the dermatology clinic. Females who were pregnant or nursing children and patients with history of hypersensitivity to tetracyclines or macrolides antibiotics were excluded.

Assessment of acne severity

Clinical examination to assess the severity of acne was done for each patient by a dermatologist. Assessment of severity grading (mild; moderate; or severe)³, was done by observing each type of facial lesions and how it spread in face, chest and back.

1. Lecturer, Faculty of Medicine, Department of Biochemistry and Pharmacology, Omdurman Islamic University, Khartoum, Sudan.

2. Assistant Professor, Head department of pharmacology, Faculty of Pharmacy University of Khartoum.

3. Associate Professor of dermatology, Elnelein University, Faculty of Medicine, Senior Dermatologist, Federal Ministry of Health.

4. Assistant Professor Department of Biochemistry and Pharmacology, Faculty of Medicine, Omdurman Islamic University, Khartoum, Sudan.

Correspondence;

Dr. Salah Eldin Ibrahim . E-mail: Isra-su@hotmail.com.

Drug administration policy

Patients were randomly assigned into two groups; Group (A) received azithromycin as 250mg tablets daily for 3 weeks, then 250mg every other day for 5 weeks then 250mg every 4 days for 2 months, then 250mg once a week⁴. Group (B) received doxycycline tablets 100mg daily throughout the period of the study.

Response evaluation and outcome measures

After the initiation of treatment patients were seen every fortnight to assess their response in comparison to the baseline assessment.

Global assessment was performed at week 22 (visit 11) using 4 point scale as shown in table 1⁵.

Table 1 explanation of abbreviation and corresponding scales:

Abbreviation	Scale	Explanation
R.R	-1	Relapse Response means the case relapsed after improvement or worsened There is exacerbation in the quantitative assessment of lesions.
N.R	0	No Response means that a shows no change.
W.R	1	Weak Response means that there is slight improvement quantitative assessments of lesions.
G.R	2	Good Response and indicate that there is a clear improvement in quantitative assessment of lesion or no lesions.

Data analysis and treatment:

Data was analyzed using SPSS. Significance was taken at P <0.05.

Results

Assessment of the response:

The mean of response to therapy for group (A) was compared with that of group (B) at every other visit (Fig 1). The graph was going smooth for group (B) from visit 2 to 10, while it is not so for group (A). The mean response was increased for group (A) at the end of the visits (visit 11 & 12) while it was decreased for group (B) at the same visits.

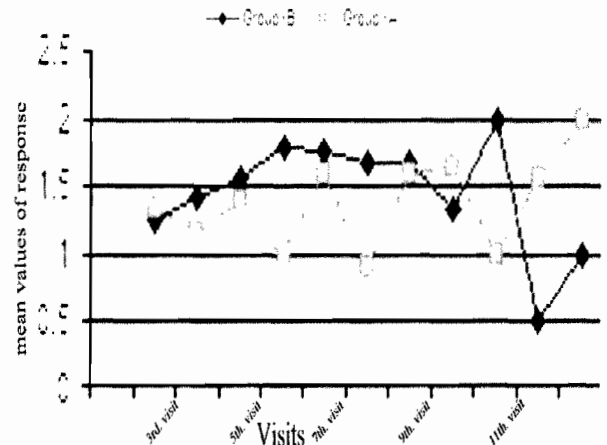


Fig1. Comparison of mean values of response distribution between two groups per each visit:

The mean of responses for group (A) was 1.37 ± 0.343; while that of group B was 1.45 ± 0.42 with no significant difference (P = 0.084).

Assessment of the severity grade improvement:

Changing the severity grade indicate the efficacy of treatment. This is shown in table (2).

Table 2: The severity in both groups decreased significantly from the baseline to the visit 12 (P <0.05).

	Group (A) N=18	Group (B) N=15
Baseline severity (X±SD)	2.46±0.66	2.20±0.63
After treatment (X±SD)	1.39±0.37	1.49±0.41
P	0.01	0.017

Evaluation of photographs

Colored photographs were taken for some patients pre- and post-treatment for both groups in order to compared and evaluate the response to therapy. Some reduction in the severity grade after treatment for both group therapy especially in group (A) as was observed independently by more than one observer unaware of the type of treatment prescribed (Fig 3 and Fig 4) .

Adverse effects and drop-out rates assessments:

One (5.6%) patient from the azithromycin group had gastritis, and one (6.7%) patient from doxycycline group complained of nausea and vomiting, but both patients continued the treatment.

We observed the higher percentage rate of drop-out in group (B) compared to group (A), 25% and 10% respectively.

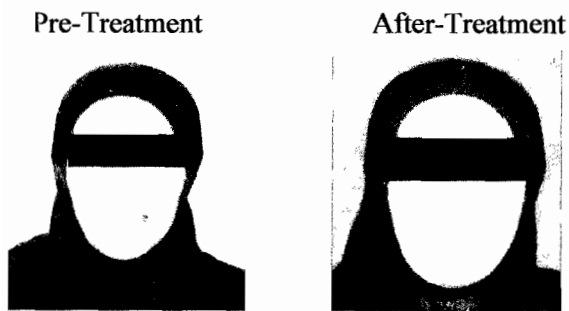


Fig 3. Two photographs for a patient from group (A) comparing pre and after treatment

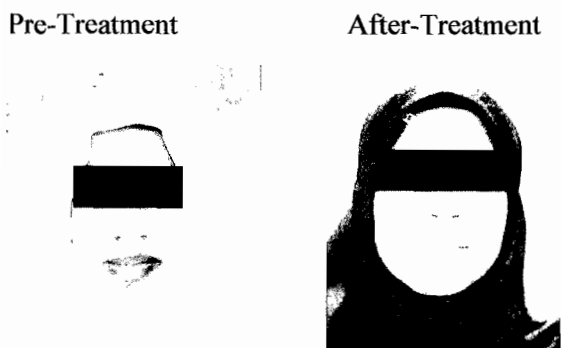


Fig 4. Two photographs for a patient from group (B) comparing pre and after treatment

Patient's opinion

The patient's 'feeling better' was recorded at each visit. A higher percentage of patients in group (A) reported that after beginning therapy. Special cases had a very severe acne vulgaris for a period more than 10 years. They tried many treatments during this period even hormones and steroids but their conditions did not improve. When treated with azithromycin they consider the results to be definitely superior to those obtained with the previous treatment. One of them had an excellent response with a clear or no lesion for a long period.

Discussion

The main aim of this study was to evaluate the effect of oral azithromycin antibiotic in the treatment of acne vulgaris by comparing its effect

against doxycycline which is the most widely and traditionally used drug.

The efficacy results of the study showed that through different outcome measures there was a significant improvement observed during the study period with both drugs. The response to azithromycin was shown to be as effective as doxycycline in improving acne state. This is in consistence with results obtained elsewhere⁵⁻⁷.

The lack of strict common outcome measures and distinct endpoints in acne trials in general together with the small size of the sample population, and increased number of missed visits, were pitfalls in this study.

Conclusion

After observing the pitfalls in this study, we can conclude that azithromycin is likely to be an effective and safe alternative treatment for moderate to severe inflammatory acne vulgaris and in cases resistant to doxycycline therapy as well as in pregnant and nursing females.

References

1. Drew RH, Gallis HA. *Pharmacotherapy*1993, 12(3),p. 161-173.
2. Driscoll MS, Rothe MJ, Abrahamian L et al. Long-term oral antibiotics for acne: is laboratory monitoring necessary? *J Am Acad Dermatol* 1993; 28: 595-602.
3. Shargel L, Mutinick AH, Souney PF et al. *Comprehensive Pharmacy Review*. 4th ed. 2001: 526-531. Lippincott Williams & Wilkins., USA.
4. Shelly WB, Shelly DS. *Advanced Dermatologic Therapy II*, 2001, Volume I, page 25.
5. Prasad D, Pandhi R, Nagpal R, et al. Azithromycin monthly pulse vs daily doxycycline in the treatment of acne. *Int J Dermatol* 2001;28:1-4
6. Naseema Kapadia, Abu Talib, *Pharmacology and therapeutics, Acne treated successfully with Azithromycin* ,*International journal of Dermatology*2004; 43(10) – 766
7. KusS, Yucelten D, Aytug A. Comparison of efficacy of azithromycin vs. doxycycline in the treatment of acne vulgaris, *Clinical and Experimental Dermatology* 2005; 30 (3): 215 - 8