


## Upside down stomach: a case report

MAM Ibnouf<sup>1</sup>, Osman A Wahab<sup>2</sup>, A M Massad<sup>3</sup>



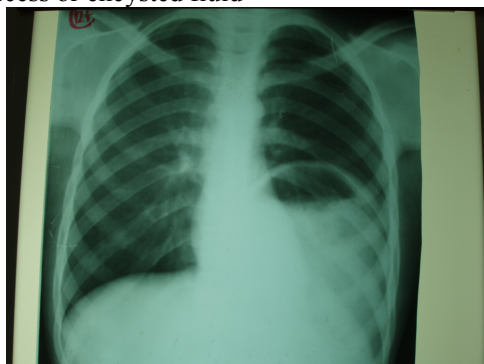
The upside down stomach (UDS) is an organo-axial rotation. The condition results from upwards migration of the antrum of the stomach towards the negative intrathoracic pressure particularly in cases having communication with the thoracic cavity as in penetration or eventration of the diaphragm. The antrum lies above the fundus i.e. the antrum lies high up adjacent to the base of the right lung. The lower oesophageal sphincter lies below the pylorus. The oesophagus has a normal length and structure.

### Case report

A 19-year old male was referred to the Surgical Gastrointestinal Unit at Ibn Sina Hospital complaining of repeated bouts of dry cough, breathlessness on mild exertion, poor appetite and feeling of distension after meals and post brandial vomiting of long duration. He was involved in a road traffic accident when he was a child for which he underwent laparotomy details of which were not known. On physical examination he was thin not pale, tachypnoeic or cyanosed. Pulse 78/min BP 110/70 temp 37°C. Chest examination revealed a central trachea, diminished air entry at the left base but no crepitations were heard. The cardiovascular system was normal. Abdomen was soft, lax, with an old upper median scar. There was neither tenderness nor palpable masses.

He came with a chest X-ray (Fig 1). A possibility of infected hydatid cyst with water-lilly appearance, encysted left-sided supra-diaphragmatic pleural effusion, or lung abscess was made. Investigations revealed normal full blood count, ESR 45mm in first hour, blood chemistry and ECG were also normal.

Fig 1: Chest X-ray showing possible hydatid cyst, abscess or encysted fluid



CT scan showed gastrografin contrast in a viscous in the left side of the chest. Gastroscopy showed normal oesophageal and gastric mucosa with some difficulty in entering the duodenum,

however, the mucosa of the first and second parts of the duodenum was normal. Barium meal showed a huge diaphragmatic hernia (Fig 2) with normal length of the oesophagus but the stomach looks inverted upside down with the pylorus high up near the copula of the diaphragm (Fig 3) During laparotomy the stomach was found inverted upside down with the antrum at the base of the right lung. The dome of the diaphragm was completely absent apart of a small rim of diaphragmatic tissue at the costal margin. A delayed diagnosis of traumatic rupture of the diaphragm was made. Polypropylene mesh (Marlex Mesh) was sutured in its outer edges to the costal margin and medially to the left half of the diaphragm. Polypropylene (Proline - ..... ) 2/0 was used to fix the mesh.

The post operative period was uneventful. The patient was discharged home and followed up in the outpatient department regularly for six months.

### Discussion:

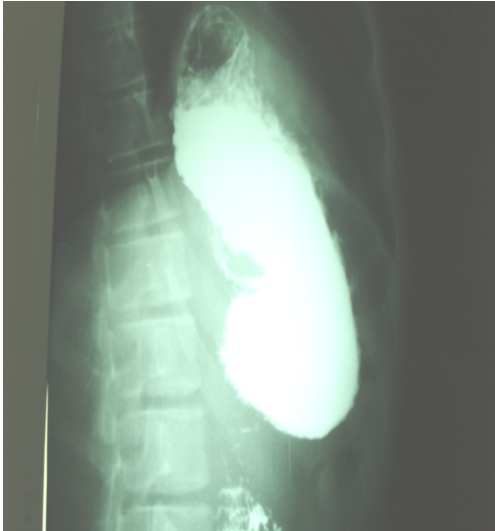The upside-down stomach (UDS) is a special form of acquired gastric malrotation in a hernial sac above the diaphragm. The condition should be suspected in patients who has retching or vomiting and has a para-oesophageal hiatus hernia or eventration of the diaphragm. Respiratory and upper gastrointestinal symptoms may occur.

Our patient symptoms were very much consistent with this description. Gastric volvulus occurs when the stomach rotates about its longitudinal axis (organo-axial volvulus), or about an axis joining the midpoint of the lesser and greater curvatures (mesentero-axial volvulus). Gastric volvulus may present acutely with Borchardt's triad or with chronic vague abdominal symptoms. The predisposing factors for gastric volvulus include lax ligaments (gastro-colic, gastro-splenic and gastro-phrenic), bands, adhesions, para-

1. Prof. of Surgery. Department of surgery. Omdurman Islamic University. Khartoum, Sudan.
2. Cosultant Radiologist. Associated Prof. University of Khartoum
3. Associated Prof GIT surgeon. Omdurman Islamic University.

oesophageal diaphragmatic hiatus hernia, and eventration of the diaphragm.

Fig2: Diaphragmatic hernia



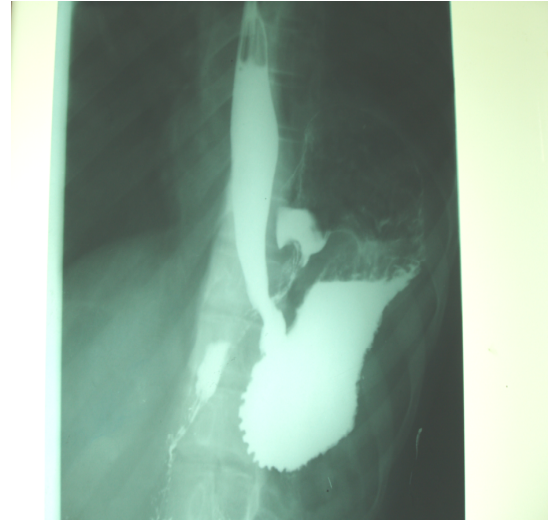
diaphragm which was missed in his previous laparotomy and the defect subsequently became gradually bigger with the negative intrathoracic pressure sucking the floppy antrum into the chest. Luckily, our patient didn't suffer from the classic Borchardt's triad of retching; severe constant epigastric pain and difficulty in passing a nasogastric tube that suggest acute gastric volvulus<sup>1</sup>. Allen MS et al<sup>2</sup> studied 147 patients with intrathoracic stomach and noted their presentation as postprandial pain in 59.2%, vomiting in 31.3%, and dysphagia in 29.9%; but only 15.7% patients had symptoms of gastro-oesophageal reflux and anemia was present in 21.1%.

Our patient is an adolescent. He might have had a similar pathology to the case reported by Moore CM et al<sup>3</sup> who had congenital eventration of the diaphragm mimicking traumatic diaphragmatic rupture. Congenital para-oesophageal hernia, is rare in children, and may present acutely with respiratory distress or intrathoracic gastric volvulus. Para-oesophageal hernia should be included in the differential diagnosis of children with repeated attacks of chest infection and/or vomiting.

The rarity of this condition in children makes it difficult to evaluate the true necessity of adding an anti-reflux procedure in these patients. We agree some form of gastropexy may be more appropriate to be added to the repair<sup>4</sup>. This may be correct for our patient who has normal length of

The last feature is in keeping with the operative findings of our patient. He had either congenital eventration or most likely a small injury of the

Fig 3: Upside down stomach



the oesophagus with normal infra-diaphragmatic cardia. In contradistinction para-oesophageal hernias represent advanced degree of sliding hiatus hernia with intrathoracic displacement of the intra-oesophageal junction. In para-oesophageal hernia gastro-oesophageal reflux

disease occurs in most cases, resulting in acquired short esophagus, which influences the type of repair selected<sup>1</sup>. However, para-oesophageal hernia, with the oesophago-gastric junction in a normal abdominal location, appears rare<sup>5</sup>. Pre-operative diagnosis of diaphragmatic injuries is difficult and requires a high index of suspicion after thoraco-abdominal trauma. In adults, diaphragmatic rupture prevails in the left side. Its surgical diagnosis and early management determines the effectiveness of treatment<sup>6</sup>.

Chest X-ray may show bowel herniation; marked elevation of hemi-diaphragm and pleural effusion. Chest radiographs are diagnostic in 46% with left-sided rupture and were considered suspicious enough to warrant further diagnostic studies in another 18% of patients. The later is a typical conclusion for our patient's chest X-ray. Nonetheless, CT is diagnostic for diaphragmatic rupture in 14% while MRI has higher diagnostic accuracy<sup>7</sup>. Chest radiographs obtained at admission and repeated soon afterwards are valuable in suggesting the diagnosis of traumatic rupture of the diaphragm than previously reported, particularly in the more frequent, left-sided injuries<sup>7</sup>.

Blunt injury of the diaphragm is suspected when there is asymmetry of a hemi-diaphragm or presence of abdominal contents within the chest, diaphragmatic paresis, unexplained haemothorax, or multiple upper abdominal injuries. Penetrating missile or blade through the hemi-diaphragm may not lead to any immediate radiological abnormality. Nevertheless, the diagnosis of traumatic diaphragmatic injury may be elusive and often can be made only during exploratory surgery<sup>8</sup>.

The preference of the operative approach being thoracotomy or laparotomy is controversial. However, in recent years laparoscopic surgery of para-oesophageal hernia is increasing. Trans-abdominal access should be chosen if brachy-oesophagus is not expected like in our case. Yet, awareness of a common hiatus is vital for approximating the crura. An antireflux procedure is not necessary as gastro-oesophageal reflux usually resolves spontaneously after hiatal repair and gastropexy<sup>9</sup>. Like in our patient, the diagnosis of diaphragmatic hernias, whether due to congenital defects or trauma, may be difficult and may rely on clinical suspicion in the setting of radiographic findings<sup>10</sup>.

Brachy-oesophagus is not a problem in UDS, as the oesophagus is of normal length. The hiatus, on the other hand, as in our case, is always very large and needs proper narrowing, which may be achieved through a trans-abdominal approach more easily than through a trans-thoracic access. A common oesophago-aortal hiatus is often present. Therefore, hiatal repair and gastropexy, i.e. fundo-phrenopexy and corpo-ventropexy along the oesophageal axis is important to prevent recurrent gastric herniation or torsion<sup>11</sup>. Anterior gastropexy with or without colon displacement is mandatory<sup>12</sup>.

Allen MS et al<sup>2</sup> reported the type of elective surgical repair among his 147 cases as Collis-Nissen repair in 68.1%, Belsey Mark IV repair in 16.0%, Nissen repair in 14.3%, and a Harrington (anatomic) repair in 1.7% with complications in 26.5% patients and concluded that patients with an intrathoracic upside-down stomach who have obstructive symptoms at initial presentation should undergo repair and that elective operation is safe and effective. In contrast our patient had had mesh repair with Nissen's fundoplication.

Steiger Z et al<sup>13</sup> described seven patients with hernias occurring after Belsey hiatal hernia repair. These hernias were of two types. Four occurred through the hiatus and had the

appearance of para-oesophageal hernia, and were attributed to the failure to correct a shortened oesophagus. In three patients the hernia occurred through a disrupted diaphragm. In the first group satisfactory repair was achieved by a Collis-Belsey gastroplasty and an anti-reflux procedure. In the second group reduction of the hernia and resuture of the diaphragm encompassing all layers corrected this life threatening hernia<sup>13</sup>.

The approach to the repair operation, may be either abdominal or thoracic, dependent upon the need to correct other associated gastrointestinal pathologic lesions. Unless severe debilitating medical diseases are present, operative intervention is recommended<sup>14</sup>.

Fortunately the short term follow up of our patient was satisfactory but, UDS has considerable amount of misdiagnosis, long mean hospitalization, high mortality and very high morbidity<sup>15, 16, 17, 18, 19</sup>. The delay in presentation varies from one to 16 years from the time of the original injury<sup>20</sup>. This is probably typical for our patient's delay.

Preoperative diagnosis of diaphragmatic rupture caused by blunt injury is often difficult because of serious concurrent injuries, lack of specific clinical signs, and simultaneous lung disease that may mask or mimic the diagnosis radiologically. Traumatic diaphragmatic hernias are usually associated with serious injuries in children. It is important to combine a high index of suspicion with radiological diagnostic tests in patients at risk. Palpation and visualization of both diaphragms at laparotomy is extremely important in detecting these injuries when they are not suspected preoperatively<sup>21</sup>. A high index of suspicion and a thorough examination of both hemi-diaphragms reduces complications<sup>22</sup>. Repair could be accomplished through the ipsilateral chest or during laparotomy, using mesh repair<sup>23</sup>, an is recommended in order to avoid early or late complications.

UDS is an extreme variant of para-oesophageal hernia. The cardia and pylorus are located next to each other, while the rest of the stomach lies within the thorax. Radiology is mandatory for accurate anatomical documentation. This is a rare condition found during endoscopy, with an incidence of 1.5%. Since there is a risk of volvulus, surgical correction is usually indicated<sup>24</sup>

#### References:

- 1 - Llana PP, Salt WB 2nd. Gastric volvulus. More common than previously thought? *Postgrad Med.* 1986; 80(5): 279-83.

- <sup>2</sup> - Lee JS, Park JW, Sohn JW, et al. Organo-axial volvulus of the stomach with diaphragmatic eventration. *Korean J Intern Med.* 2000; 15(2): 127-30.
- 3- Moore CM, Mander BJ, Raja MA. A case of congenital eventration of the diaphragm mimicking traumatic diaphragmatic rupture. *Injury.* 2001; 32(6): 508-9.
- <sup>4</sup> - Al-Salem AH. Congenital para-oesophageal hernia in infancy and childhood. *Saudi Med J.* 2000; 21(2): 164-7.
- <sup>5</sup> - Maziak DE, Todd TR, Pearson FG. Massive hiatus hernia: evaluation and surgical management. *J Thorac Cardiovasc Surg.* 1998;115(1):53-60; 61-2.
- <sup>6</sup> -Shehata SM, Shabaan BS. Diaphragmatic injuries in children after blunt abdominal trauma. *J Pediatr Surg.* 2006 Oct;41(10): 1727-31.
- <sup>7</sup> - Gelman R, Mirvis SE, Gens D. Diaphragmatic rupture due to blunt trauma: sensitivity of plain chest radiographs. *AJR Am J Roentgenol.* 1991; 156(1): 51-7. Comment in: *AJR Am J Roentgenol.* 1991; 157(2):411.
- <sup>8</sup> - Shackleton KL, Stewart ET, Taylor AJ. Traumatic diaphragmatic injuries: spectrum of radiographic findings. *Radiographics.* 1998; 18(1): 49-59.
- <sup>9</sup> - Stiefel D, Willi UV, Sacher P, et al. Pitfalls in therapy of upside-down stomach. *Eur J Pediatr Surg.* 2000; 10(3): 162-6.
- <sup>10</sup>- Sattler S, Canty TG Jr, Mulligan MS, Wood DE, Scully JM, Vallieres E, Pohlman T, Karmy-Jones R. Chronic traumatic and congenital diaphragmatic hernias: presentation and surgical management. *Can Respir J.* 2002; 9(2): 135-9.
- 11- Scaglione M, Pinto F, Grassi R, et al. Diagnostic sensitivity of computerized tomography in closed trauma of the diaphragm. Retrospective study of 35 consecutive cases.. *Radiol Med (Torino).* 2000; 99(1-2): 46-50.
- <sup>12</sup>- Johnson JA 3rd, Thompson AR. Gastric volvulus and the upside-down stomach. *J Miss State Med Assoc.* 1994; 35(1): 1-4.
- <sup>13</sup>- Steiger Z, Wilson RF, Nelson RM, Huang CL, Jacobs LA. Iatrogenic hiatal and diaphragmatic hernias. *Am Surg.* 1984; 50(4): 217-21.
- <sup>14</sup>- Weinstein EC, Kohn BS. Paraesophageal hiatus hernia in the aged. *J Am Geriatr Soc.* 1976; 24(1): 37-40.
- <sup>15</sup>- Esme H, Solak O, Sahin DA, et al. Blunt and penetrating traumatic ruptures of the diaphragm. *Thorac Cardiovasc Surg.* 2006; 54(5): 324-7.
- <sup>16</sup> - Stagnitti F, Priore F, Corona F, et al. Traumatic lesions of the diaphragm. *G Chir.* 2004 ; 25(8-9): 276-82.
- <sup>17</sup>- Abdel Hadi MS, Al-Mulhim AA, Al-Awad NI, et al. Diaphragmatic injury. A clinical review. *Saudi Med J.* 2001; 22(10): 890-4.
- <sup>18</sup>- Degiannis E, Levy RD, Sofianos C, et al. Diaphragmatic herniation after penetrating trauma. *Br J Surg.* 1996; 83(1): 88-91.
- <sup>19</sup>- Maddox PR, Mansel RE, Butchart EG. Traumatic rupture of the diaphragm: a difficult diagnosis. *Injury.* 1991; 22(4): 299-302.
- <sup>20</sup>- McHugh K, Ogilvie BC, Brunton FJ. Delayed presentation of traumatic diaphragmatic hernia. *Clin Radiol.* 1991; 43(4): 246-50. Comment in: *Clin Radiol.* 1991; 44(6): 436.
- <sup>21</sup>- Ramos CT, Koplewitz BZ, Babyn PS, et al. What have we learned about traumatic diaphragmatic hernias in children? *J Pediatr Surg.* 2000; 35(4): 601-4.
- <sup>23</sup>- Mihos P, Potaris K, Gakidis J, et al. Traumatic rupture of the diaphragm: experience with 65 patients. *Injury.* 2003; 34(3): 169-72.
- <sup>24</sup>- Kowalewski H, Rosch WThe "upside-down stomach"--a diagnostic pitfall. *Fortschr Med.* 1989; 107(10): 54-6.