

Case Report

Customized Preliminary Impression: A Novel Impression Technique for Severely Resorbed Edentulous Ridges

Arpit Sikri¹, Jyotsana Sikri², Tarun Kalra³, Ritika Sharda⁴, Natasha Bathla⁵, Sahil Thakur⁴

¹Department of Prosthodontics, Crown Bridge and Oral Implantology, Bhojia Dental College and Hospital, Solan, Himachal Pradesh, India

²Department of Conservative Dentistry and Endodontics, Bhojia Dental College and Hospital, Solan, Himachal Pradesh, India

³Department of Prosthodontics, Crown and Bridge and Oral Implantology, Bhojia Dental College and Hospital, Solan, Himachal Pradesh, India

⁴Department of Prosthodontics, Crown and Bridge and Oral Implantology, Bhojia Dental College and Hospital, Solan, Himachal Pradesh, India

⁵Department of Prosthodontics, Crown and Bridge and Oral Implantology, Bhojia Dental College and Hospital, Solan, Himachal Pradesh, India

ORCID:

Arpit Sikri: <https://orcid.org/0000-0002-6273-8882>

Corresponding Author: Arpit Sikri; email: arpitsikri@gmail.com

Received 7 December 2022

Accepted 10 June 2022

Published 27 September 2023

Production and Hosting by Knowledge E

© Arpit Sikri et al. This article is distributed under the terms of the [Creative Commons Attribution License](#), which permits unrestricted use and redistribution provided that the original author and source are credited.

Editor-in-Chief:

Prof. Nazik Elmalaika Obaid

Seid Ahmed Husain, MD, M.Sc.,

MHPE, PhD.

Abstract

Patients with long-term edentulism and/or ill-fitting (poorly fitted) dentures are more likely to experience severe mandibular alveolar ridge resorption. Some of these patients have genial tubercles that rise over the mandibular residual ridge in the anterior region and protrude into the floor of the mouth. Typically, the most prominent portions of the resorbed mandibular edentulous ridge are in contact with the lingual flanges of the mandibular stock impression trays (i.e., genial tubercles and internal oblique lines). In these situations, it is advised that a preliminary custom impression tray be created to pour an initial impression, allowing for the fabrication of individual custom trays. In general, dental practice for the fabrication of the complete denture, the stock trays are used for making the preliminary impression and the custom trays for the final impression. The present article portrays an innovative and efficient clinical technique involving the fabrication of a customized preliminary impression tray for preliminary impression making particularly in unconventional situations, that is, pronounced mandibular alveolar ridge resorption.

Keywords: custom tray, edentulous mandible, individual tray, preliminary impression, residual ridge resorption

OPEN ACCESS

1. Introduction

Patients with complete dentures who have advanced lower ridge resorption are becoming more common over time [1]. If physiologic methods are not used to create stable and retentive dentures, ridges that have already had significant resorption will continue to deteriorate due to atrophy, trauma, or ill-fitting dentures. The tissues over the ridge are significantly distorted by ill-fitting dentures, which also promote bone resorption. The contour of the mucosa changes because of the continuous usage of these dentures [2].

The main goal of the complete-denture fabrication philosophies and techniques that have been presented to the dental profession over the years is to obtain maximum retention, stability, and support [3]. Maximum denture-supporting tissue coverage is a key element that improves denture retention, stability, and support [4]. The majority of the techniques for the fabrication of complete dentures that have been developed begin with preliminary impressions that serve as a building block for a complete denture and entail an impression procedure using stock trays that encompass as much of the edentulous area as possible.

The genial tubercles, which are the highest point in the anterior portion of the mandibular residual ridge, protrude onto the floor of the mouth in many patients due to the alveolar ridge resorption [5]. Because the projecting genial tubercles prevent the lingual flange area in the anterior region from seating properly, this scenario makes it difficult for selecting an acceptable stock impression tray to form an accurate preliminary impression. A stock tray may deform the tissue and lead to an overextended impression, hence Klein [6] suggested developing the impression without the stock tray. A contoured metal wire was suggested by Kinra et al.[7] as an alternative preliminary impression procedure for a compromised residual mandibular alveolar ridge.

This case portrays an innovative and efficient technique of fabricating a custom preliminary impression tray for maximum coverage of edentulous areas in patients with significant residual ridge resorption.

2. Case Report

A 65-year-old completely edentulous man presented with an ill-fitting lower denture. The patient's chief complaint was that his lower denture was loose, and he had difficulty chewing food for the past four years. The patient's past medical history was not significant. Previous dental history showed that the patient had worn a complete denture for

the past 25 years. Upon intraoral examination, the mandibular residual alveolar ridge was extensively resorbed.

The available treatment options including conventional prosthodontic rehabilitation, surgical intervention, and implant-supported fixed and removable prosthesis were discussed with the patient. Different treatment choices were outlined to the patient, considering his financial limitation and his unwillingness for undergoing surgical treatment. The patient opted for the removable complete denture. Besides, a new technique for taking an impression for his severely resorbed ridge was also explained, which will be used for the fabrication of the prosthesis.

The patient signed informed written consent for accepting the treatment by the new technique for impression and his acceptance for publication of this case in the future.

3. Procedure

Complete denture fabrication's initial steps remained the same that is, examination, diagnosis, initial impressions, final impressions, maxillo-mandibular jaw relation records, teeth selection, wax-trial denture try-in, and delivery of definitive prostheses.

Medium-fusing impression compound was used to create preliminary impressions of the maxillary and mandibular arches (Hiflex Impression Compound, Prevest DenPro Limited, Jammu, India). To obtain a proper primary cast using type II dental plaster (GypRock plaster, Rajkot, Gujarat, India), beading and boxing of the primary impressions were done (MAARC Dental, Maharashtra, India). A prefabricated (perforated) metal mesh sheet (MAARC – CE Reinforcement Golden Mesh, Shiva Products, Thane, India) of 0.6 mm thickness was selected and trimmed to create an outline for the impression tray (Figure 1).

The excess metal mesh around the anterior, that is, lingual frenum area was folded. A handle for the tray was created and secured using an admix of impression compound and a green stick (Pinnacle Tracing Sticks, Dental Products of India, Mumbai, India) for added support. The custom preliminary impression tray was created by folding the metal mesh around the flange areas. The preliminary impression tray was customized according to the patient's mouth, that is, in both relaxed as well as in functional positions (Figure 2).

An admix of impression compound and a green stick was softened for border moulding and extending the tray as required (Figure 3).

Tray adhesive (Caulk Tray Adhesive, Dentsply India Pvt Ltd, Mumbai, India) was applied over the tray for at least 7 minutes as recommended by the manufacturer.

The tray was loaded over the borders with polyvinyl siloxane impression material putty (Aquasil Soft Putty, Dentsply India Pvt Ltd, Mumbai, India) to achieve proper extensions. This was followed by placing the tray in the patient's mouth with moderate pressure to record the intricate details of the tissues. The borders of the impression completely filled the labial, buccal, and lingual vestibules to provide a peripheral seal for the final denture. The patient was asked to perform tongue movements following the conventional impression procedures. The tray was removed from the patient's mouth and the impression was examined (Figure 4).

The polyvinyl siloxane light body consistency (Aquasil Ultra LV Light Body, Dentsply India Pvt Ltd, Mumbai, India) impression material was loaded onto the impression and inserted into the patient's mouth. The patient was instructed to repeat the tongue movements more vigorously for proper border moulding of the material. The impression was removed from the patient's mouth after the material was set (Figure 5). The remaining steps were the same as required for the fabrication of the complete denture.




Figure 1: Prefabricated metal mesh selected & trimmed to create mandibular tray.

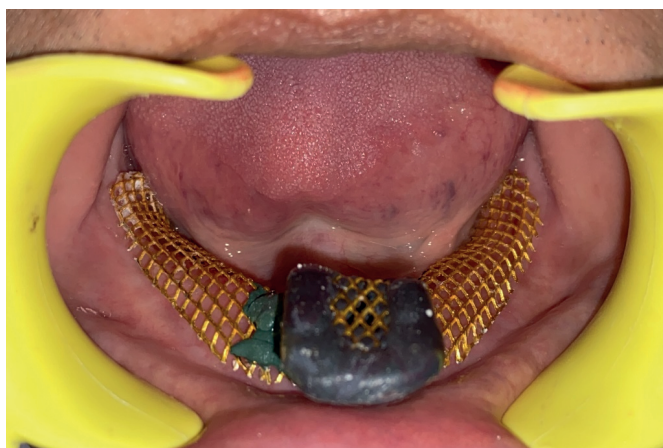

Figure 2: Custom preliminary impression tray in patient's mouth.

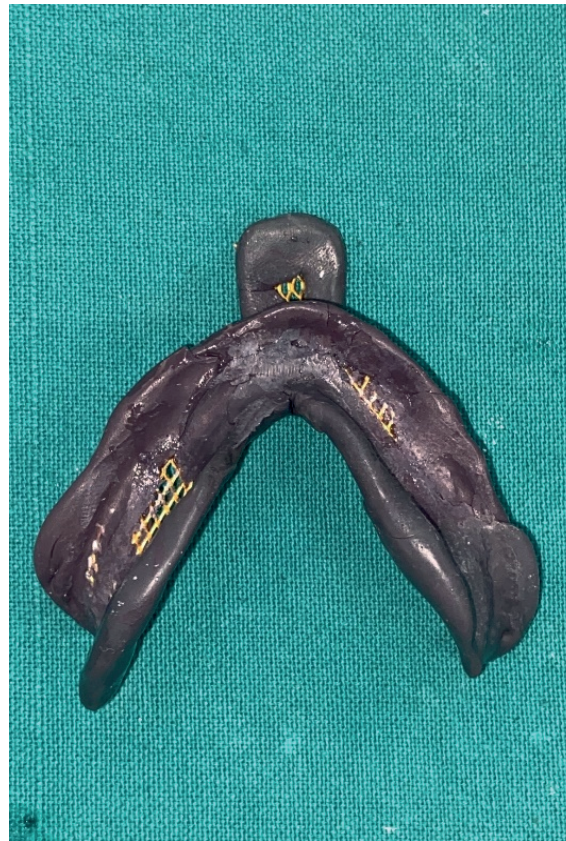

Figure 3: Mesh outlined with admix material.

4. Discussion

Every complete denture must possess the three fundamental qualities of retention, stability, and support for it to be successful [8]. Due to the greater number of anatomical limitations that must be considered, mandibular dentures typically provide more challenges in achieving these three features [9].

Severe mandibular resorption is frequently the outcome of long-term edentulism and the long-term use of ill-fitting dentures [10]. Because of how drastically this acute residual ridge resorption alters the morphology of the mandibular edentulous ridge, stock impression trays cannot be used to make the preliminary impressions correctly [11]. The stock tray does not fit precisely in the severely resorbed ridge, which results in an erroneous primary impression, leading to the creation of ill-fitting dentures [12]. Not all primary impression errors can be fixed when border moulding is being done since the low-fusing impression compound can only extend up to 2 mm [13]. This is due to the fact that border moulding cannot record anatomical landmarks that are not recorded in the primary impression. A dental surgeon should, therefore, put a lot of emphasis on creating

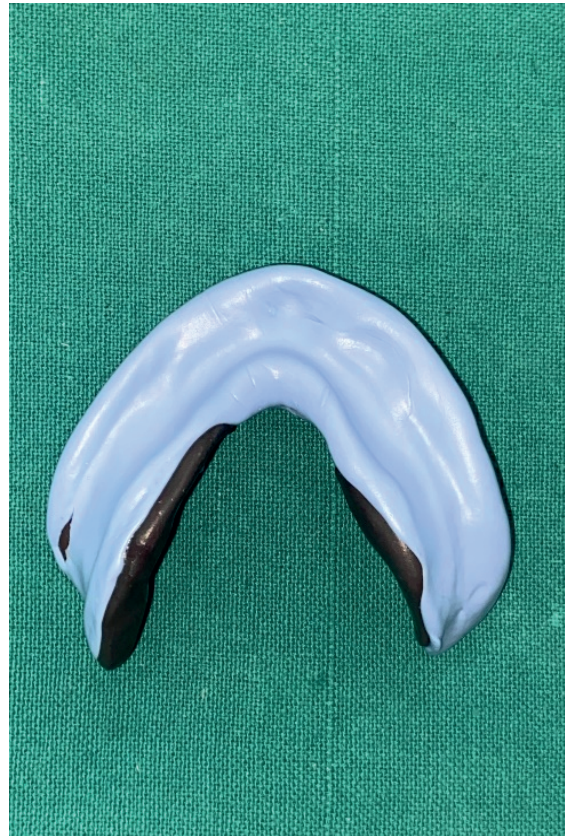

Figure 4: Impression made with polyvinyl siloxane impression material putty.

an accurate first impression [14]. A successful preliminary impression yields a well-contoured denture, an accurate wash impression, and an extended border moulding [15].

The genial tubercles projecting as the highest point in the anterior part of the edentulous mandible are the most typical findings in cases with severe resorption [16]. Any attempt to utilize a stock tray in such a case will result in the tray's lingual flange impinging on the genial tubercles, making it impossible for the stock tray to be correctly placed and ultimately preventing it to be seated properly. Because the individual custom trays will not sufficiently cover the denture-supporting areas, the resulting impressions are typically short in the buccal, labial, and posterior lingual areas, making it difficult to complete the final impression procedure [17].

Such issues can be resolved by an innovative technique, which involves the fabrication of a customized stock tray using inexpensive materials that are easily found in a dental practice. The basic frame outline of an impression tray can simply be created from a metal mesh, and since the impression compound is a thermoplastic material, additional customization of the impression tray is possible.

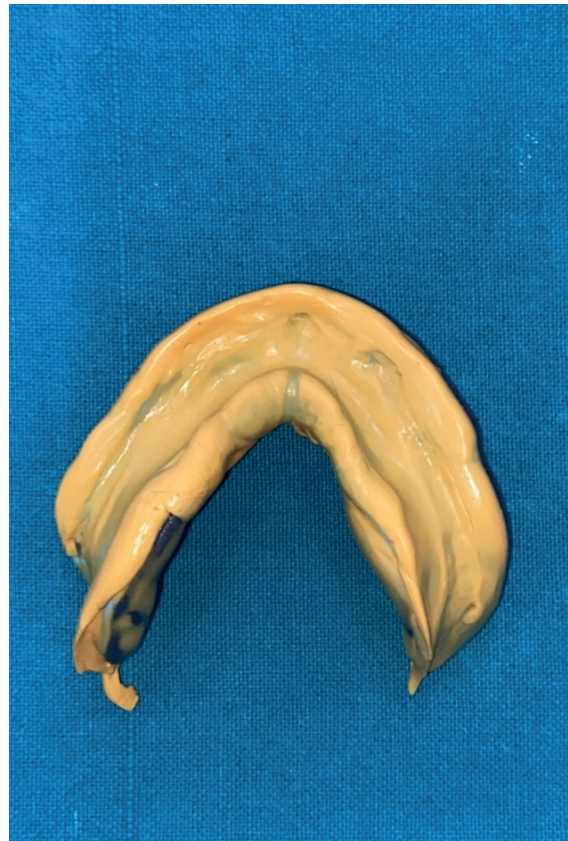

Figure 5: Wash impression made with polyvinyl siloxane light body consistency impression material.

The preliminary impression was created with polyvinyl siloxane impression material [18]. This material was chosen because it is simple to mix, is available in all four consistencies, has a high viscosity, can be poured up to a week later than usual, poured repeatedly, is easily adaptable and strengthened with metal mesh, and can reproduce excellent surface details [19]. The proposed material enables further extension to regions that the impression tray might not be able to sustain. Moreover, it provides a longer and more satisfactory working period of about 4 – 6 minutes [20], which gives the dental surgeon more time to cover all the lingual, buccal, and labial flange areas.

Finally, the denture-supporting regions' intricate details will be perfectly captured by using the polyvinyl siloxane light body impression material creating a flawless preliminary impression. The dental technician will be able to create an accurate custom individual tray using the casts created from such an impression, which will make it simple for the dental clinician to create an accurate final impression.

The alternative method suggested by Boucher is impractical in this specific clinical situation for creating a preliminary impression. In this procedure, the primary impression is initially made using a stock tray and high-fusing impression compound, following which the borders are redefined and the impression is taken from the stock tray. This

method is inapplicable, because the stock tray does not fit precisely on the severely resorbed ridge [21].

Making a primary and a secondary impression is possible when computer-aided designing (CAD), computer-aided machining (CAM), and rapid prototyping (RP) technologies are used [22, 23]. The prepared impressions were accurate, properly extended, and the tissue displacement and denture base interface were the same when comparing digital impressions to conventional impression processes [24]. The advantages of digital technology include improved treatment outcome predictability, fewer appointment times [25], and shorter patient chairside times. It also increases efficiency and standardizes the restoration process, reducing dependence on the operator's competence and subjective experience [26]. However, there are a lot of disadvantages as well, like the expensive cost of technology and the requirement for trained employees to operate the machinery [27].

The CAD/CAM machine was unavailable, extremely expensive, and required a skilled person, therefore this technology was one of the alternatives for generating a preliminary impression in this situation, but it was not used. Moreover, it cannot record the resiliency of the soft tissues.

As the present new technology is technique sensitive, an operator should keep in mind a few things when making an impression. The impression material should possess desirable qualities, such as the ability to mould and precisely record the borders. Polyvinyl siloxane putty and light-bodied impression materials were used in this procedure because they contain all the aforementioned ideal characteristics.

5. Conclusion

Stock impression trays are not an option due to their negative impact on the tissues, that is, impingement over the tissues such as the genial tubercles. In such situations, customized preliminary impression trays can be used, particularly in patients with severe edentulous mandibular ridge resorption. Additionally, it can be used for patients with restricted mouth opening, that is, patients with microstomia, oral submucous fibrosis, etc., and postsurgical patients who have severe tissue deficits. Although the use of the polyvinyl siloxane putty impression material can lead to an impression that is slightly overextended, preliminary impressions made with the customized preliminary impression tray were extremely close to the final impressions. The results of the innovative clinical technique are very satisfactory.

When standard stock impression trays are unable to facilitate the making of the preliminary impressions due to severely resorbed mandibular edentulous ridge, the dental surgeon/practitioner can fabricate an impression tray using this innovative clinical technique. Hence, the present innovative clinical technique is a boon for the unconventional residual ridges, that is, the severely resorbed residual alveolar ridge.

Acknowledgments

None

Ethics approval

The patient signed informed written consent is attached.

Competing interests

None

Availability of Data and Material

Supported by the Department of Prosthodontics

Funding

None

Abbreviations and Symbols

CD – complete denture

mm – millimeter

CAD–CAM - Computer aided design, Computer assisted milling

Ethical Approval

The patient signed informed written consent is as follows:

PATIENT CONSENT FORM

Department of Prosthodontics, Crown & Bridge and Oral Implantology,
Bhojia Dental College & Hospital, Budh (Baddi),

Customized Preliminary Impression: A Novel Impression Technique for Severely Resorbed
Edentulous Ridges

I, Jitendra Kumar, after thoroughly listening to the information sheet in the presence of caretaker, in the language that I can understand, about my involvement in the case:


- I agree to give my personal details like name, age, sex etc. and the details required for the case to the best of my knowledge.
- I will provide my co-operation to the dentist for my intra-oral and extra-oral examination.
- I allow the dentist to obtain photographs at each and every clinical step.
- I permit the operator to utilize information given by me and my photographs for presentation and publication purpose.
- I will not claim any returns for my co-operation, I am participating with my own wish and will.
- I have understood the above information given by the doctor about the case.

मुझे, जीतेंद्र कुमार इस अध्ययन में मेरी भागीदारी के बारे में उस भाषा में सूचित किया गया है जिसे मैं समझ सकता हूँ।

- मैं अपना नाम, आयु, लिंग आदि की तरह व्यक्तिगत विवरण और अध्ययन के लिए आवश्यक विवरण देने में सहमति रखता हूँ।
- मैं दन्त चिकित्सक को अपनी मौखिक जाँच के लिए सहयोग दूंगा।
- मैं दन्त चिकित्सक को अपनी फोटो खींचने की अनुमति देता हूँ।
- मैं दन्त चिकित्सक को मेरे द्वारा दी गई जानकारी तथा फोटो का उपयोग करने की अनुमति देता हूँ।
- मैं इस अध्ययन में सहयोग के लिए किसी भी रिटर्न का दावा नहीं करूँगा, मैं अपनी मर्जी से इस अध्ययन में भाग ले रहा हूँ।
- मुझे दन्त चिकित्सक द्वारा उपरोक्त अध्ययन के बारे में दी गई जानकारी की समझ है।

Date: 17.09.2022

Place: Baddi


Signature/thumbprint

6. Author Contributions

1. Concepts, Literature search - Dr. Arpit Sikri
2. Clinical studies, Experimental studies - Dr. Jyotsana Sikri
3. Data acquisition, Data analysis, Statistical analysis - Dr. Tarun Kalra
4. Manuscript preparation, Manuscript editing, Manuscript review - Dr. Ritika Sharda

5. Final Approval of the version to be published - Dr. Natasha Bathla & Dr. Sahil Thakur

References

- [1] Huuemonen, S., Haikola, B., Oikarinen, K., Söderholm, A. L., Remes-Lyly, T., & Sipilä, K. (2012). Residual ridge resorption, lower denture stability and subjective complaints among edentulous individuals. *Journal of Oral Rehabilitation*, 39, 384–390. <https://doi.org/10.1111/j.1365-2842.2011.02284.x>
- [2] Karnam, S., Basimi, S., Surapaneni, H., Basapogu, S., & Gantala, R. (2015). Severely resorbed edentulous ridges: A preventive prosthodontic approach - A case report. *Journal of Clinical and Diagnostic Research : JCDR*, 9, ZD17–ZD19. <https://doi.org/10.7860/JCDR/2015/15439.6666>
- [3] Azaria, H. (1972). Elements of removable prosthodontics. Complete Dentures. Thessaloniki, Greece: Aristotle University of Thessaloniki. 52-62,146-164,271-288, 292-306.
- [4] Azzam, M. K., Yurkstas, A. A., & Kronman, J. (1992). The sublingual crescent extension and its relation to the stability and retention of mandibular complete dentures. *The Journal of Prosthetic Dentistry*, 67, 205–210. [https://doi.org/10.1016/0022-3913\(92\)90454-I](https://doi.org/10.1016/0022-3913(92)90454-I)
- [5] Bocage, M., & Lehrhaupt, J. (1977). Lingual flange design in complete dentures. *The Journal of Prosthetic Dentistry*, 37, 499–506. [https://doi.org/10.1016/0022-3913\(77\)90162-7](https://doi.org/10.1016/0022-3913(77)90162-7)
- [6] Klein, P. (1971). La peizographie en prothese adjointe mandibulaire. Thesis, Paris.
- [7] Kinra, M., Chugh, D., Gowdar, I., Khan, S., Kola, M., & Sachdeva, B. (2016). Making of primary impression made easy for severely resorbed mandibular ridge – A clinical case report. *Journal of Advances in Medicine and Medical Research*, 19, 1–8.
- [8] Jacobson, T. E., Krol, A. J. (1983). A contemporary review of the factors involved in complete denture retention stability and support. Part I. Retention. *Journal of Prosthetic Dentistry*, 49, 5-15.
- [9] Jacobson, T. E., & Krol, A. J. (1983). A contemporary review of the factors involved in complete dentures. Part II: Stability. *The Journal of Prosthetic Dentistry*, 49, 165–172. [https://doi.org/10.1016/0022-3913\(83\)90494-8](https://doi.org/10.1016/0022-3913(83)90494-8)
- [10] Jacobson, T. E., & Krol, A. J. (1983). A contemporary review of the factors involved in complete dentures. Part III: Support. *The Journal of Prosthetic Dentistry*, 49, 306–313. [https://doi.org/10.1016/0022-3913\(83\)90267-6](https://doi.org/10.1016/0022-3913(83)90267-6)

- [11] Klein, I. E., Goldstein, B. M. (1984). Physiologic determinants of primary impressions for complete dentures. *Journal of Prosthetic Dentistry*, 53, 611-616.
- [12] Aiche, H. (1989). Preliminary functional impression for the mandibular complete denture. *The International Journal of Prosthodontics*, 2, 543–548.
- [13] Kinra, M., Kinra, M., Kalra, A., Nagpal, A., Kapoor, V. (2012). Custom impression trays in prosthodontics- clinical guidelines. *Indian Journal of Dental Sciences*, 4, 93–95.
- [14] McCord, J. F., & Grant, A. A. (2000). Impression making. *British Dental Journal*, 188, 484–492. <https://doi.org/10.1038/sj.bdj.4800516a>
- [15] Juneja, S., Arora, A., Garg, S. (2013). Creating a denture using customized multi-step approach: A case report. *Indian Journal of Dental Sciences*, 4, 99–101.
- [16] Lott, F., & Levin, B. (1966). Flange technique: An anatomic and physiologic approach to increased retention, function, comfort, and appearance of dentures. *The Journal of Prosthetic Dentistry*, 16, 394–413. [https://doi.org/10.1016/0022-3913\(66\)90044-8](https://doi.org/10.1016/0022-3913(66)90044-8)
- [17] Shanahan, T. E. (1962). Stabilizing lower denture on unfavorable ridges. *The Journal of Prosthetic Dentistry*, 12, 420–424. [https://doi.org/10.1016/0022-3913\(62\)90122-1](https://doi.org/10.1016/0022-3913(62)90122-1)
- [18] Madhav, V. N. V., & Desai, P. (2012). Elastomeric impression technique for complete denture impressions. *Journal of International Dental and Medical Research*, 5, 122–128.
- [19] Anusavice, K. J. (1996). Phillips science of dental materials (10th ed.). WB Saunders Co.
- [20] Solomon, E. G. R. (2011). A critical analysis of complete denture impression procedures: Contribution of early prosthodontists in India-part I. *Journal of Indian Prosthodontic Society*, 11, 172–182. <https://doi.org/10.1007/s13191-011-0089-2>
- [21] Zarb, G. A., Bolender, C., & Hickey, C. (1985). Boucher's prosthodontic treatment for edentulous patients (6th ed.). Mosby-Year Book.
- [22] Neumeier, T. T., & Neumeier, H. (2016). Digital immediate dentures treatment: A clinical report of two patients. *The Journal of Prosthetic Dentistry*, 116, 314–319. <https://doi.org/10.1016/j.prosdent.2016.01.010>
- [23] Matsuda, T., Goto, T., Yagi, K., Kashiwabara, T., & Ichikawa, T. (2016). Digitizing system of impression and inter occlusal records for complete denture fabrication. *The Journal of Prosthetic Dentistry*, 25, 503–509. <https://doi.org/10.1111/jopr.12375>
- [24] Rignon-Bret, C., Dupuis, R., & Gaudy, J. F. (2002). Application of a 3-dimensional measurement system to complete denture impressions. *The Journal of Prosthetic Dentistry*, 87, 603–612. <https://doi.org/10.1067/mpr.2002.124204>

- [25] Infante, L., Yilmaz, B., McGlumphy, E., & Finger, I. (2014). Fabricating complete dentures with CAD/CAM technology. *The Journal of Prosthetic Dentistry*, *111*, 351–355. <https://doi.org/10.1016/j.prosdent.2013.10.014>
- [26] Zhang, P., Li, W., Wang, Y., Pan, S., & Sun, Y. (2016). [Multi-source data acquisition technology in the restoration of the complete denture restoration]. *Chung-Hua Kou Chiang I Hsueh Tsa Chih Chinese Journal of Stomatology*, *51*, 124–128.
- [27] Alghazzawi, T. F. (2016). Advancements in CAD/CAM technology: Options for practical implementation. *Journal of Prosthodontic Research*, *60*, 72–84. <https://doi.org/10.1016/j.jpjor.2016.01.003>