

Case Report

The Confusing Tale of Foreign Body Gastric Outlet Obstruction

Nader Mutwakel Osman

Pediatric and Child Health, Department Omdurman Islamic University, Sudan

ORCID:

Nader Mutwakel Osman: <https://orcid.org/0009-0002-3252-9649>

Abstract

Background: Duplication cysts are rare congenital anomalies that can occur anywhere in the gastrointestinal tract from the mouth up to the anus. Acquired gastric outlet obstruction (GOO) during infancy beyond the neonatal period is a very rare condition and should be considered when other causes of GOO such as infantile hypertrophic pyloric stenosis, antral diaphragm, and pyloric atresia are excluded.

Case Presentation: We report a one-year old female infant who presented with an acute onset of copious persistent vomiting that was initially diagnosed with a duplication cyst of the duodenum, but was found to have GOO after surgical exploration.

Conclusion: Clinicians should be mindful of the common causes of GOO and have a high index of suspicion for acquired causes.

Corresponding Author: Nader Mutwakel Osman; email: nader_osman@hotmail.com

Keywords: duplication cyst, gastric outlet, acquired obstruction

Received 30 December 2020
Accepted 23 October 2022
Published 31 March 2023

Production and Hosting by
Knowledge E

© Nader Mutwakel Osman. This article is distributed under the terms of the [Creative Commons Attribution License](#), which permits unrestricted use and redistribution provided that the original author and source are credited.

Editor-in-Chief:
Prof. Nazik Elmalaika Obaid
Seid Ahmed Husain, MD,
M.Sc, MHPE, PhD.

1. Introduction

Gastrointestinal (GI) tract duplication cysts are rare congenital GI malformations that can be seen in pediatric and adult populations. They can be either cystic or tubular and share several properties such as having an intimate attachment to the GI tract, a lining of epithelial mucosa, and a well-developed smooth muscle layer [1]. Based on their embryonic origin, they can be subdivided into foregut, small bowel, and large bowel duplication cysts [2]. The most common identifiable sites for duplication cysts in the GI tract are the ileum, esophagus, and colon whereas duodenal cysts account for <15% of GI duplications [2].

Gastric outlet obstruction (GOO) in infants and children can either be congenital, resulting from the antral diaphragm, pyloric atresia, and infantile hypertrophic pyloric stenosis (IHPS), or acquired complicating peptic ulcer disease, caustic ingestion, tumors, chronic granulomatous disease, and eosinophilic gastroenteritis [3, 4]. Among the above pathologies, IHPS is considered to be the commonest with an estimated incidence of up to 1.5–3 per 1000 live births and responds well to Ramstedt's pyloromyotomy. The other

 OPEN ACCESS

causes are relatively rare, and, in combination, account for approximately 1 in 100,000 live births [5].

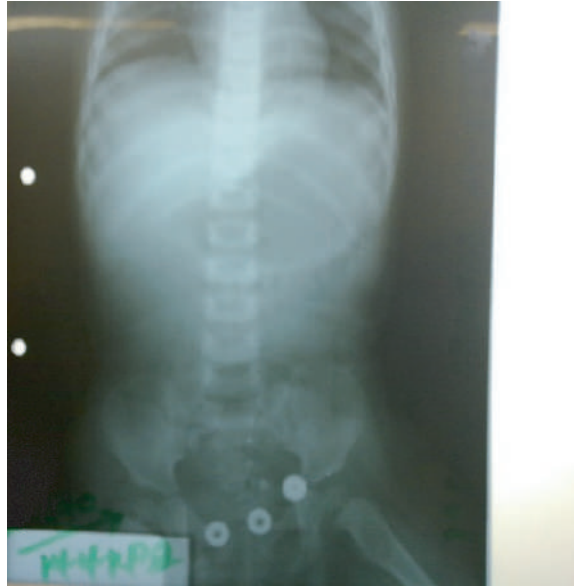

Figure 1: Normal plane X-Ray of the abdomen.

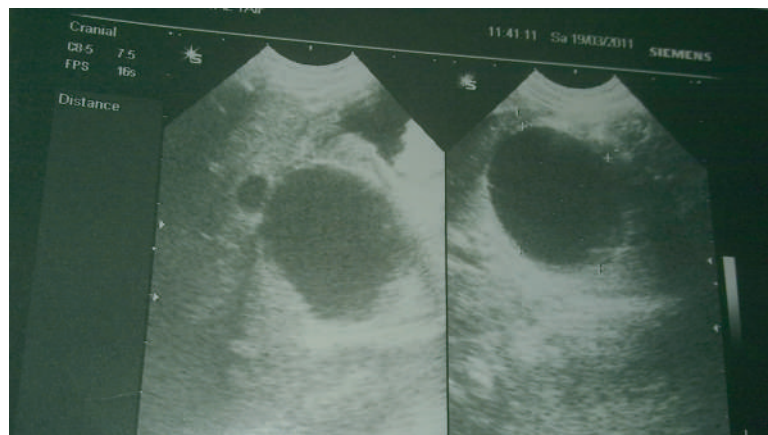


Figure 2: Ultrasound of the abdomen showing a cystic mass measuring 37x 33 mm at the epigastric region adjacent to the head of the pancreas.

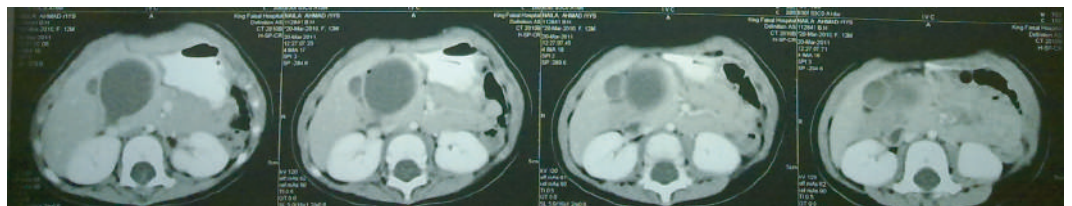


Figure 3: CT scan of the abdomen with an IV and oral contrast showing evidence of cystic structure in the first and proximal second part of the duodenum.

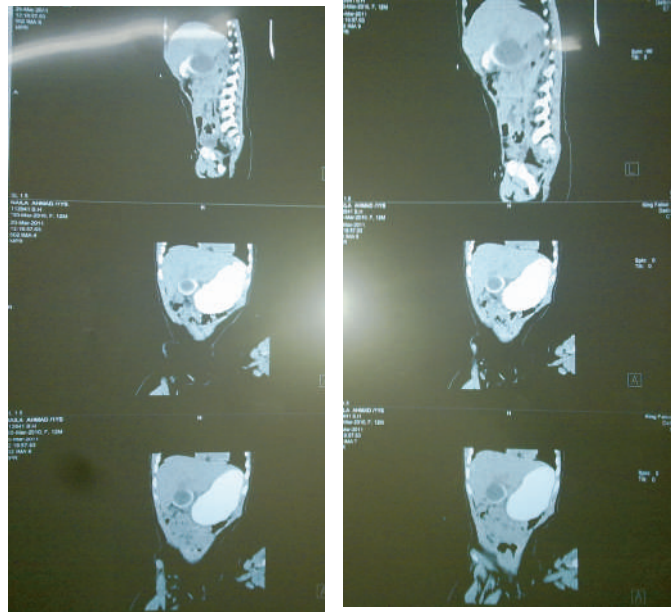


Figure 4: Magnetic Resonance Cholangiopancreatography (MRCP) showing multi-echoic, multiplanar images through the upper abdomen with evidence of a large well-defined fluid intensity signal cystic lesion in the right abdomen measuring 3 × 3.3 × 3.4 cm.

2. Case Presentation

A one-year-old female infant was admitted with a two-day history of frequent copious watery vomiting that eventually became coffee grounds. There was no history of diarrhea, fever, or urinary or respiratory symptoms. The patient has otherwise an unremarkable past medical, developmental, and family history. Physical examination was entirely normal including anthropometric measurements. The working diagnosis on admission was acute gastritis with a possible Mallory-Weiss tear.

Investigations revealed Hb 14.4 gm/dl (N 11.5–15.5 g/dL), WBC 10.7 (N 5.5–15.5 × 10⁹ cells/L), with normal differential count, platelet count 200 × 10⁹ (N 150–400 × 10⁹). C-reactive protein and arterial blood gas were normal.

RBS 74 mg/dl (N <180 mg/dl), BUN 96 mg/dl (N 20–40 mg/dl), S creatinine 0.6 mg/dl (N 0.3–1 mg/dL), Na 145 meq/l (N 138–145), K 3.7 meq/l (N 3.5–4.5). Total serum bilirubin 1.2 mg/dl (N <1 mg/dl), direct 0.18 mg/dl, AST 36 (N 15–55 U/L), ALT 38 (5–45 u/l), ALP 266 (N 145–420). Ca 10.0 mg/l (N 8.8–10.8 mg/dL), Mg 2.5 mg/l (N 1.5–2.3 mg/dL), PO4 3.5 mg/l (N 3.7–5.6 mg/dL). Serum amylase 67 u/l then 80 u/l (N 50–300 IU/l), serum lipase 350 u/l then 413u/l (N 3–32 u/l).

Prothrombin time 10.7 sec (N 11–15 sec), INR 0.86, APPT 32 sec (N 25–40 sec). Blood for culture, no growth Abdominal X-ray was normal (Figure 1). Ultrasound abdomen

showed a cystic mass measuring 37 mm × 33 mm at the epigastric region adjacent to the head of the pancreas suggesting a pancreatic pseudocyst (Figure 2).

CT scan of the abdomen with intravenous and oral contrast showed evidence of cystic structure in the first and the proximal second part of the duodenum with surrounding contrast widening the lumen indicating intraluminal lesion which seems to continue down to the lumen, this is most likely representing duplication cyst, however, other causes of cysts cannot be ruled out. The liver, spleen, both kidneys, and pancreas were normal. There was a complete obstruction of the stomach with no contrast seen post the duodenum, there was no ascites or lymphadenopathy. These findings are suggestive of duodenal duplication cyst (Figure 3).

Magnetic Resonance Cholangiopancreatography (MRCP) showed multi-echoic, multiplanar images through the upper abdomen with evidence of a large well-defined fluid intensity signal cystic lesion in the right abdomen measuring 3 × 3.3 × 3.4 cm sized located in the right subphrenic region displacing the gallbladder laterally with mass effect on the adjacent part of the head of the pancreas as well. The coronal image and MIP image showed no intra- or extra-biliary dilation, however, the common hepatic and common bile duct were displaced medially to the cystic lesion.

The gall bladder appears distended and compressed by the cystic lesion with some area of intraluminal filling defect (Figure 4).

Complementary ultrasound of the abdomen to evaluate the cyst showed again a well-defined cystic lesion with an internal echogenic mucosal layer and hypoechoic possibly muscular wall. These features most likely represent a duplication cyst of the duodenum, however, no communication of the biliary tract to the cystic lesion was observed.

Based on the above investigation results, the patient was referred for surgical management of a duodenal duplication cyst. The duodenal anatomy was unexpectedly found to be entirely normal, however, a mucoïd gelatinous material was detected inside the duodenum measuring 7.0 × 7.0 × 1.0 cm which was removed. From a histological point of view, the specimen was thought to be pseudo-myxomatous in nature with numerous fungal hyphae on Periodic Acid Schiff (PAS) stain, no human tissue was identified.

More detailed collateral history revealed that the patient used to play with small gelatinous toys that tend to get bigger when exposed to water, however, the family did not witness any previous ingestion attempts by their daughter.

3. Discussion

Foreign body impaction after oral intake is rarely associated with obstruction in adults compared to children. It is a worldwide problem and the exact figures are not known as many cases are not brought to medical attention. It was estimated that >125,000 foreign body ingestion cases were reported in patients aged up to 19 years to American Poison Control Centers in 2007 [6]. In the majority of cases, ingested foreign bodies pass without causing any complications, but in some cases, serious consequences can occur requiring special attention and immediate intervention. The challenge for primary care and emergency medicine physicians is to distinguish those patients who require intervention from the majority who can be safely observed.

The highest incidence of foreign body ingestion is reported in six-month to three-year-old with an equal male-to-female ratio [7, 8]. Children can swallow numerous objects and coins are considered to be the commonest. Other possible ingested objects include toys, batteries, needles, pins, and fish bones, particularly in countries where fish is the main diet [9].

Several conditions lead to signs and symptoms of GOO such as gastric web, pyloric atresia, ectopic pancreatic tissue, and duplication of the pylorus. One of the important acquired causes of GOO is peptic ulcer disease which has an increasing incidence in the pediatric population with complications like gastro-duodenal perforation and pre-pyloric stricture occasionally encountered [10]. In general, the course of peptic ulcer disease in children is longer than that in adults, increasing their predisposition and degree of stricture despite the advances in medical management [11].

Other causes of GOO such as pyloric atresia, pre-pyloric webs, and diaphragm can be managed by excision of the membrane and pyloroplasty. Prepyloric strictures of unknown etiology are very rare in infants, and they should be kept in mind when IHPS is ruled out.

The clinical presentation of small intestinal duplications may vary but abdominal distension and/or mass are the most common presentations. Small cystic duplications can act as lead points for small bowel intussusception or result in localized volvulus, whereas large duplications can cause compression of the adjacent intestine and obstructive symptoms. The optimal treatment for small intestine duplications is total excision. In the case of cystic duplications, this is usually accomplished by excising the duplications with its adjacent bowel with primary re-anastomosis. In long tubular duplications, attempts should be made to preserve one leaf of the mesentery to maintain blood.

4. Conclusion

There are several rare causes of GOO in children that may present with a variety of symptoms. Evaluation of such patients may require a wide range of diagnostic studies including endoscopy which was not done in our patient leading to an unnecessary operation. We were mainly guided by the results of abdominal ultrasound, CT scan, and MRCP which were all consistent with a diagnosis of a duplication cyst of the duodenum.

Acknowledgements

None.

Ethical Considerations

Verbal consent was obtained from the parents of to child to publish the case and images.

Competing Interests

The authors declare that they have no competing interests.

Availability of Data and Material

All relevant data of this study are available to any interested researchers upon reasonable request to the corresponding author.

Funding

None.

References

- [1] Jadlowiec, C. C., Lobel, B. E., Akolkar, N., Bourque, M. D., Devers, T. J., & McFadden, D. W. (2015). Presentation and Surgical Management of Duodenal Duplication in Adults. *Case Reports in Surgery*, 2015, 659150.
- [2] Liu, R., & Adler, D. G. (2014). Duplication cysts: Diagnosis, management, and the role of endoscopic ultrasound. *Endoscopic Ultrasound*, 3(3), 152–160.

- [3] Feng, J., Gu, W., Li, M., Yuan, J., Wei, M., & Zhou, X. (2005). Rare cases of gastric outlet obstruction in children. *Pediatric Surgery International*, 21(8), 635–640.
- [4] Ormarsson, O. T., Haugen, S. E., & Juul, I. (2003). Gastric outlet obstruction caused by heterotopic pancreas. *European Journal of Pediatric Surgery*, 13(6), 410–413.
- [5] Sharma, K. K., Agrawal, P., & Toshiniwal, H. (1997). Acquired gastric outlet obstruction during infancy & childhood: A report of five unusual cases. *Journal of Pediatric Surgery*, 32(6), 928–930 .
- [6] Bronstein, A. C., Spyker, D. A., Cantilena, L. R., Jr., Green, J. L., Rumack, B. H., & Heard, S. E., American Association of Poison Control Centers. (2008). 2007 Annual Report of the American Association of Poison Control Centers' National Poison Data System (NPDS): 25th Annual Report. *Clinical Toxicology*, 46(10), 927–1057 .
- [7] Alexander, W., Kadish, J. A., & Dunbar, J. S. (1969). Ingested foreign bodies in children. In H. J. Kaufmann HJ (Ed.) *Progress in Pediatric Radiology* (pp. 256–285). 2nd Ed. Chicago: Yearbook Medical Publishers.
- [8] Balci, A. E., Eren, S., & Eren, M. N. (2004). Esophageal foreign bodies under cricopharyngeal level in children: An analysis of 1116 cases. *Interdisciplinary CardioVascular and Thoracic Surgery*, 3(1), 14–18.
- [9] Watanabe, K., Kikuchi, T., Katori, Y., Fujiwara, H., Sugita, R., Takasaka, T., Hashimoto, S. (1998). The usefulness of computed tomography in the diagnosis of impacted fish bones in the oesophagus. *Journal of Laryngology & Otology*, 112(4), 360–364.
- [10] Tsang, T. M., Saing, H., & Yeung, C. K. (1990). Peptic ulcer in children. *Journal of Pediatric Surgery*, 25, 744–748.
- [11] Azarow, K., Kim, P., Shandling, B., Ein, S. (1996). A 45-year experience with surgical treatment of peptic ulcer disease in children. *Journal of Pediatric Surgery*, 31(6), 750–753.