

Original Article

Non-scalpel Vasectomy Camps: Our Experience and Recent Trends in 2021

Pankaj P Rao, Vipin V Nair, Pawan Sharma, Nilanjan Roy, and Simarjit S Rehsi

Dept of Surgery, Armed Forces Medical College, Pune, India

ORCID:

Pankaj P Rao: <https://orcid.org/0000-0002-1420-7622>

Vipin V Nair: <https://orcid.org/0000-0001-6903-6368>

Pawan Sharma: <https://orcid.org/0000-0003-4984-0708>

Nilanjan Roy: <https://orcid.org/0000-0001-6233-8929>

Simarjit S Rehsi: <https://orcid.org/0000-0002-3170-0750>

Abstract

Background: Camp approach has been advocated as an effective means of motivating the target population to adopt vasectomy as a method of permanent sterilization. There is a high degree of acceptance of Non-scalpel Vasectomy (NSV) among physicians and laypersons. With this knowledge, we organized camps and found good results which we share in this article.

Methods: Four NSV camps were organized in four different villages across India on a vehicle-mounted mobile operation theater. The meticulous and detailed planning, dissemination of information, careful execution, and post-procedure follow-up is enumerated.

Results: A total of 76 individuals underwent the operation in these camps. The mean age of the participants was 35 ± 5.2 years (range, 27–44 years). The complication rate was negligible and there was no failure of vasectomy. There was a high level of satisfaction among those who underwent this procedure as seen by the increased number wanting to undergo the procedure from places where camps were located.

Conclusion: NSV as a procedure is perceived as being simple and pain-free. Re-enforcing this fact and removing doubts, and conducting operations at the camp in an environment the client is familiar with achieved rewarding results.

Corresponding Author: Vipin V Nair; email: vipinvenugopalnair@gmail.com

Received 11 December 2021

Accepted 10 March 2022

Published 31 March 2022

Production and Hosting by
Knowledge E

© Pankaj P Rao et al. This article is distributed under the terms of the [Creative Commons Attribution License](#), which permits unrestricted use and redistribution provided that the original author and source are credited.

Editor-in-Chief:
Prof. Mohammad A. M. Ibnouf

Keywords: non-scalpel vasectomy, camp, mobile operation theater, male sterilization, vas

1. Introduction

The need to emphasize the importance of promoting small family norms requires no further elaboration. All of us are aware of the need to propagate this with a great deal of enthusiasm, zeal, and conviction. We also know that even a minor problem faced by the individuals who adopt the permanent method of sterilization brings adverse publicity causing a great setback to the program. Today, Non-scalpel Vasectomy (NSV), a refinement over the traditional technique of vasectomy, offers a simple, safe, and permanent method to control family size [1, 2].

 OPEN ACCESS

What follows is a brief account of the multiple NSV camps conducted at different field locations. The operations were conducted in a well-equipped vehicle-mounted mobile operation theater, which was taken to these locations. This article aims to share the experience gathered during these successful camps and the lessons learned.

2. Materials and Methods

NSV camps were organized with the help of the government at different villages in Northeastern India between August and October of 2019. The camps were organized with the support of local Public Health Centers (PHC) and the involvement of local healthcare workers. Announcements were made one week in advance through public announcement systems and publicity literature. The literature disseminated knowledge on all aspects of NSV including the anatomy, physiological basis, the procedure, and anticipated complications [3].

The availability of suitably modified vehicle made running these camps possible (Figure 1). This vehicle contained a mobile operation theatre (OT) with a single foldable seat cum table. The vehicle was also equipped to receive electrical supply from an exterior source with help of cables. There was sufficient room for keeping and sterilizing the instruments. Before starting the camp, the mobile OT was thoroughly checked, especially for electric and plumbing issues. It was thoroughly fumigated and sterility ensured. The manpower included a surgeon, an OT assistant, housekeeping staff, and a driver. For monitoring, dispensing, and recordkeeping, a healthcare worker available with the PHC was utilized.

We carried enough material to be able to perform 30 vasectomies. Eight NSV instrument sets were obtained from the Family Welfare Center of District Hospital. Each set consisted of one extracutaneous vas fixation forceps (Figure 2), one vas dissecting forceps (Figure 3), a small stainless-steel bowl, one sponge holder, and a Mayo's Scissors. In addition, 30 sterile sets each containing six gauze pieces, a disposable patient cover of 2-0 silk were also catered. Gloves, caps, masks, gowns, suspensory bandages, sticking plaster, syringes (5 ml), and needles were kept as per requirement. Scrubbing, cleaning, sterilizing, and fumigation material like detergent, Savlon, Cidex solution, povidone iodine, spirit, formalin, and potassium permanganate were also catered. Basic antibiotics and analgesics were kept.

The crash cart was made with injection Lignocaine, Atropine, Adrenalin, Deriphylline, Hydrocortisone, Antihistaminic, Diazepam, Dopamine, Pethidine, Soda bicarbonate, adequate IV Fluids, IV sets. Oxygen cylinders, surgical airways, endotracheal tube,



Figure 1: Mobile operating van.

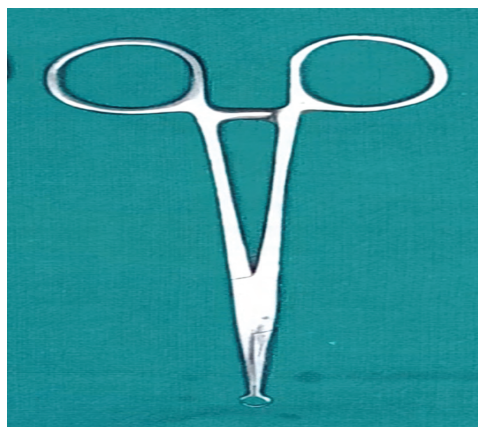


Figure 2: Extracutaneous vas holding forceps.

laryngoscope, portable suction, and battery-operated pulse oximeter were catered for emergency needs.

A day before setting up the camp, a clean area with access to water and electricity was selected. The mobile OT vehicle was deployed and the canopy was opened. Tarpaulin was laid and a tent pitched nearby to act as the pre-op area, dispensary, and post-op place. This tent had one bed with resuscitation equipment and emergency drugs laid out. The canopy acted as the registration and dispensing area. The vehicle was

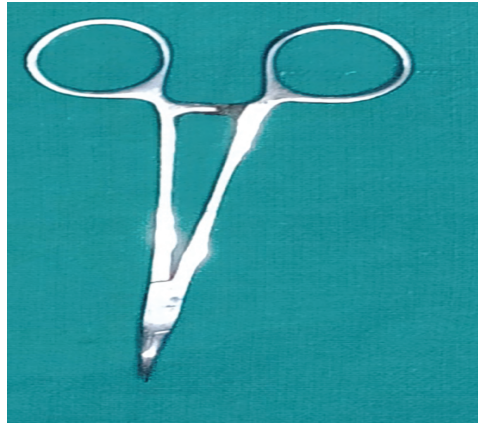


Figure 3: vas dissecting forceps.

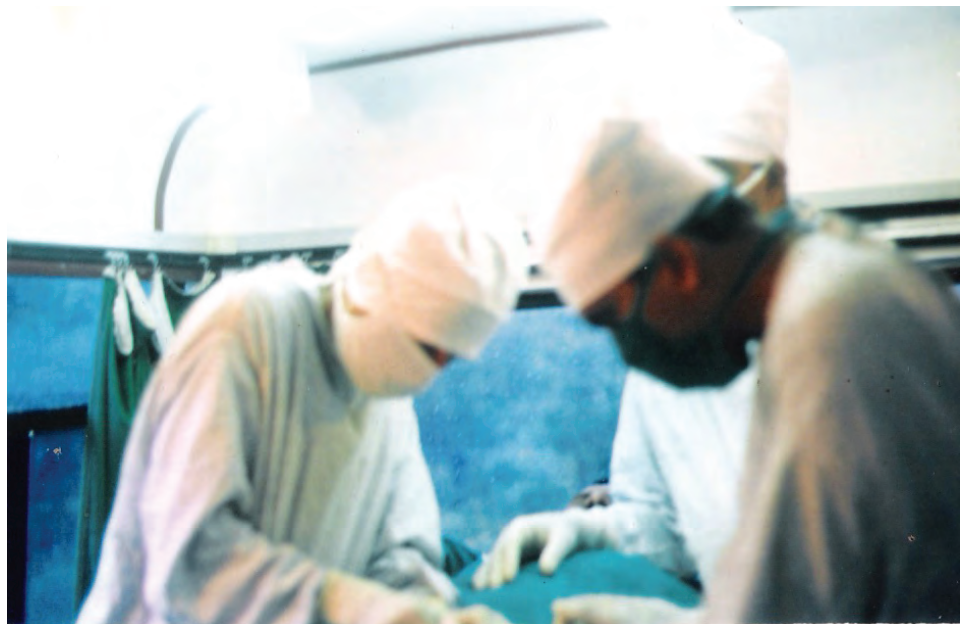

Figure 4: Surgery in progress in mobile van.

fumigated and the area around cleaned. The volunteers were briefed and their doubts cleared. Next, a list of volunteers was made and written consent was obtained after detailed pre-op and post-op instructions were given. Prepared charts of instructions were also displayed at the campsite. We aimed to perform at least 20 operations in one day. All individual volunteers were informed according to the registration list of the approximate time to report for the operation.

On the day of the camp, the operation theatre, dispensary, resuscitation bed, and registration were made ready as per protocol. Before the first operation and subsequently after each break, the assistant and the surgeon thoroughly scrubbed as one would before any surgery (Figure 4). Fresh caps, masks, and gowns were worn after each break. After each operation, gloves were removed hand cleaned with satellitium

before putting on sterile gloves. The scrotum was cleaned with Savlon and then 5% povidone iodine and draped. Great care was taken to avoid any breach in sterility. After each operation, the instruments were cleaned, dried, and kept in Cidex trays. As we had eight sets, the instruments were left in Cidex for at least 1 hr before they were reused.

The standard NSV procedure was employed [4, 5]. Preoperative medication injection Pethidine 25 mg and Atropine 0.4 mg were given intramuscularly to all volunteers 30 min before the procedure. Local anesthesia with an injection of 1% Plain lignocaine was used; 2 ml injected near the pubic tubercle on each side and 1 ml on the midline at the junction of upper one-third and lower two-thirds. A small puncture wound was made at this site using dissecting forceps. This puncture would only permit the introduction of ring forceps. The vas was isolated from the surrounding tissues and using the three-finger technique brought near the puncture wound. With the ring forceps introduced in the puncture wound, one wall of the vas was held. The tissues over the vas were bared using the dissecting forceps. This made the vas entirely visible, which was easily picked up by going around it with the help of dissecting forceps. The ring forceps were now encircled over the full thickness of vas. One cm of the bare vas was excised, ligated, and reposed back into the scrotum.

Medical waste generated was collected in color-coded plastic bags and brought back to the hospital to be disposed of as per the existing biomedical waste disposal policy. Each resected vas was marked as per the patient particulars and side of surgery. The specimens were sent for confirmation by the pathologist. All patients operated in the day were interviewed late in the evening for any problems. The opposite vas was brought near the puncture wound in exactly the same manner, held partially with the ring forceps, vas bared, delivered with the ring forceps, one cm excised ligated, and put back into the scrotum. The most important step before delivering the vas back into the scrotum is to ensure that there is no bleeding from around the dissected vas. We would spend an extra minute to check that and after being fully convinced that the field is dry, the cut ends were reposed back into the scrotum. No stitch was required, and the puncture wound was dressed in a piece of small gauze. A snugly fitting scrotal support was given. All of them were given Tab Ciprofloxacin 500 mg twice daily for three days and Tab Diclofenac Sodium 75 mg twice daily for two days. Although studies have shown that no antibiotics are required, we gave antibiotics to ensure that no complications arose [6].

The volunteers were sent back after the operation and asked to report immediately in case of any pain or swelling in the scrotum. The volunteers were advised to resume normal work after 48 hr and full physical activity after one week. They were also instructed

to have an alternate method of contraception till the semen analysis becomes negative for no spermatozoa. The first review was done after 10 days with a histopathological report for confirmation of vas. A final sterilization certificate was given after 12 weeks on confirmation of completed NSV with negative semen report [7]. The descriptive data were tabulated and analyzed using IBM SPSS version 25.

3. Results

In total, 76 male patients were operated on in four different camps. All patients were volunteers from villages aged between 27 and 44 years (mean 35 ± 5.2 years). While 9 of them had a single child, 62 had two children and 5 had more than two.

Moreover, 28 (36.84%) men had mild pain described as discomfort lasting up to three days following the operation. Three cases (3.95%) had pain lasting up to one month after the operation. Of these, two had nonspecific dull pain requiring no medication, while one had sharp shooting pain usually following intercourse. On examination of this individual, there was no swelling, cyst, or tenderness. The skin wound had healed well. The pain gradually subsided on its own. There was no local infection, hematoma, or spermatocele. The vas was confirmed histopathologically in all cases bilaterally. All men had semen analysis negative for spermatozoa after three months following operation and were awarded a sterilization certificate.

4. Discussion

NSV also known as the keyhole vasectomy is a surgical technique initially developed in the 1980s in China to alleviate men's fear from the word incision with a scalpel as in surgery. Dr Li Shunqiang from Chongqing Family Planning Scientific Research Institute, Sichuan, China is considered to be the original inventor of this procedure in China [8]. This simple procedure is presently used in more than 40 countries around the world as part of their public health programs [9]. In India, NSV was introduced in 1998 under the national rural health mission. Dr RCM Kaza was one of the pioneers of NSV in India.

Since then, NSV is offered at many government hospitals and public health centers in India. To extend the reach, sterilization camps are organized across the country. The key factor that motivates individuals for any program is knowledge [2]. Bearing this in mind, to make the NSV camp successful, a detailed campaign was launched. All required information regarding NSV was dispatched well in advance. Local doctors and PHC staff were specially told to organize lectures and informal talks to answer queries

and dispel doubts. A pictorial chart explaining anatomically the procedure was found helpful in motivating individuals. This was revealed by the majority of individuals during an informal talk with the volunteers.

Special efforts were made to avoid complications as much as possible. Complications of NSV include hematoma, genitourinary infections, traumatic fistulas, orchialgia, and recanalization of the vas. Vasectomy failure is documented to occur in around 2% [10]. Knowing that any small complication would be a setback to the entire exercise, extra precautions were taken at each step. The time taken for each case may appear a little more; this was because we did not want any breach in sterility. NSV is a pain-free and reliable procedure and the postoperative period is usually devoid of complications. The fact about it being less painful and complication-free as compared to conventional vasectomy is well documented [3, 11]. Preference of operation, camp approach, and quality of care were listed as the three most important aspects motivating individuals to accept vasectomy [5, 12]. Besides, NSV offers a shorter operating time and faster recovery than any other technique of vasectomy [13, 14].

“Well-planned vasectomy camps, with adequate pre and postoperative care, counseling, supply of medicines should be organized frequently” is the recommendation given unanimously by all researchers who have written about male sterilization in India [2, 5, 6, 15]. It was for this reason that we decided to organize an NSV camp and chose to operate at a place away from a hospital, despite the obvious disadvantage, to reach out to the targeted clientele.

Moreover, efforts were made to make the procedure as pain-free and comfortable as possible. Care was also taken to keep the complications at a minimal level. The word-of-mouth publicity and sharing of personal experiences by those who underwent the procedure were so effective that many volunteers from the locality came for NSV to the hospital after the camp was over. Our results of postoperative complications compare well with figures from the world over [3]. A review of data from other studies involved in organizing such camps was of great help.

There was some fear regarding vasectomy and the development of various diseases post vasectomy such as testicular carcinoma, cardiac diseases due to autoantibodies, and prostate cancer. Duan *et al.* in their large meta-analysis of 2176 testicular cancer patients in eight studies from 1980 to 2017 proved that there is no correlation between testicular carcinoma and vasectomy [16]. However, Husby *et al.* believed that there is a high risk of prostatic carcinoma after vasectomy. They studied a cohort of Danish men born between 1937 and 1996. It was found that there was a relative risk of 1.15 with a 95% confidence interval from 1.10 to 1.20. The increased risk persisted for up

to 30 years post vasectomy [17]. However, this was negated by Bhindi *et al.* in their large systemic review and meta-analysis done in 2017. They analyzed 53 studies with 14,700,000 participants and concluded that there is no association between prostate carcinoma and vasectomy [18].

Gou *et al.* in 2017 conducted a meta-analysis of 12 studies with 299,436 participants. In their study they concluded that there is no excessive risk or increase in risk for cardiovascular disease post vasectomy [19].

Another much-discussed complication post vasectomy is the incidence of post vasectomy pain. Auyeung *et al.* in 2020 published their systematic review and meta-analysis on the incidence of post vasectomy pain in traditional procedures and NSV. They included 18 studies up to July 2019 for analysis and found that the incidences of post-vasectomy pain following scalpel and non-scalpel techniques were 24% (95% CI 15%–36%) and 7% (95% CI 4%–13%), respectively.

Post-vasectomy pain syndrome, which is a diagnosis of exclusion, occurred in 5% (95% CI 3%–8%) of men in both groups. Hence, they concluded that the occurrence of post-vasectomy pain syndrome is similar to the conventional technique. NSV has three times lesser post-vasectomy pain than other techniques [20]. In this series, only 3% of our cases developed pain post NSV. However, the pain was reduced with symptomatic management and counseling.

Kreutzig *et al.* in their recent article settle all dust as NSV is the contraception of choice without any side effects. It is documented that approximately <6% of men post vasectomy request for recanalization. And with experienced surgical hands, the refertilization rate is up to 90%. Hence even though it is a permanent method of sterilization, if needed there is a great possibility for reversal [21, 22].

5. Conclusion

Non-scalpel vasectomy has come to be accepted as a procedure with fewer complications by physicians as well as patients. Dispelling the doubts and dissemination of advantages of the technique to the target population helps motivate them to adopt this method readily. The final and most important step is to organize such camps with maximum precautions to deliver high-quality results.

Acknowledgements

Nil.

Ethical Considerations

Necessary approval was taken from the Institutional Review Board and informed consent was obtained from next of kin.

Competing Interests

Nil.

Availability of Data and Material

Available upon reasonable request.

Funding

Nil.

References

- [1] Amory, J. K. (2016). Male contraception. *Fertility and Sterility*, vol. 106, no. 6, pp. 1303–1309.
- [2] Rogers, M. D. and Kolettis, P. N. (2013). Vasectomy. *Urologic Clinics of North America*, vol. 40, no. 4, pp. 559–568.
- [3] Kaza, R. C. M. (2001). No-scalpel vasectomy-experience from the field. *Health*, vol. 27, no. 3, pp. 27–29.
- [4] Dassow, P. and Bennett, J. M. (2006). Vasectomy: an update. *American Family Physician*, vol. 74, pp. 2069–2074.
- [5] Sharlip, I. D., Belker, A. M., Honig, S., et al. (2012). Vasectomy: AUA guideline. *Journal of Urology*, vol. 188, no. 6, pp. 2482–2491.
- [6] Seenu, V. and Hafiz, A. (2005). Routine antibiotic prophylaxis is not necessary for no scalpel vasectomy. *Journal International Urology and Nephrology*, vol. 37, no. 4, pp. 763–765.
- [7] Dassow, P. and Bennett, J. M. (2006). Vasectomy: an update. *American Family Physician*, vol. 74, no. 12, pp. 2069–2074.
- [8] Engender Health. (1997). *No-scalpel vasectomy: an illustrated guide for surgeons*. New York: Engender Health.

- [9] Shattuck, D., Perry, B., Packer, C., et al. (2016). A review of 10 years of vasectomy programming and research in low-resource settings. *Global Health: Science and Practice*, vol. 4, no. 4, pp. 647–660.
- [10] Awsare, N. S., Krishnan, J., Boustead, G. B., et al. (2005). Complications of vasectomy. *Annals of the Royal College of Surgeons of England*, vol. 87, no. 6, pp. 406–410.
- [11] Amundsen, G. A. and Ramakrishnan, K. (2004). Vasectomy: a "seminal" analysis. *Southern Medical Journal*, vol. 97, no. 1, pp. 54–60.
- [12] Murthy, S. R. and Rao, M. D. (2003). An analysis of factors influencing the acceptability of vasectomy in Andhra Pradesh. *Health and Population-Perspectives and Issues*, vol. 26, no. 4, pp. 162–182.
- [13] Clenney, T. L. and Higgins, J. C. (1999). Vasectomy techniques. *American Family Physician*, vol. 60, no. 1, pp. 137–146.
- [14] Cook, L. A., Pun, A., Gallo, M. F., et al. (2014). Scalpel versus no-scalpel incision for vasectomy. *Cochrane Database of Systematic Reviews*, vol. 2014, no. 3, CD004112.
- [15] Das, H. C. and Bhattacharjee, J. (1993). No-scalpel vasectomy: hope for the future. *Journal of Family Welfare*, vol. 39, pp. 14–16.
- [16] Duan, H., Deng, T., Chen, Y., et al. (2018). Association between vasectomy and risk of testicular cancer: a systematic review and meta-analysis. *PLoS One*, vol. 13, no. 3, p. e0194606.
- [17] Husby, A., Wohlfahrt, J., and Melbye, M. (2020). Vasectomy and prostate cancer risk: a 38-year nationwide cohort study. *Journal of the National Cancer Institute*, vol. 112, no. 1, pp. 71–77.
- [18] Bhindi, B., Wallis, C. J. D., Nayan, M., et al. (2017). The association between vasectomy and prostate cancer: a systematic review and meta-analysis. *JAMA Internal Medicine*, vol. 177, no. 9, pp. 1273–1286.
- [19] Guo, Z. L., Xu, J. L., Lai, R. K., et al. (2017). Vasectomy and cardiovascular disease risk: a systematic review and meta-analysis. *Medicine*, vol. 96, no. 34, p. e7852.
- [20] Auyeung, A. B., Almejally, A., Alsaggar, F., et al. (2020). Incidence of post-vasectomy pain: systematic review and meta-analysis. *International Journal of Environmental Research and Public Health*, vol. 17, no. 5, p. 1788.
- [21] Kreutzig, L. T., Lellig, E., Hinz, P., et al. (2021). Aktuelle informationen [Vasectomy: current information]. *Urologe A*, vol. 60, no. 4, pp. 523–532.
- [22] Dickey, R. M., Pastuszak, A. W., Hakky, T. S., et al. (2015). The evolution of vasectomy reversal. *Current Urology Reports*, vol. 16, no. 6, p. 40.