

Research Article

Practice and Perception of Radiographers on the Positioning Techniques of Erect Lateral Cervical Spine Radiography in Non-trauma Adult Patients

B.S. Weerakoon*, I.G.N.N.K. Karunaratne, and J.M.W.S. Jayasundara

Department of Radiography & Radiotherapy, Faculty of Allied Health Sciences, University of Peradeniya, Peradeniya, 20400, Sri Lanka

ORCID:

B.S. Weerakoon: <https://orcid.org/0000-0003-0843-6389>

Abstract

Background: The visualization of the lower cervical spine (C-spine), including the C7-T1 junction on lateral radiograph is a challenge due to the overlapping of the shoulder girdle. Therefore, the radiographers have adapted different positioning strategies to overcome this challenge. This study explores the current practice and perception of radiographers on positioning techniques of erect lateral cervical spine radiography in non-trauma adult patients.

Methods: This prospective study was conducted with a self-administered, structured questionnaire distributed among 50 radiographers working in four selected hospitals in Sri Lanka.

Results: The radiographers used weight-bearing and non-weight-bearing positioning techniques for the erect lateral C-spine radiography. Most of them employed the standing breath-holding technique for image acquisition with or without exertion. While 54% of the radiographers utilized two water-filled cans during the weight-bearing technique, 82% used holding arms back with the shoulders down and pulling as low as possible in the non-weight-bearing technique. In addition, 88% of the radiographers believed that the weight-bearing position could increase the visibility of the C-spine. Almost all the radiographers (100%) stated that correct positioning instruction could improve the visibility of the C-spine.

Conclusion: Radiographers have mainly used two positioning techniques of weight-bearing and non-weight-bearing for erect lateral C-spine radiography for non-trauma adult patients. In addition, most radiographers had a positive attitude toward the weight-bearing technique in the evaluation of lateral C-spine. These results highlight the importance of conducting studies to evaluate the effectiveness of the weight-bearing technique in erect lateral C-spine radiography.

Keywords: cervical spine, erect lateral radiography, positioning techniques, current practice, non-trauma adult patients

Corresponding Author: B.S. Weerakoon; email: bsw888@gmail.com

Received 06 October 2021
Accepted 18 November 2021
Published 31 December 2021

Production and Hosting by
Knowledge E

© B.S. Weerakoon et al.. This article is distributed under the terms of the [Creative Commons Attribution License](#), which permits unrestricted use and redistribution provided that the original author and source are credited.

Editor-in-Chief:
Prof. Mohammad A. M. Ibnouf

OPEN ACCESS

1. Introduction

Although computed tomography (CT) and magnetic resonance imaging (MRI) have been able to advance the imaging of the cervical spine (C-spine), plain radiography still plays a vital role in the initial assessment of any type of cervical spine injury due to its abundant availability and cost-effectiveness [1, 2]. The lateral view of the C-spine is an important examination in radiographic assessment as it can demonstrate all seven cervical vertebrae with their alignments and the cervico-thoracic (C7-T1) junction where 9–18% of injuries to the cervical region are found [3–5]. However, due to the overlap of the shoulder girdle and other anatomical structures such as the rib cage (Figure 1), it is challenging to demonstrate the lower cervical vertebrae with the C7-T1 junction on lateral radiographs of the C-spine [3, 6, 7]. Therefore, different positioning techniques are proposed and adapted by researchers and radiographers to overcome this challenge [3, 8, 9]. However, there is inadequacy in guidelines and directives for the use of different positioning techniques in the erect lateral C-spine radiography. Nevertheless, a good positioning technique is significant in order to obtain correct diagnostic information and minimize unnecessary radiation exposure to a patient [10, 11].

Inadequate awareness of usefulness could be a reason for the underuse of the recommended positioning techniques. Therefore, it is essential to understand the current practice as it can explain the application of the optimal positioning techniques, the practical difficulties involved, and the level of awareness of the radiographers about positioning techniques. This study explores the current practice and perception of radiographers on positioning techniques of erect lateral cervical spine radiography in non-trauma adult patients. The outcomes of this study can be used to enhance the awareness of radiographers about the positioning techniques of erect lateral C-spine radiography, and thereby promote an accurate diagnosis through the effective usage of positioning techniques.

2. Materials and Methods

This prospective study was conducted at four selected government hospitals in Sri Lanka. Using the purposive sampling technique, 63 radiographers working in the plain radiography units were selected for the study.

Data were collected using a self-administered structured questionnaire. The questionnaire consisted of two sections. While the first section was dedicated to the collection of demographic data such as education level and years of experience in radiography,

the second part was dedicated to investigating the current practice of the positioning technique of the erect lateral C-spine radiography. A pilot study was conducted with four randomly selected radiographers (one from each hospital) to determine the readability, clarity, and comprehensiveness of the questionnaire. Based on the responses received, the questionnaire was edited to correct minor ambiguities.

The Statistical Package for Social Science (SPSS) v.20 was used for data analysis. The sample was described using frequency distributions. The non-parametric Chi-square test was used to identify the significant differences between the variables. P -value < 0.05 was considered significant.

3. Results

A total of 50 questionnaires were returned with a response rate of 79%. Overall, 92% (46) of the respondents had a diploma in diagnostic radiography and only 8% (04) had a degree or postgraduate qualification in diagnostic radiography. The majority of the radiographers (82%, 41) had more than five years of professional experience (Table 1).

As demonstrated in Figure 3, the radiographers who participated in this study primarily used weight-bearing and non-weight-bearing positioning techniques for the erect lateral C-spine radiography. The majority of radiographers (76%, 38) stated that they would choose one of the above positioning techniques depending on the indication and the condition of the patient. Besides, 28% (14) of the radiographers claimed that they apply the weight-bearing position for all sufficiently capable patients. In the meantime, 24% (12) claimed that they only use the weight-bearing position for obese and short neck patients depending on their ability to perform. The majority of radiographers use the standing breath-holding technique to obtain lateral C-spine radiographs (Tables 2 and 3) with both weight-bearing and non-weight-bearing techniques. As shown in Table 2, 54% (27) of the participants utilized two water-filled cans during the weight-bearing positioning, followed by sandbags (20%, 10). Holding arms back with the shoulders down and pulling as low as possible was the highest (82%, 41) reported position in the non-weight-bearing technique.

When considering the radiographers' perception, 88% (44) of the participants believed that a weight-bearing position could increase the visibility of the C-spine than a non-weight-bearing position. Further, all radiographers (100%, 50) mentioned that correct instruction during positioning can increase the visibility of the C-spine. Patient discomfort (66%, 33) and extended time taken for a procedure (46%, 23) are the most common hindrances that radiographers have identified when performing lateral

radiography of the erect C-spine in non-trauma adult patients (Figure 3). There is no significant association between the years of professional experience with the type of positioning technique used, the breathing instructions given, and the positive attitude toward the weight-bearing technique (Table 4).

4. Discussion

The positioning of the patient in C-spine radiography is significant as it facilitates patient stability, clear exposure, and accurate diagnosis through correct anatomical positioning [12]. The obstruction of the visibility of the lower cervical vertebrae by the shoulder girdle and certain other anatomical structures make positioning difficult in erect lateral C-spine radiography [3, 6, 7]. Therefore, different positions are used and suggested by researchers and radiographers to minimize the difficulties and challenges associated with the practical demonstration of lower cervical vertebrae [3, 8, 9] This study explores the current practice and perception of radiographers about positioning techniques of erect lateral cervical spine radiography in non-trauma adult patients.

In general, the lateral erect C-spine radiography is performed in both sitting [13, 14] and standing positions [15, 16]. In this study, the majority of radiographers employed the standing position. The standing position is generally considered to be a comfortable and functional posture for spinal radiography. Previous researchers have used the standing position to assess the sagittal alignment of the C-spine [16, 17] However, a standing position with arms by the sides prevents adequate visualization of the lower cervical spine [18]. Therefore, one of the customized positioning techniques should be used based on patient's capabilities. The use of the weight-bearing position in the lateral C-spine radiograph as an adjunct to improve the visualization of the lower C-spine is suggested [8]. However, no study was found in the literature that evaluates the effectiveness of the above technique. Holding a weight in each hand is expected to project the shoulder masses below the level of C7. However, for the instances where patients tend to hunch their shoulders when attempting to firmly hold the weights, the desired anatomy will be obscured. Therefore, this technique can be counterproductive insisting on a clear and proper explanation [19].

Several previous researchers have proposed different positioning strategies for lateral C-spine radiography to improve the visibility of the lower cervical vertebrae. However, each strategy has its own strengths and weaknesses. Certain studies have observed the effects of the swimmer's view [3, 5, 20], supine oblique view [20], and arm traction technique [16, 21–23] on improving the visibility of lateral C spine radiography. However,

with the availability of many such strategies, it was revealed that the radiographers in this study have primarily used only the two positioning techniques of weight-bearing and non-weight-bearing for the erect lateral C-spine radiography. Alternative positioning techniques such as the swimmer's view may increase the time spent as it requires additional time for handling the patient. Therefore, the results of the current study could be due to heavy workloads leading to time constraints or the scarcity of knowledge of other positioning techniques among radiographers.

All radiographers in this study correctly recognized the fact that the lateral cervical spine radiography can be significantly improved with the use of proper breathing instruction [24]. In addition, this study found that most radiographers, with or without a weight-bearing technique, often instructed patients to hold their breath for lateral cervical radiography. Most available resources suggested performing this examination with arrested expiration or full exhalation in order to lower the shoulders well out of the region of interest [8, 19].

In this study, the non-weight-bearing technique was primarily performed by the radiographers in the position of holding arms behind the back and pulling the shoulders down as low as possible. This technique helps the shoulder to be moved inferiorly and produce a clear view of the C-spine anatomy [24]. However, this downward pull can exacerbate an unstable injury. Therefore, prior to using this technique, it should be ensured that the patient is at a low risk of being further subjected to unstable injuries by assessing their clinical and physical symptoms [25]. According to the current study results, the patient's discomfort and time expenditure are the greatest challenges encountered in the erect lateral cervical spine radiography. To ensure the visibility of the upper anterior cervical vertebra and posterior arch of the atlas, it is necessary to avoid the overlap of the angle of the mandible and occipital bone [26]. This requires bending or extending the head, and it might cause discomfort to the patient. Further, it is impossible to obtain a good-quality radiograph without proper immobilization despite the significant amount of time that it requires [27].

5. Strengths and Limitations

There are certain limitations to this study. Only 8% of the radiographers in this study had a degree or postgraduate qualifications making it hard to determine the impact of education level on other variables. Hence, it is recommended that this study be repeated with a relatively equal number of graduates and non-graduates to determine the impact of education on their practice and attitudes. Moreover, due to its feasibility,

TABLE 1: Demographic characteristics of the participants.

Variables		Percentage% (n)
Education level	Diploma	92 (46)
	Graduate	4 (02)
	Postgraduate	4 (02)
Professional experience (yr)	0–5	18 (09)
	6–10	38 (19)
	>10	44 (22)

TABLE 2: Details of the weight-bearing position.

Weight-bearing position		
Positioning techniques		Percentage% (n)
Posture	Standing	72 (36)
	Sitting	0 (00)
	Both standing and sitting	12 (06)
	No response	16 (8)
Breathing instructions	Not given	8 (4)
	Holding breath	54 (27)
	Suspended inspiration	0 (00)
	Suspended expiration	22 (11)
	Missing	16 (08)
Type of the weight	Two water-filled cans	54 (27)
	Two sandbags	20 (10)
	Both	10 (05)
	No response	16 (08)

only the radiographers in four selected government hospitals were included in this study. Therefore, this study does not represent the entire population of radiographers across Sri Lanka, thus, it is recommended to conduct further research with a larger sample representing the radiographers from different regions in the country. However, this study is significant as there are no published studies available on this topic. Further, this study provides baseline information to the imaging field about the usage of positioning techniques, although there are many recommended advanced techniques available. Additionally, by assessing the current practice and the perception, it is possible to identify the value of strengthening the continuing education programs for radiographers.

TABLE 3: Details of the non-weight-bearing position.

Non-weight-bearing position		
Positioning techniques		Percentage% (n)
Posture	Standing	78 (39)
	Sitting	0 (00)
	Both standing and sitting	14 (07)
	No response	8 (04)
Breathing instructions	Not given	8 (04)
	Holding breath	64 (32)
	Suspended inspiration	0 (00)
	Suspended expiration	20 (10)
Types of positioning	No response	8 (04)
	Arms by sides with relaxed shoulders against the vertical cassette holder	2 (01)
	Arms by sides with relaxed shoulders as far down and forward as possible	8 (04)
	Arms hold behind the back with shoulders down and pull them down as low as possible	82 (41)
	No response	8 (04)

TABLE 4: Association between the years of professional experience and other variables.

Variables	Type of positioning technique (weight-bearing/non-weight-bearing)	Breathing instructions (weight-bearing)	Breathing instructions (non-weight-bearing)	Positive attitude towards the weight-bearing technique
Professional experience (yr)	0.51	0.22	0.12	0.58

6. Conclusion

Although many strategies are available, the radiographers in this study have mainly used two positioning techniques of weight-bearing and non-weight-bearing for the erect lateral C-spine radiography of non-trauma adult patients. This highlights the urgency of providing regular, continuous professional development programs to radiographers to uplift their awareness on different radiological techniques. Further, most radiographers had a positive attitude toward the weight-bearing technique when assessing the lateral C-spine. This finding shows the importance of conducting studies to assess the effectiveness of the weight-bearing technique in the erect lateral cervical spine radiography.

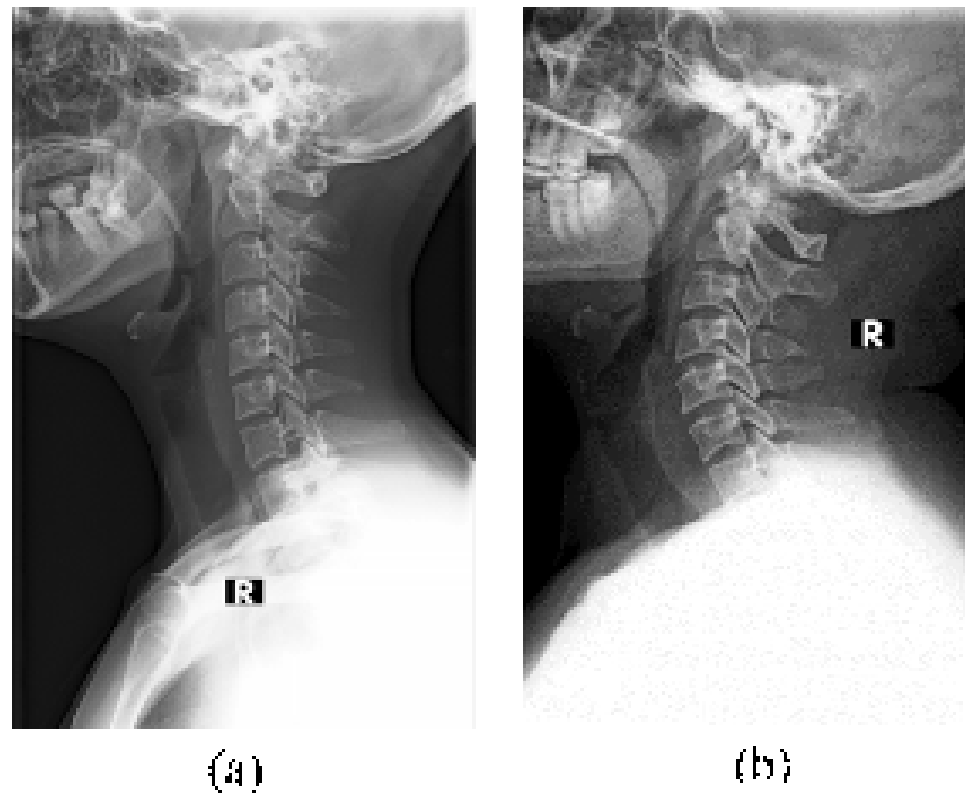


Figure 1: Erect lateral cervical spine radiographs. (a) The lower cervical spine and the C7-T1 junction are not obscured by the musculoskeletal structures. (b) The lower cervical spine and the C7-T1 junction are obscured by the musculoskeletal structures.

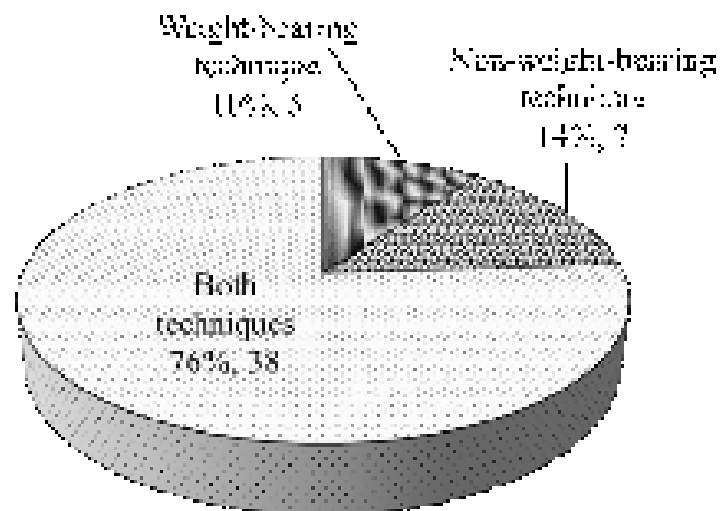


Figure 2: Practice of weight-bearing and non-weight-bearing positioning techniques.

However, it is essential to conduct further studies with larger samples to confirm and elevate the reliability of the results.

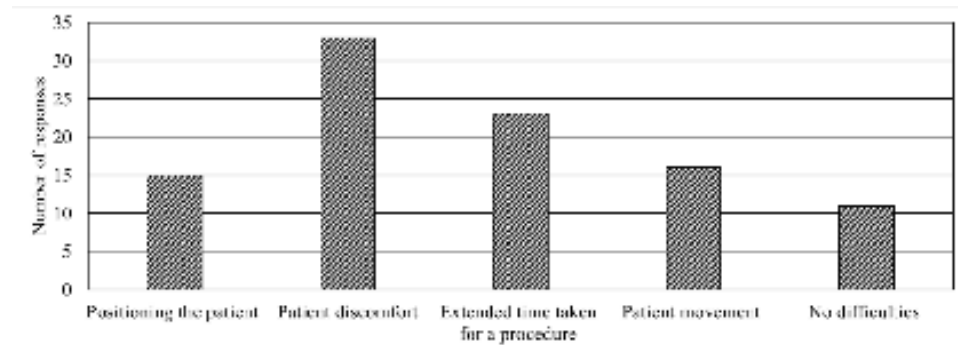


Figure 3: Challenges in erect C-spine lateral radiography of the non-trauma adult patients.

7. Acknowledgements

The authors would like to thank all hospitals involved in this study for granting permission to collect data. They would also like to express their sincere appreciation to all participants and parties who contributed to the successful completion of this study.

8. Ethical Considerations

Ethical approval was granted by the Ethics Review Committee of the Faculty of Allied Health Sciences, University of Peradeniya. Permission to conduct the study was obtained from all selected hospitals. Written consent was obtained from the participants prior to data collection, and voluntary participation was emphasized. The participants were assured of the confidentiality of their responses.

9. Competing Interests

The authors declare that there is no conflict of interest related to this study.

10. Funding

This research did not receive any specific grant from funding agencies in the public, commercial, or not-for-profit sectors.

References

- [1] Izzo, R., Popolizio, T., Balzano, R. F., et al. (2019). Imaging of cervical spine traumas. *European Journal of Radiology*, vol. 117, pp. 75–88.

- [2] Joaquim, A. F., Ghizoni, E., Tedeschi, H., et al. (2015). Radiological evaluation of cervical spine involvement in rheumatoid arthritis. *Neurosurgical Focus*, vol. 38, no. 4, pp. 1–7.
- [3] Toksoy, A., Bektas, F., Eken, C., et al. (2010). Value of the swimming position and arm traction in visualizing the cervicothoracic junction over the standard lateral cervical X-ray. *International Journal of Emergency Medicine*, vol. 3, no. 2, pp. 85–90.
- [4] Rhea, J. T., Rao, P. M., and Novelline, R. A. (1998). The normal cervical spine and its variations on plain radiography and computed tomography. *Emergency Radiology*, vol. 5, no. 1, pp. 13–28.
- [5] Rethnam, U., Yesupalan, R. S. U., and Bastawrous, S. S. (2008). The Swimmer's view: does it really show what it is supposed to show? A retrospective study. *BMC Medical Imaging*, vol. 8, article 2.
- [6] Truong, V. T., Al-Shakfa, F., Boubez, G., et al. (2020). Enhanced visualization of the cervical vertebra during intraoperative fluoroscopy using a shoulder traction device. *Asian Spine Journal*, vol. 14, no. 4, pp. 502–506.
- [7] Wongwaisayawan, S., Suwannanon, R., and Kaewlai, R. (2013). Imaging of cervicothoracic junction trauma. *Reports Medical Imaging*, vol. 6, no. 1, pp. 11–27.
- [8] Whitley, A. S. (2015). *Clarks Positioning In Radiography* (13th ed.). CRC Press.
- [9] Rauck, R., Stammen, K., Yu, E., et al. (2016). Novel intraoperative technique to visualize the lower cervical spine: a case series. *American Journal of Orthopedics*, vol. 45, no. 2, pp. 46–49.
- [10] Maruyama, T. and Yamamoto, H. (2008). Study of positioning techniques for radiography. *Nippon Hoshasen Gijutsu Gakkai Zasshi*, vol. 64, no. 1, pp. 25–34.
- [11] Kapur, N., Nargotra, N., Singh, T., et al. (2019). Study of proper technique to avoid repeat radiography with proper instructions and positioning. *International Journal of Radiation Research*, vol. 33, pp. 33–37.
- [12] Du, L., Gao, Y., Gao, K., et al. (2020). Lateral position versus prone position for cervical laminoplasty: a retrospective comparative study. *Therapeutics and Clinical Risk Management*, vol. 16, pp. 133–140.
- [13] Okada, E., Matsumoto, M., Ichihara, D., et al. (2009). Does the sagittal alignment of the cervical spine have an impact on disk degeneration? Minimum 10-year follow-up of asymptomatic volunteers. *European Spine Journal*, vol. 18, no. 11, pp. 1644–1651.
- [14] Nojiri, K., Matsumoto, M., Chiba, K., et al. (2003). Relationship between alignment of upper and lower cervical spine in asymptomatic individuals. *Journal of Neurosurgery*, vol. 99, no. 1, pp. 80–83.

- [15] Yukawa, Y., Kato, F., Suda, K., et al. (2012). Age-related changes in osseous anatomy, alignment, and range of motion of the cervical spine. Part I: radiographic data from over 1,200 asymptomatic subjects. *European Spine Journal*, vol. 21, no. 8, pp. 1492–1498.
- [16] Park, S.-M., Song, K.-S., Park, S.-H., et al. (2014). Does whole-spine lateral radiograph with clavicle positioning reflect the correct cervical sagittal alignment? *European Spine Journal*, vol. 24, no. 1, pp. 57–62.
- [17] Park, M. S., Moon, S. H., Kim, T. H., et al. (2015). Radiographic comparison between cervical spine lateral and whole-spine lateral standing radiographs. *Global Spine Journal*, vol. 6, no. 2, pp. 118–123.
- [18] Marks, M., Stanford, C., and Newton, P. (2009). Which lateral radiographic positioning technique provides the most reliable and functional representation of a patient's sagittal balance? *Spine*, vol. 34, no. 9, pp. 949–954.
- [19] Carver, E. and Carver, B. (2012). *Medical Imaging: Techniques, Reflection & Evaluation* [Internet] (2nd ed.). Elsevier Health Sciences. Retrieved from: https://books.google.lk/books?redir_esc=y&id=j8vohlcgiiAC&q=cervical#v=snippet&q=cervical&f=false (accessed 2020 April 25).
- [20] Ireland, A. J., Britton, I., and Forrester, A. W. (1998). Do supine oblique views provide better imaging of the cervicothoracic junction than swimmer's views? *Emergency Medicine Journal*, vol. 15, no. 3, pp. 151–154.
- [21] Bowe, C. T., Burton, J. H., Chandler, R. C., et al. (2003). The effect of arm traction on the adequacy of cross-table lateral cervical spine radiographs. *Journal of Trauma*, vol. 55, no. 4, pp. 800–801.
- [22] Boger, D. and Ralls, P. W. (1981). New traction device for radiography of the lower cervical spine. *American Journal of Neuroradiology*, vol. 2, no. 5, pp. 467–469.
- [23] Norris, C. S., Silva, W. E., Dodson, T. F., et al. (1986). Shoulder harness traction for roentgenographic assessment of the cervical spine. *Archives of Surgery*, vol. 121, no. 4, pp. 452–455.
- [24] Pate, D. (2012 September 23). Getting a good view of the cervicothoracic junction: swimmer's lateral view. *Dynamic Chiropractic*, vol. 30, no. 20. Retrieved from: <https://www.dynamicchiropractic.com/mpacms/dc/article.php?id=56132> (accessed 2020 April 24).
- [25] Berquist, T. H. (1988). Imaging of adult cervical spine trauma. *Radiographics*, vol. 8, no. 4, pp. 667–694.

- [26] Shrestha, S., Maharhan, S., Khanal, U., et al. (2017). Evaluation of image quality in cervical spine lateral radiographs. *Journal of Chitwan Medical College*, vol. 6, no. 1, pp. 30–33.
- [27] Tins, B. J. (2017). Imaging investigations in spine trauma: the value of commonly used imaging modalities and emerging imaging modalities. *Journal of Clinical Orthopaedics and Trauma*, vol. 8, no. 2, pp. 107–115.