

Case Report

Unexpected Diagnosis of Complete Androgen Insensitivity Syndrome (CAIS) During Inguinal Hernia Repair in 11-year-old-girl

Rayan Khalid^{1,2}, Alaa M. Siddig^{1,3}, Abdelrahman A. Abudoam^{1,4}, Abdel Bagi Alzain^{1,5}, and Imad Fadl-Elmula^{1,2,6}

¹Sudanese Intersex Working Group, Sudan, Khartoum, Sudan

²Department of Clinical Genetics, Assafa College, Khartoum, Sudan

³Department of Pediatric Surgery, Khartoum Teaching Hospital, Khartoum, Sudan

⁴Department of Psychiatry, International University of Africa, Khartoum, Sudan

⁵Department of Obstetrics and Gynecology, Assafa College, Khartoum, Sudan

⁶Department of Surgery, Assafa College, Khartoum, Sudan

ORCID:

Rayan Khalid: <http://orcid.org/0000-0002-2829-9871>

Abstract

Complete Androgen Insensitivity Syndrome (CAIS) is an X-link recessive genetic mutation of androgen receptor (AR) gene leading to complete inability of cell to respond to the androgens. CAIS occurs in 1 out of 20,400 XY live-birth babies, and affects about 1–2% of prepubertal girls that present with an inguinal hernia. Although individuals with CAIS have XY, those with grades 6 and 7 on the Quigley scale are born phenotypically female, without any signs of genital masculinization. Thus, individuals affected by CAIS develop a normal external female phenotype with normal female external genitalia, well-developed breast, absent uterus, and bilateral undescended testicles. The question of CAIS diagnosis does not come forward until the absent menses at the puberty is noted or accidentally during an inguinal hernia repair in a premenarchal girl. The present study reports a case of inguinal hernia repair on 11-year-old girl, which led to unexpected intraoperative notion of CAIS. The diagnostic work-up, genetic counseling, sex assignment, and the need for preoperative CAIS screening in girls with bilateral inguinal hernia are described and discussed.

Keywords: DSD, CAIS, bilateral inguinal hernia, gonadectomy

Corresponding Author:

Rayan Khalid;

Department of Clinical

Genetics, Al Neelain Stem

Cells Center, Al Neelain

University, Khartoum, Sudan

Phone: +249912883686

email: rynkhalid@yahoo.com

Received 26 January 2021

Accepted 7 March 2021

Published 31 March 2021

Production and Hosting by
Knowledge E

© Rayan Khalid et al. This article is distributed under the terms of the [Creative Commons Attribution License](#), which permits

unrestricted use and

redistribution provided that

the original author and

source are credited.

Editor-in-Chief:

Prof. Mohammad A. M. Ibnouf

OPEN ACCESS

1. Introduction

Complete Androgen Insensitivity Syndrome (CAIS) is a rare disorder of sex development (DSD). It is manifested due to mutation in androgen receptor (AR) gene which has been mapped to Xq11-12 [1]. AR gene mutation is maternally inherited in 70% of the cases, whereas the remaining 30% are de novo mutations. The disease is characterized by

feminization of external genitalia and bilateral undescended testes in a 46,XY individual [2].

Although, CAIS is easily diagnosed after puberty, it can be seen accidentally during surgical repair in girls with bilateral inguinal hernia. However, controversy exists about the need to screen premenstrual girls with bilateral inguinal hernia, the best methods of the screening, and the suitable time for gonadectomy.

This report describes unexpected intraoperative findings (testis) during a repair of inguinal hernia in 11-year-old girl, which was later diagnosed as CAIS.

2. Case Presentation

An 11-year-old phenotypical female child presented to Kassala Hospital in Eastern Sudan with bilateral inguinal swellings. Her family history with special probing on her maternal side revealed no previous similar condition. On examination, her height was 128 cm and weight 30 kg. The examination revealed normal female external genitalia and bilateral inguinal swellings, which became prominent on coughing and/or straining. The rest of the physical examination was unremarkable. The diagnosis of bilateral indirect inguinal hernia was made with strong recommendation for surgical repair. During the surgical session, a macroscopic testicular-like structure was found lying inside the Rt. hernial sac. The suspicion of CAIS was evident so the operation was withheld and sutured back without taking tissue biopsy. Later, the patient was referred to the care of Sudanese Intersex Working Group at Elite Clinic, Khartoum, where abdominal/pelvic ultrasound revealed bilateral well-formed testicles (Rt 17 x 7 mm, Lt 16 x 8 mm) located in the mid inguinal canals and no uterine shadow was detected. Hormonal analysis showed normal male testosterone level and chromosomal analysis showed normal male karyotype (46,XY) (Figure 1).

Subsequent PCR for *SRY* gene showed presence of sex-determining region (Figure 2).

The final diagnosis of XY, confirmed DSD (CAIS) and thus patient and parents were referred for genetic, psychological counseling and social support.

The counseling mainly focused on parents since they were anxious, worried, rather clinically depressed, and highly preoccupied about the future of their daughter's gender assignment. They were enlightened about the CAIS and the future hormonal and surgical management. Due to cultural factors, they demanded to preserve the female sex of their daughter and requested urgent gonadectomy. According to the parents will, the young girl's insight about her sex was kept discrete to avoid an unwanted conflict

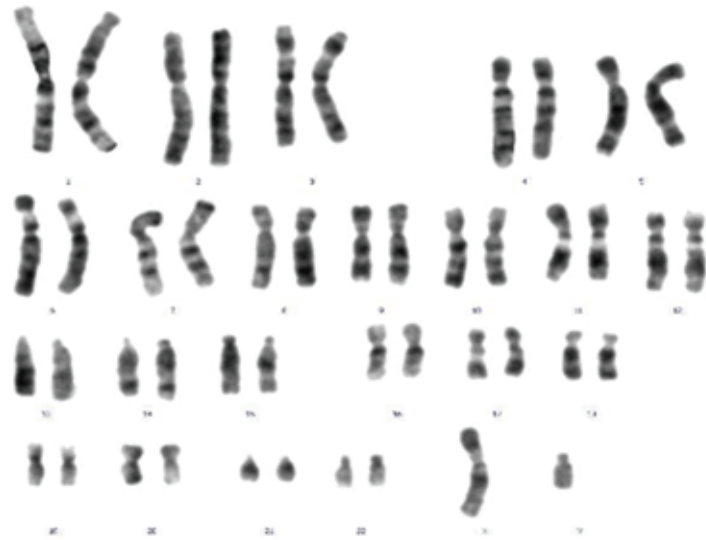


Figure 1: Normal male karyotype 46,XY.

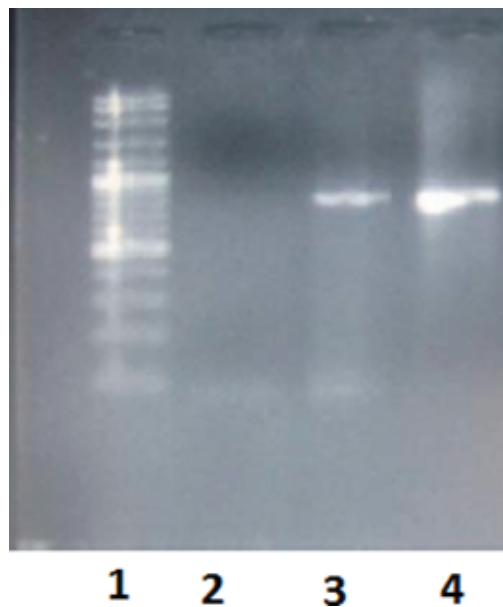


Figure 2: PCR amplification of the *SRY* gene. From left to right: (lane 1) 100 bp ladder; (lane 2) –ve control (fertile female); (lane 3) +ve control (fertile male), (lane 4) patient.

at the age of early adolescence. However, her expected removal of gonads will be explained on the lines of hernial repair. She should be taken in confidence when she is over 18 years old with the help of her parents and a religious leader. Professional news breaking should be exercised to her and further to whoever would marry her that she will not bear children.

3. Discussion

The aforementioned case represents the dramatic scenario of intraoperative finding (testicular-like structure in a hernial sac) in a girl with CAIS. The unexpected findings are weird for the operating surgeon and traumatizing for the parents and their 11-year-old girl let alone the surprise of the limited experience of the surgeon to provide proper counseling and management of such cases.

It has been suggested that all premenstrual girls with inguinal hernias should undergo chromosomal study to rule out the possibility of an early diagnosis of CAIS [3]. This idea originates from the increased prevalence (0.8–2.4%) of CAIS in phenotypic females presenting with inguinal hernias [4]. Contrastingly, other authors argue that the 2.4% prevalence does not justify chromosomal screening since the vast majority (>97%) of phenotypic female cases presenting with inguinal hernia are less likely to have CAIS. Moreover, in areas with limited health resources such as Africa, screening methods such as sonography and/or chromosomal analysis are not available or otherwise are very costly. In fact, the reported incidence of CAIS has not been convincing enough to support the routine use of such investigations even if they are available [5]. This view is supported by Hurme *et al.*'s study in which they diagnosed CAIS in only one case following karyotype analyses of 109 premenstrual females who had undergone inguinal hernia repair [6]. In fact, most authors agree on the unnecessary for chromosome analysis in girls with inguinal hernia and instead consider ultrasonography capable of revealing the uterus and/or the ovaries in most cases [7].

Considering Sudanese culture on sex assignment and orientation in rural community, parents easily accepted the decision not to reassign an opposite sex to the patient. This was evident in the unusual management in this reported case, where both parents were adamantly demanding early gonadectomy. The fear of social stigma may justify the concern of the parents stressing the surgeon to comply and perform early gonadectomy.

According to the statistics, most of the patients with CAIS present late with primary amenorrhea leading to delayed diagnosis, in some cases, post marriage. In fact, early diagnosis may help appropriate scheduling of gonadectomy as well as systematic parental counseling regarding several long-term issues of hormone-replacement therapy and fertility [8, 9]. Early diagnosis of CAIS is equally essential for better management of psychosocial comorbidities and genetic counseling including carrier detection and pre-implantation genetic test with 100% chance for carrier females to bear healthy children; putting end to the transmission of the mutated X chromosome to the coming generations.

Ethical considerations

The study protocol was approved by the institutional ethical committee of Assafa College. Data were collected anonymously, and verbal consent were obtained from both parents.

Competing interests

The authors hereby declare that they have no competing interest.

Availability of data and material

All the data included in the present study is available and can be provided upon request.

Funding

The study was self-funded by the authors as part of ongoing project of the Sudanese intersex working group

Authors' contributions

Data presented in the case report is original data of the authors and has not been published previously. The manuscript has been reviewed and approved by all authors. All authors equally contributed to this paper.

References

- [1] Lubahn, D. B., Joseph, D. R., Sullivan, P. M., et al. (1988). Cloning of human androgen receptor complementary DNA and localization to the X chromosome. *Science*, vol. 240, no. 4850, pp. 327–330.
- [2] Sharma, S., Balwan, W. K., Kumar, P., et al. (2012). Androgen insensitivity syndrome (testicular feminization). *Journal of Obstetrics and Gynecology of India*, vol. 62, no. 2, pp. 199–201.
- [3] Konar, S., Dasgupta, D., Patra, D. K., et al. (2015). Chromosomal study is must for prepubertal girl with inguinal hernia: opportunity to diagnose complete androgen

insensitivity syndrome. *Journal of Clinical and Diagnostic Research*, vol. 9, no. 4, p. GD01.

- [4] Oakes, M. B., Eyvazzadeh, A. D., Quint, E., et al. (2008). Complete androgen insensitivity syndrome—a review. *Journal of Pediatric and Adolescent Gynecology*, vol. 21, no. 6, pp. 305–310.
- [5] Sarpel, U., Palmer, S. K., and Dolgin, S. E. (2005). The incidence of complete androgen insensitivity in girls with inguinal hernias and assessment of screening by vaginal length measurement. *Journal of Pediatric Surgery*, vol. 40, no. 1, pp. 133–137.
- [6] Hurme, T., Lahdes-Vasama, T., Mäkelä, E., et al. (2009). Clinical findings in prepubertal girls with inguinal hernia with special reference to the diagnosis of androgen insensitivity syndrome. *Scandinavian Journal of Urology and Nephrology*, vol. 43, no. 1, pp. 42–46.
- [7] Okada, T., Sasaki, S., Honda, S., et al. (2012). Irreducible indirect inguinal hernia containing uterus, ovaries, and Fallopian tubes. *Hernia*, vol. 16, no. 4, pp. 471–473.
- [8] Dejager, S., Bry-Gauillard, H., Bruckert, E., et al. (2002). A comprehensive endocrine description of Kennedy's disease revealing androgen insensitivity linked to CAG repeat length. *Journal of Clinical Endocrinology and Metabolism*, vol. 87, no. 8, pp. 3893–3901.
- [9] Aschim, E. L., Nordenskjöld, A., Giwercman, A., et al. (2004). Linkage between cryptorchidism, hypospadias, and GGN repeat length in the androgen receptor gene. *Journal of Clinical Endocrinology and Metabolism*, vol. 89, no. 10, pp. 5105–5109.