

Research Article

Profile of Abdominal Surgical Complications of Enteric Fever in Children in a Developing Country

Kevin Emeka Chukwubuiké

Pediatric Surgery Unit, Department of Surgery, Enugu State University Teaching Hospital, Enugu, Nigeria

Abstract

Background: Surgical complications of enteric fever has been associated with significant morbidity and mortality. The aim of this study was to determine the pattern and outcome of the treatment of abdominal surgical complications of enteric fever in children in a teaching hospital in Enugu, Nigeria.

Methods: This retrospective study included children who had undergone a surgery for abdominal complications of enteric fever at the pediatric surgery unit of Enugu State University Teaching Hospital (ESUTH), Enugu, Nigeria. The medical records of the pediatric patients over a five-year period were evaluated for the patients' demographics, presenting symptoms, investigations, intraoperative findings, procedures performed, and postoperative complications and outcome.

Results: During the study period, there were 44 cases of abdominal surgical complications of enteric fever with an age range of 6–14 years (mean 9.5 years) and the male to female ratio of 2.7:1. The mean duration of symptoms prior to presentation was five days. All the patients had fever and abdominal pain. While 95% of the patient had typhoid intestinal perforation, 5% had typhoid hemorrhage. Primary closure of intestinal perforation and right hemicolectomy with ileotransverse anastomosis were performed for typhoid intestinal perforation and typhoid intestinal hemorrhage, respectively. Surgical site infection was the most common postoperative complication. The mortality rate was 6.8%.

Conclusion: Abdominal surgical complications of enteric fever are still obtainable in developing countries. Typhoid intestinal perforation was the most common complication recorded in the present study.

Corresponding Author:
Kevin Emeka Chukwubuiké;
Department of Surgery,
Enugu State University
Teaching Hospital, Enugu,
Nigeria.
email: chukwubuikéon-
line@yahoo.com

Received 11 August 2020
Accepted 15 September
2020
Published
30 September 2020

Production and Hosting by
Knowledge E

© Kevin Emeka
Chukwubuiké. This article is
distributed under the terms of
the [Creative Commons
Attribution License](#), which
permits unrestricted use and
redistribution provided that
the original author and
source are credited.

Editor-in-Chief:
Prof. Mohammad A. M. Ibnouf

Keywords: abdominal, children, enteric fever, surgical complications

1. Introduction

Enteric fever, also known as typhoid fever, is a common multisystem infection caused by the bacteria *Salmonella enterica serovar typhi* and *Salmonella enterica serovar paratyphi A and B* which are transmitted through feco-oral route [1]. It is a public health problem particularly in low-income countries due to poor sanitation, lack of potable

 OPEN ACCESS

water, and improper waste disposal [2]. Generally, complications of enteric fever of surgical importance could be associated with significant morbidity and mortality. These complications include typhoid intestinal perforation, intestinal bleeding, gall bladder diseases, and osteomyelitis. Other complications, though rare, include pancreatitis, pleural effusion, orchitis, hepatic, and splenic abscesses. Among all the complications, typhoid intestinal bleeding is the most common. However, several authors have reported typhoid intestinal perforation as the most dreaded and feared complication [3–6]. This study focuses on the surgical complications of typhoid fever that occur in the abdomen. The objective of this study was to determine the pattern and outcome of the treatment of abdominal surgical complications of enteric fever in children in a teaching hospital in Enugu, Nigeria.

2. Materials and Methods

This retrospective study included children aged 15 years and below who had undergone a treatment for abdominal complications of typhoid fever between January 2014 and December 2018 at the pediatric surgery unit of the Enugu State University Teaching Hospital (ESUTH) Enugu, Nigeria. ESUTH serves the whole of the Enugu State, which according to the 2016 estimates of the National Population Commission and Nigerian National Bureau of Statistics has a population of about 4 million people and a population density of 616.0/km². The hospital also receives referrals from its neighboring states. Ethical approval was obtained from the ethics and research committee of the hospital. Informed consent was obtained from the patients' caregivers. However, patients who have had surgery for typhoid complication and those who are above the age of 15 years were excluded from this study. In addition, patients with incomplete case records were also excluded.

2.1. Preoperative protocol

All the consecutive children who presented during the study period were recruited into the study. The diagnosis of typhoid complication was made based on clinical features, investigations, intraoperative findings and histological examination. Investigations such as ultrasound and X-rays were performed depending on the clinical presentation of the patients. All patients had taken Widal tests which were strongly positive. On presentation at the hospital, all patients were resuscitated using intravenous fluids and placed on intravenous ceftriaxone.

2.2. Intraoperative protocol

The intraoperative procedure depended on the type of typhoid complication. For instance, in typhoid intestinal perforation following adequate resuscitation, laparotomy was performed through a transverse infraumbilical incision under general anesthesia with endotracheal intubation. The bowel perforation was identified and the surgeon closed the perforation in two layers. The peritoneal cavity was mopped dry and abdomen closed in layers. In recalcitrant typhoid hemorrhage that has failed to stop following nonoperative treatment, right hemicolectomy with ileotransverse anastomosis was performed.

2.3. Postoperative protocol and follow-up

Postoperatively, graded oral intake was commenced when bowel function returned. The surgical site was examined on the fourth day and the patient discharged on the fifth day if there are no problems. The follow-up period was for 12 months.

2.4. Data collection

The following data were collected: age and gender of the patient, duration of symptoms before presentation, time interval between presentation and surgery, type of typhoid complication, complications of treatment, duration of hospital stay, and the outcome of the treatment.

2.5. Data Analysis

Data were analyzed using the Statistical Package for Social Science (SPSS) version 23 (manufactured by IBM Cooperation, Chicago Illinois) were expressed as percentages, means, and standard deviation.

3. Results

3.1. Patients' demographics

In total, 47 cases of abdominal surgical complications of typhoid fever were treated during the five-year study period. However, only 44 of them had complete case records

and thereby formed the basis of this report. There were 32 (72.7%) male and 12 (27.3%) female participants, which corresponded to a male-to-female ratio of 2.7:1. Details are depicted in Table 1.

3.2. Clinical presentation

The patients presented with a constellation of symptoms that included abdominal pain, bleeding per rectum, fever, abdominal swelling, diarrhea, vomiting, and constipation in various combinations. All patients had fever and abdominal pain. The frequency of the symptoms is shown in Table 2.

3.3. Investigations performed

All patients had undergone an abdominopelvic ultrasound and the presence of echo-rich peritoneal fluid was negative in 10 (22.7%) patients. Plain X-ray showed air under the diaphragm in 25 (56.8%) patients, while air-fluid level was seen in 35 (79.5%) patients.

3.4. Intraoperative finding

A single ileal perforation was observed in 35 (79.5%) patients. Nine (20.5%) patients had more than one perforation. All perforations occurred within a proximity of 30 cm to the ileocaecal valve. The perforations were round or ovoid in shape, each measuring about 1.5 cm and located at the anti-mesenteric border of the ileum. There was no colonic perforation. Additionally, no intestinal perforation was observed in two (4.5%) patients who had bleeding per rectum.

3.5. Definitive diagnosis and procedure performed

While 42 (95.5%) patients had typhoid intestinal perforation, two (4.5%) patients had typhoid intestinal hemorrhage. No typhoid gall bladder disease was recorded during the study period. The typhoid perforations were closed primarily after excising the edges and tissue specimen sent for histology. For patients with typhoid hemorrhage, a right hemicolectomy was performed, which excises the Peyer's patches from the terminal ileum, and specimen sent for histology. The specimen sent for histology showed cryptic changes with evidence of acute and chronic inflammation on the Peyer's patches. This histopathological finding is consistent with typhoid intestinal pathology.

3.6. Postoperative complications

Postoperative complication is shown in Figure 1.

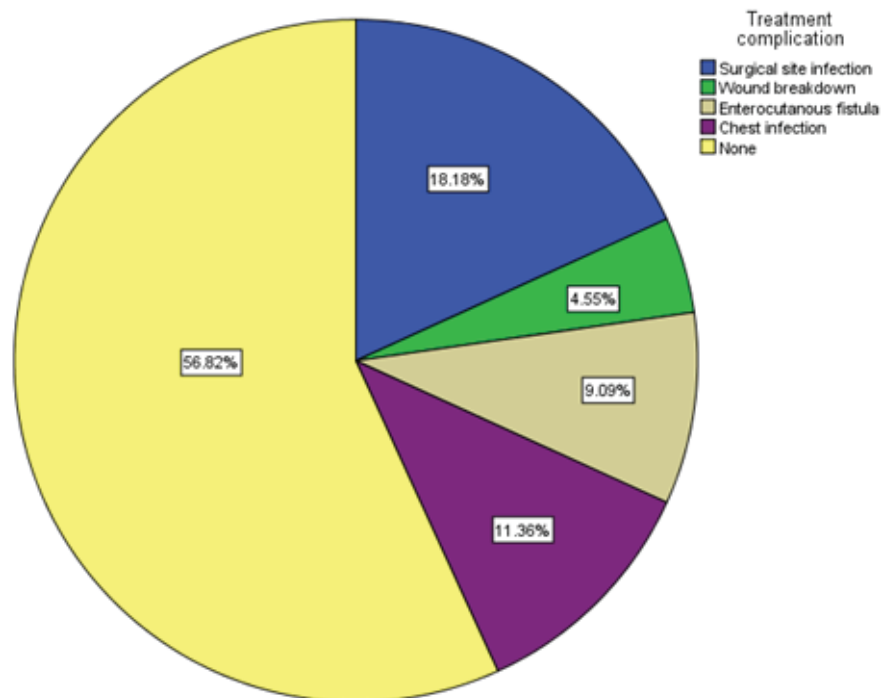


Figure 1: Post-operative complications.

3.7. Outcome

Thirty nine (88.6%) patients did well and were discharged home. Two (4.5%) patients signed out, in the postoperative period, against medical advice. Mortality was recorded in three (6.8%) patients.

4. Discussion

Salmonella typhi is a gram-negative, motile, aerobic, non-spore-forming intracellular bacillus that causes the systemic infection, typhoid fever [7]. Despite awareness that has been created, typhoid fever is still hovering around in developing countries. Surgical complications of typhoid fever have been documented to occur in 10–15% of typhoid fever patients, and these complications are more likely to occur if the typhoid fever has lasted for more than two weeks [8].

TABLE 1: Patients' demography.

Variables	Values
Gender	
Male	32 (72.7%)
Female	12 (27.3%)
Mean age of the patients	9.5 years (6–14)
Mean duration of symptoms prior to presentation	5 days (2–8)
Presented within 24 hr	4 (9.1%)
Presented between 24 and 72 hr	8 (18.2%)
Presented after 72 hr	32 (72.7%)
Mean duration from presentation to surgery	2 days (1–5)
Mean duration of hospital stay	12.9 days (7–21)

TABLE 2: Symptomatology of the patients.

Symptoms	Number of patients	Percentage (%)
Abdominal pain	44	100
Fever	44	100
Abdominal distension	30	68.2
Vomiting	25	56.8
Constipation	13	29.5
Diarrhea	11	25.0
Bleeding per rectum	2	4.5

Moreover, this study found that the male patients were more affected than the female; which is consistent with other series on typhoid complications [9, 10]. However, there are also few reports of female predominance [11, 12]. The reason for this difference in sex is unclear. There is a postulation of hormonal factors as being responsible [13]. The mean ages of the patients who have complications of typhoid fever vary from one study to another [9, 10, 14]. Typhoid fever complications rarely occur in children under the age of five years. Ekenze *et al.* reported typhoid complication in children less than five years of age [5]. However, the World Health Organization recommends the administration of the live attenuated oral typhoid vaccine to persons above five years of age [15]. Moreover, typhoid complications in children less than five years of age present in unusual manner [5]. Majority of our patients presented after 72 hr of the onset of their symptoms. Poverty and ignorance that is common in low-income countries may explain the late arrival in hospital.

The clinical presentation of the patients depends on the type of typhoid complication. For patients who had intestinal perforation, fever and abdominal pain were reported in most patients. The finding is in alignment with reports of other researchers [16, 17]. For typhoid intestinal hemorrhage, a consistent finding was gastrointestinal bleeding

which could be mild or massive. In very minimal bleeding, typhoid intestinal hemorrhage may manifest as altered blood in stool [18]. Colonoscopy is the gold standard for the evaluation of lower intestinal bleeding [19]. However, none of the studied patients had colonoscopy due to absence of the facility. Typhoid was suggested as the cause of the intestinal bleeding by the patients' clinical features and confirmed by histopathological examination of the resected specimen.

Ultrasound is non-invasive, available, affordable, and fairly sensitive test in the assessment of abdominal problems. Abdominal ultrasound for typhoid perforation may show free peritoneal fluid due to leakage of intestinal contents. A significant number of our patients had free peritoneal fluid. This finding has also been reported by other series on typhoid intestinal perforation [20, 21]. The ability to detect leakage of intestinal content may depend on the quantity of peritoneal fluid and experience of the radiologist. About half of the studied patients had pneumoperitoneum. Pneumoperitoneum was also documented by Ugochukwu *et al.* and Chalya *et al.* [20, 21]. In typhoid intestinal hemorrhage, nothing may be found on abdominal ultrasound because the bleeding is intraluminal. However, non-specific features of enteric fever such as hepatomegaly, splenomegaly, ileal and cecal thickening may be noticed during ultrasound [22].

One perforation on the ileum was the predominant finding in typhoid perforation patients. This is in line with the findings of other workers [12, 20]. The severity of symptoms does not depend on the number of intestinal perforations [23]. Colonic involvement in typhoid fever has been documented [24]. For the two patients who had bleeding per rectum, there was no intestinal perforation. Typhoid intestinal bleeding results from erosion of a necrotic Peyer's patch through the wall of an enteric vessel [8]. In most cases, the hemorrhage is mild and stops spontaneously. However, the bleeding can be fatal if a large vessel is involved [8]. In the index study, there were far more typhoid intestinal perforation than typhoid intestinal bleeding. This is consistent with the reports of other studies [9, 25]. However, other researchers reported typhoid intestinal bleeding as the most common [8, 24]. The reason for the differences in the report is not known but might be explained by the fact that most bleeding are mild and only present as melana stool. Vagholkar *et al.* reported that patients give a history of melena preceding onset of abdominal pain in typhoid perforation [26]. Treatment of abdominal surgical complication depends on the type of complication. In the present study, typhoid perforation was treated by simple primary closure in two layers. Other modalities of treatment include segmental bowel resection or creation of ileostomy. The choice of option may be based on the available facilities and the degree of the peritoneal contamination. In typhoid hemorrhage, a right hemicolectomy excises most

of the terminal ileum where the Peyer's patches are located. This was the modality of treatment offered to the studied patients. In developed countries where all the facilities are available, endotherapy and angiographic coil embolization of the bleeding vessel are the current modalities of the treatment [27]. Surgical site infection was the most common complication in the index study. This finding is supported by the report of Uba *et al.* [10]. Abdominal wounds following laparotomy for typhoid complications is considered as dirty wound with an infection rate of over 40% [17]. Mortality following the treatment of typhoid complication may be multifactorial. In developing countries like Nigeria, delayed presentation is a significant factor that affects mortality.

Limitations of this study

This study was limited by the small number of cases. A larger number of cases would have availed better analysis.

Culture and isolation of the organism, *Salmonella*, was not possible due to the retrospective nature of the study.

5. Conclusion

Abdominal surgical complications of enteric fever are still obtainable in developing countries. In this study, typhoid intestinal perforation was more common than typhoid hemorrhage. The outcome of the treatment can be improved by early presentation. There is a need for increased awareness both among the public and the clinicians.

Declarations

Acknowledgements

None

Ethical Considerations

This study was approved by the ethics and research committee of the hospital.

Competing Interests

None

Availability of Data

Data is available with the corresponding author and can be provided on reasonable request.

Funding

None

Authors' Contributions

The author was solely involved in the study concept, design, data acquisition, analysis, etc. The author bears the responsibility for the accuracy and integrity of all aspects of this work.

References

- [1] Archampong, E. Q., Tandoh, J. F., Nwako, F. A., et al. (1994). Surgical problems of enteric fever. In: E. A. Badoe, E. Q. Archampong, M. O. Jaja, (eds.), *Principles and Practice of Surgery including Pathology in the Tropics* (2nd ed.). Ghana: Ghana publishing corporation, pp. 602–604.
- [2] Ochiai, R. L., Acosta, C. J., Danovaro-Holliday, M. C., et al. (2008). A study of typhoid fever in five Asian countries: disease burden and implications for controls. *Bulletin of the World Health Organization*, vol. 86, pp. 260–268.
- [3] Atamanalp, S. S., Aydinli, B., Ozturk, G., et al. (2007). Typhoid intestinal perforations: twenty-six year experience. *World Journal of Surgery*, vol. 31, pp. 1883–1888.
- [4] Santillana, M. (1991). Surgical complications of typhoid fever: Enteric perforation. *World Journal of Surgery*, vol. 15, pp. 170–175.
- [5] Pujar, K. A., Ashok, A. C., Rudresh, H. K., et al. (2013). Mortality in typhoid intestinal perforation – a declining trend. *Journal of Clinical and Diagnostic Research*, vol. 7, no. 9, pp. 1946–1948.

- [6] Butler, T., Joseph, K., Samir, K. N., et al. (1985). Typhoid fever complicated by intestinal perforation: a persisting fatal disease requiring surgical management. *Review of Infectious Diseases*, vol. 7, no. 2, pp. 244–256.
- [7] Lucas, A. O. and Gilles, H. M. (2003). Communicable diseases: infections through the gastrointestinal tract. In: A. O. Lucas, H. M. Gilles, (eds.), *Short Textbook of Public Health Medicine for the Tropics (4th rev. ed.)*. London: Arnold Publishers, p. 59.
- [8] Ezzat, R. F., Hussein, H. A., Baban, T. S., et al. (2010). Typhoid ulcer causing life-threatening bleeding from Dieulafoy's lesion of the ileum in a seven-year-old child: a case report. *Journal of Medical Case Reports*, vol. 4, p. 171. DOI: 10.1186/1752-1947-4-171.
- [9] Akinwale, M. O., Sanusi, A. A., Adebayo, O. K. (2016). Typhoid perforation. Post-operative intensive care unit care and outcome. *African Journal of Paediatric Surgery*, vol. 13, pp. 175–180.
- [10] Sumer, A., Kemik, O., and Dulger, A. C. (2010). Outcome of surgical treatment of intestinal perforation in typhoid perforation. *World Journal of Gastroenterology*, vol. 16, no. 33, pp. 4164–4168.
- [11] Olori, S. and Ukpoju, E. (2019). Typhoid ileal perforation in children: does clinical diagnosis alone justify laparotomy? *South Sudan Medical Journal*, vol. 12, pp. 9–11.
- [12] Edino, S. T., Yakubu, A. A., Mohammed, A. Z., et al. (2007). Prognostic factors in typhoid ileal perforation, a prospective study of 53 cases. *Journal of the National Medical Association*, vol. 99, pp. 1042–1045.
- [13] Khan, M. (2012). A plausible explanation for male dominance in typhoid ileal perforation. *Clinical and Experimental Gastroenterology*, vol. 5, pp. 213–217. DOI: 10.2147/CEG.S36569.
- [14] Sheshe, A. A., Anyanwu, L. J. C., Mohammed, A. M., et al. (2018). Typhoid intestinal perforation: analysis of the outcome of surgical treatment in Kano, Nigeria. *Archives of Medical Science*, vol. 6, pp. 59–63.
- [15] Milligan, R., Paul, M., Richardson, M., et al. (2018). Vaccines for preventing typhoid fever. *Cochrane Database Systematic Reviews*, vol. 5, no. 5, CD001261. DOI: 10.1002/14651858.CD001261.pub4.
- [16] Ekenze, S. O., Okoro, P. E., Amah, C. C., et al. (2008). Typhoid ileal perforation: analysis of morbidity and mortality in 89 children. *Nigerian Journal of Clinical Practice*, vol. 11, pp. 58–62.
- [17] Usang, E. U., Inyang, A. W., Nwachukwu, I. E., et al. (2017). Typhoid perforation in children: an unrelenting plague in developing countries. *Journal of Infection in Developing Countries*, vol. 11, pp. 747–752. DOI: 10.3855/jidc.9304.

- [18] Jemni, L., Mehdi, A., Chakroun, M., et al. (1989). Complications of typhoid fever. *Medecine Tropicale*, vol. 49, pp. 189–191.
- [19] Lee, J. H., Kim, J. J., Jung, J. H., et al. (2004). Colonoscopic manifestations of typhoid fever with lower gastrointestinal bleeding. *Digestive and Liver Disease*, vol. 36, no. 2, pp. 141–146.
- [20] Chalya, P. L., Mabula, J. B., Koy, M., et al. (2012). Typhoid intestinal perforations at a University teaching hospital in Northwestern Tanzania: a surgical experience of 104 cases in a resource-limited setting. *World Journal of Emergency Surgery*, vol. 7, no. 4. DOI: 10.1186/1749-7922-7-4.
- [21] Ugochukwu, A. I., Amu, O. C., and Nzegwu, M. A. (2013). Ileal perforation due to typhoid fever-Review of operative management and outcome in an urban centre in Nigeria. *International Journal of Surgery*, vol. 11, pp. 218–222. DOI: 10.1016/j.ijss.2013.01.014.
- [22] Mateen, M. A., Saleem, S., Rao, P. C., et al. (2006). Ultrasound in the diagnosis of typhoid fever. *Indian Journal of Pediatrics*, vol. 73, no. 8, pp. 681–685. DOI: 10.1007/bf02898444.
- [23] Contini, S. (2017). Typhoid intestinal perforation in developing countries: still unavoidable deaths? *World Journal of Gastroenterology*, vol. 23, pp. 1925–1931. DOI: 10.3748/wjg.v23.i11.1925.
- [24] Sharma, A. K., Sharma, R. K., Sharma, S. K., et al. (2013). Typhoid intestinal perforation: 24 perforations in one patient. *Annals of Medical and Health Science Research*, vol. 3, no. 1, pp. S41–S43. DOI: 10.4103/2141-9248.121220.
- [25] Chaudhary, P., Kumar, R., Munjewar, C., et al. (2015). Typhoid ileal perforation: a 13-year experience. *Healthcare in Low-resource Settings*, vol. 3, p. 4677. DOI: 10.4081/hls.2015.4677.
- [26] Vagholkar, K., Mirani, J., Jain, U., et al. (2015). Abdominal complications of typhoid fever. *Journal of Surgery*, vol. 10, no. 4, pp. 227–338. DOI: 10.7438/1584-9341-10-4-9.
- [27] Goel, A. and Bansal, R. (2017). Massive lower gastrointestinal bleed caused by typhoid ulcer: conservative management. *Euroasian Journal of Hepato-Gastroenterology*, vol. 7, no. 2, pp. 176–177. DOI: 10.5005/jp-journals-10018-1242.