

Vaginal Misoprostol for Cervical Priming before Operative Hysteroscopy in Misurata Hospital, Libya

Aisha M. Elbareg¹, Mohamed El Sirkasi², Fathi M. Essadi¹
Mohamed O. Elmahashi¹, Ishag Adam^{3*}

ABSTRACT

Background: Operative hysteroscopy has gained popularity as a minimally invasive approach in the management of intrauterine abnormalities. Cervical dilatation represents a real challenge during the procedure. Misoprostol, a synthetic prostaglandin E1 analogue has a cervical ripening effect in both pregnant and non-pregnant patients.

Objectives: To investigate vaginal misoprostol in facilitating cervical dilatation prior to operative hysteroscopy.

Material and Methods: This was an open controlled clinical trial conducted at Misurata, Libya. Patients were randomized into two groups of (60 each): misoprostol group received 400 µg misoprostol (cytotec), self-administered vaginally 3-4 hrs prior to the operation (hysteroscopy) and control group received no treatment.

Results: The two groups were well matched in their age, parity, presentations and indications of the procedure. Compared with the controls, significantly more cervical dilatation was achieved in significantly shorter time in misoprostol group. Likewise the duration of the operative hysteroscopy was also significantly shorter in the misoprostol group. Significantly fewer patients in misoprostol group had cervical lacerations, creation of false passage during cervical dilatation and uterine perforations.

Conclusion: In summary, the study showed that vaginal misoprostol administered 3-4 hour before operative hysteroscopy reduce the need for cervical dilatation and facilitate hysteroscopic surgery.

Keywords: Misoprostol, cervical priming, hysteroscopy, Libya.

Operative hysteroscopy is popular minimally invasive approach in the management of intrauterine lesions such as endometrial polyps; submucous fibroid, intrauterine adhesions, and uterine septum¹. Insertion of hysteroscopic resectoscope usually requires a dilatation of the cervix. Achieving this degree of dilatation in the non-gravid cervix is difficult and might be impossible without

prior cervical ripening. Therefore complications (cervical tear, creation of false passage, and uterine perforation) might encounter during the procedure of the insertion of the hysteroscopy or to the dilatation of the cervical canal²⁻⁴. Furthermore, some hysteroscopic operations such as myomectomy need longer duration for adequate cervical dilatation to facilitate repeated insertions and withdrawals of the resectoscope to allow complete extraction of the excised lesions. Thus an efficient method to facilitate an easier uncomplicated entry through ripened cervix during hysteroscopic procedure could substantially minimize the risk of complications. Application of

1. Misurata Central Hospital, Misurata University, Misurata, Libya

2. Faculty of Medical Technology, Misurata University, Misurata, Libya

3. Faculty of Medicine, University of Khartoum, Khartoum, Sudan.

* Correspondence to: Ishag Adam
E-mail: ishagadam@hotmail.com

intracervical sulprostone gel before diagnostic hysteroscopy yield a significant reduction in the force required to dilate the cervix⁵. Likewise, the vaginal use of metenoprost potassium before outpatient hysteroscopy in infertile patients provided sufficient dilatation of the cervical canal to permit the insertion of a hysteroscope without additional mechanical dilatation⁶. Preoperative cervical ripening may be achieved other method e.g. osmotic dilator (Laminaria) and misoprostol⁷⁻¹². Misoprostol, a synthetic prostaglandin E1 analogue was found to be successfully ripen the cervix either when give for medical abortion during first or second trimester¹³, or when used for labor induction¹⁴. Consequently, given its high efficacy in dilating the cervix also facilitate dilatation in women undergoing hysteroscopy⁵⁻¹⁷. The total systemic bioavailability of vaginally administered misoprostol was three times greater than that of orally administered misoprostol¹⁸, and might explain why vaginal misoprostol is more effective than oral misoprostol when used medical abortion and before hysteroscopy^{15, 19}. Yet, other studies showed that all routes, oral, sublingual administration, vaginal, intracervical before hysteroscopy were equally effective in ripening the cervix^{9,17, 20}.

In addition, the primary advantages of misoprostol were cheaper price, can be kept at room temperature, greater acceptability by doctors and patients²¹. There are few published data on the use of misoprostol in ripening the cervix before hysteroscopy and most of these are from developed world. The current study was conducted to investigate the use of vaginal misoprostol before operative hysteroscopy.

MATERIALS AND METHODS:

An opened controlled clinical trial was carried out during the period of October 2012 to September 2013 at the

Gynecology Department of Misurata Hospital. It was approved by the Medical Ethics Committee of the Hospital. After signing an informed consent, symptomatic patients and suspected to have intrauterine pathology, such as a submucous myoma, endometrial polyps or other endometrial pathological findings based on the transvaginal ultrasound, were enrolled. The study comprised women with different indications for operative hysteroscopy. The obstetric history was gathered using questionnaires and pelvic examinations with transvaginal ultrasonography was performed to determine the nature, site and extent of intrauterine lesions. Those with genital infection, history of cervical surgery, endometrial lesions with suspected endo- or ecto-cervical lesions that could affect the cervical resistance, or patients that were not candidates for surgery were excluded. Patients were randomized into two groups using computer generated numbers and sealed envelopes. The misoprostol group received 400 µg misoprostol (self-administered) vaginally 3-4 hours before operative hysteroscopy and the control group who received no treatment before hysteroscopy.

All the hysteroscopic surgeries were performed in the early proliferative phase of the menstrual cycle with a Carl Storz 9-mm hysteroscope under general anaesthesia. In the operating room, the degree of initial cervical dilatation was assessed by introducing Hegar dilators under general anesthesia. It was defined as the maximal caliber dilator that passed without resistance in ascending manner starting with Hegar

size 4. The primary outcome measure was number of patients achieving a pre-operative cervical dilatation of 7mm. The secondary outcome measures included the subjective ease of cervical dilatation; the time required for dilatation up to Hegar 10,

time required to complete the procedure and complication of the procedure.

RESULTS:

One hundred and twenty (60 patients in each arm) patients were enrolled to the study. The mean (SD) of the age [32.5(6.7) vs. 30.7(8.3) year, $P = 0.102$] and the number (%) of the nulliparae [38(63.3) vs. 32(53.3), $P = 0.267$] was not different between the two groups. There was no significant difference in the indications (infertility was the main indications), types of the operative hysteroscopic procedure (endometrial polypectomy and submucous myomectomy were the commonest) between the two groups, figure 1, 2.

Compared with the controls, significantly more cervical dilatation was achieved in significantly shorter time in misoprostol group [42.30 (20.5) vs. 110.20 (25.3) sec, $P < 0.001$]. Consequently, the duration of the operative hysteroscopy was also significantly shorter in the misoprostol group (table 1). Likewise, significantly more patients [49(81.6%) vs 10(16.6%)] in misoprostol group the size 7 Hegar dilator was passed without use of force (table 1). In comparison with the controls; significantly fewer patients in misoprostol group had cervical lacerations [1 (1.6%) vs. 8 (13.3%), $P < 0.001$], creation of false passage during cervical dilatation [1 Table (1): the Outcome measures of the study

(1.6%) vs. 4(6.6%), $P < 0.001$]. Four of the 8 patients with cervical tear in the control group, required suturing. There were two (3.3%) uterine perforations in the control group. One occurred during cervical dilatation and one occurred during lysis of intrauterine adhesions (table 1).

DISCUSSION:

The main findings of the current study were; more cervical dilatation was achieved in significantly shorter time, operation time was shorter and the dilator was passed without force in misoprostol group. This is goes with the previous studies that have shown that misoprostol administered vaginally was effective when compared with placebo for cervical ripening before diagnostic hysteroscopy and it reduced the pain score and facilitated easy entry of the hysteroscopy^{22,23}. likewise it has been observed that even in operative hysteroscopy the use of misoprostol is beneficial^{6,20,24,25}. Recently Gkrozou et al., in their met-analyses confirmed that vaginal misoprostol significantly reduced the need for cervical dilatation and even in the operative hysteroscopy the need for dilatation and the duration of the operation were also significantly reduced²⁶. Previous studies compared the vaginal misoprostol with placebo before operative hysteroscopy found that misoprostol

The variable	Misoprostol group	Control group	P
<i>The mean (SD) of the</i>			
Cervical dilatation, mm	7.2 (0.5)	3.7 (1.5)	< 0.001
Time for cervical dilatation to Hegar 10, sec	42.30 (20.5)	110.20 (25.3)	< 0.001
Duration of operative hysteroscopy, min	37.2(10.2)	50.9 (14.6)	< 0.001
<i>Number (%) of</i>			
Cervical dilatation to 7mm	49 (81.6)	10 (16.6)	< 0.001
Cervical tear	1 (1.6)	8 (13.3)	0.015
Creation of a false passage	1 (1.6)	4 (6.6)	0.213
Uterine perforation	0 (0)	2 (3.3)	0.467

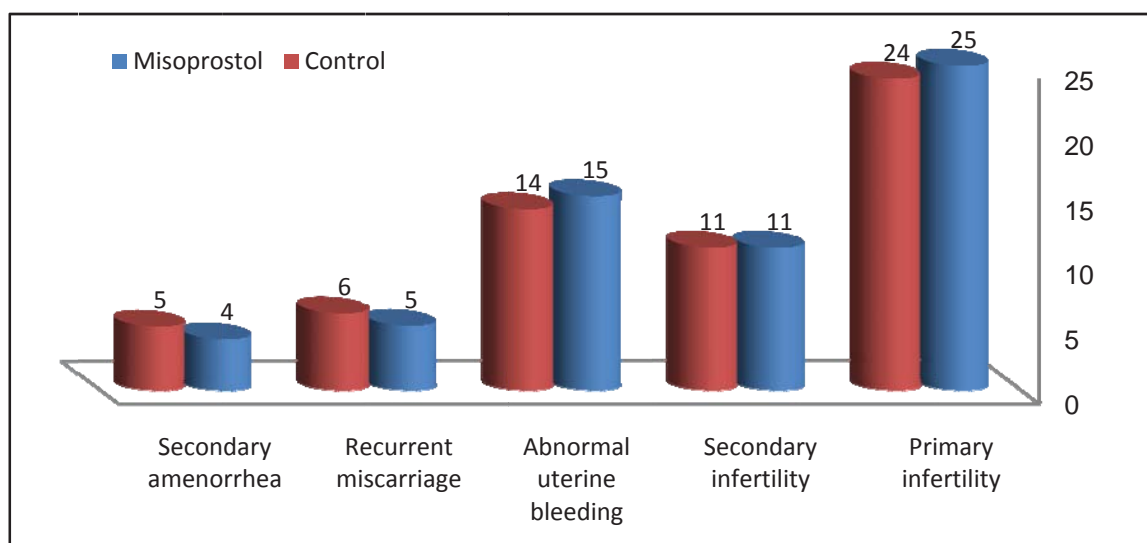


Figure 1: The indications of hysteroscopy among women in Misurata Hospital, Libya

reduced the need for cervical dilation, facilitated the procedure and minimized cervical complications of the procedure^{27, 28}.

In the current study the complications of the procedure such as cervical lacerations, creation of false passage during cervical dilatation and uterine perforations were observed in fewer patients in the misoprostol compared with the control group. This is goes with the previous

study²⁸. It is worth to be mentioned that these complications would have been avoided by the proper ripening of the cervix as it was in the misoprostol group.

CONCLUSION:

In summary, the study showed that vaginal misoprostol administered 3-4 hour before operative hysteroscopy reduce the need for cervical dilatation and facilitate hysteroscopic surgery.

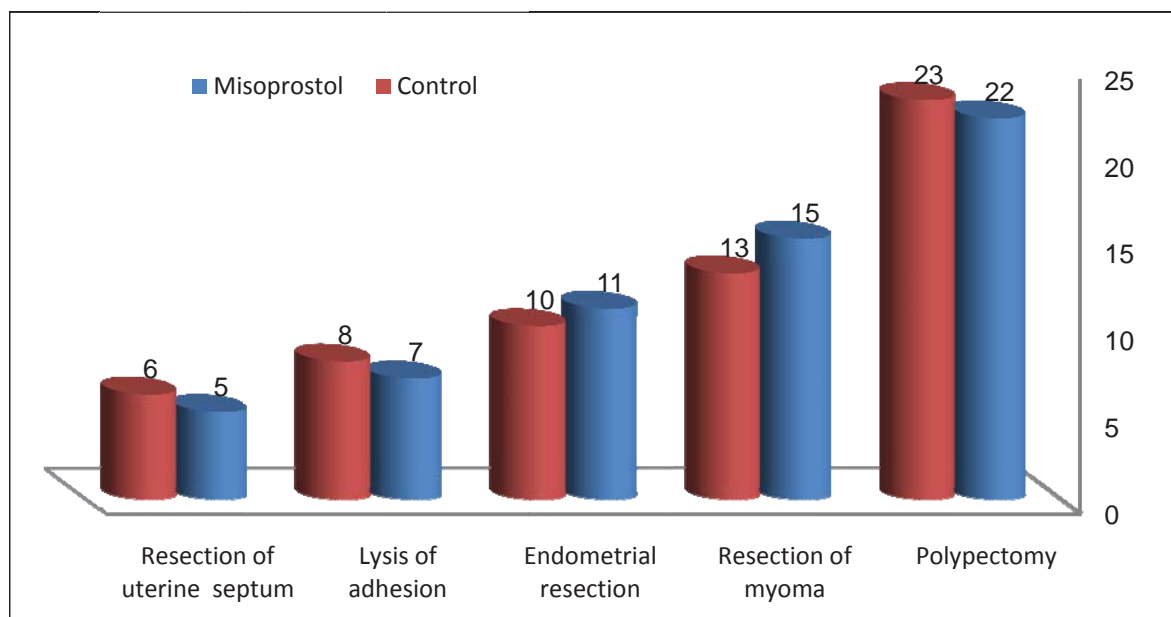


Figure 2: The performed of hysteroscopic procedures among women in Misurata Hospital, Libya

Conflict of interest statement:

No actual or potential conflict of interest exists in relation to this article.

REFERENCES:

1. Ghahiry AA, Refaei Aliabadi E, Taherian AA, Najafian A, Ghasemi M. Effectiveness of hysteroscopic repair of uterine lesions in reproductive outcome. *Int J Fertil Steril.* 2014 ;8(2):129-34
2. Bradley LD. Complications in hysteroscopy: prevention, treatment and legal risk. *Curr Opin Obstet Gynecol.* 2002; 14:409-415.
3. Jansen FW, Vredevogd CB, Van Ulzen K, et al. Complications of hysteroscopy: a prospective multicentre study. *Obstet Gynecol.* 2000; 96:266-270.
4. Wortman M. Complications of hysteroscopic surgery. In: Isaacson K, editor. *Complication of Gynecological Endoscopic Surgery.* Philadelphia: Saunders Elsevier; 2006. P. 185-200.
5. Rath W, Kuhn W, Hilgers R. Facilitation of cervical dilatation by intra cervical application of sulprostone gel prior to hysteroscopy. *Endoscopy* 1985; 17:191-193.
6. Hald F, Kristoffersen SE, Gregresen E. Prostaglandin vaginal suppositories in nonpregnant women required cervical dilatation prior to hysteroscopy. *Acta Obstet Gynecol Scand* 1988; 67:219-222.
7. Thomas JA, Leyland N, Durand N, Windrim RC. The use of oral misoprostol as a cervical ripening agent in operative hysteroscopy: a double-blind, placebo controlled trial. *Am J Obstet Gynecol* 2002; 186: 876-879.
8. Preutthipan S, Herabutya Y. A randomized comparison of vaginal misoprostol and dinoprostone for cervical ripening in nulliparous women before operative hysteroscopy. *Fertil Steril* 2006; 86:990-994.
9. Lee YY, Kim TJ, Kang H, Choi CH. The use misoprostol before hysteroscopic surgery in non-pregnant premenopausal women: a randomized comparison of sublingual, oral and vaginal administration. *Hum Reprod* 2010; 25:1942-1948.
10. Darwish AM, Ahmed AM, Mohammad AM. Cervical priming prior to operative hysteroscopy: a randomized comparison of laminaria versus misoprostol. *Hum Reprod* 2004; 19: 2391-2394.
11. Dan Yu, Tin-Chin Li, Enlan Xia, Xiaowu Huang. A prospective, randomized, controlled trial comparing vaginal misoprostol and osmotic dilator in achieving cervical ripening before operative hysteroscopy. *Gynecol Surg* 2006, 3:186-189.
12. Lin YH, Hwang JL, Seow KM, Huang LW, Chen HJ, Hsieh BC. Laminaria tent vs misoprostol for cervical priming before hysteroscopy: Randomized study. *J Minim Invasive Gynecol* 2009; 16(6):708-12.
13. Goldberg AB, Greenberg MB, Darney PD. Misoprostol and pregnancy. *N Engl J Med* 2001; 344:38-47.
14. Austin SC, Sanchez-Ramos L, Adair CD. Labor induction with intravaginal misoprostol compared with the dinoprostone vaginal insert: a systematic review and met analysis. *Am J Obstet Gynecol* 2010; 202(6):624.
15. Batukan C, Ozgun MT, Ozcelik B, Aygen E, Sahin Y, Turkyilmaz C. Cervical ripening before operative hysteroscopy in premenopausal women: a randomized, double-blind, placebo-controlled comparison of vaginal and oral misoprostol. *Fertil Steril* 2008; 89(4):966-973.
16. Tanha FD, Salimi S, Ghajarzadeh M. Sublingual versus vaginal misoprostol for cervical ripening before hysteroscopy: a randomized clinical trial. *Arch Gynecol Obstet* 2013; 287(5):937-40.
17. Song T, Kim MK, Kim ML, Jung YW, Yoon BS, Seong SJ. Effectiveness of different routes of misoprostol administration before operative hysteroscopy: a randomized, controlled trial. *Fertil Steril* 2014; 102(2):519-24.
18. Zieman M, Fong SK, Benowitz NL, et al. Absorption kinetics of misoprostol with oral or vaginal administration. *Obstet Gynecol* 1997; 90: 88-92.
19. El-refacy H, Calder L, Wheatley DN, Templeton A. Cervical priming with prostaglandin E1 analogues, misoprostol and gemeprost. *Lancet* 1994; 343:1207-1209.
20. Goyal B, Roy P, Bhat P, Das N, Paul K, Duggal B. Intracervical versus vaginal misoprostol for cervical dilatation prior to operative hysteroscopy-a comparative study. *Med J Armed Forces India.* 2012; 68(2):129-31.
21. Arena S, Zupi E, Affronti G. Cervical ripening prior to hysteroscopy: is the application of misoprostol useful. *Minerva Ginecol* 2011; 63(5):439-48.
22. El-Mazny A, Abou-Salem N. A double-blind randomized controlled trial of vaginal

- misoprostol for cervical priming before outpatient hysteroscopy. *Fertil Steril* 2011; 96(4):962–965.
23. Sordia-Herna'ndez LH, Rosales-Tristan E, Vazquez-Mendez J, et al. Effectiveness of misoprostol for office hysteroscopy without anesthesia in infertile patients. *Fertil Steril* 2011; 95(2):759–761.
 24. Oppegaard KS, Nesheim B-I, Istre O, Qvigstad E. Comparison of self-administered vaginal misoprostol versus placebo for cervical ripening prior to operative hysteroscopy using a sequential trial design. *Br J Obstet Gynecol.* 2008; 115(663):e1-e9.
 25. Uckuyu A, Ozcimen EE, Sevinc FC, Zeyneloglu HB. Efficacy of vaginal misoprostol before hysteroscopy for cervical ripening in patients who have undergone cesarean section and no vaginal deliveries. *J Minim Invasive Gynecol.* 2008; 15: 472-475.
 26. Gkrozou F, Koliopoulos G, Vrekoussis T et al., A systematic review and meta-analysis of randomized studies comparing misoprostol versus placebo for cervical ripening prior to hysteroscopy. *Eur J Obstet Gynecol Reprod Biol* 2011; 158(1):17-23.
 27. Preutthipan S, Herabutya Y. A randomized controlled trial of vaginal misoprostol for cervical priming before hysteroscopy. *Obstet Gynecol.* 1999; 93:427-430.
 28. Preutthipan S, Herabutya Y. Vaginal misoprostol for cervical priming before operative hysteroscopy: a randomized controlled trial. *Obstet Gynecol.* 2000; 96:890-894.