

Osteopetrosis: A Case Report and Review of the Literature

Emadian O¹, Kariminasab M², Montazer F¹, Shayesteh Azar M², Sajjadi Saravi M²,
Daneshpoor SMM^{2*}

ABSTRACT

Osteopetrosis or marble bone disease is a rare heritable skeletal disorder that the bones becoming denser, caused by aberrant osteoclast-mediated bone resorption. This condition reveals a spectrum of heterogeneity of genetic defects. This metabolic disorder has an unequal balance between new bone formation and old bone resorption. Thus the result is increased bone density on radiographs. Presented here is a 25 years-old Persian female presented to our clinic with the chief complaint of low back pain and limping. She explained that her problem had been present for a long time. There were no other significant findings in past medical history and her parents and three siblings did not have any disorder of note, however, the parents were first cousin. No specific laboratory abnormalities found in the initial evaluation. On physical examination, an antalgic gait is noted. A Bone biopsy from proximal medial tibia revealed increased density of the cortex and part of medullary canal with hematopoietic marrow and irregular and thickened bone trabeculae. These factors suggested osteopetrosis disease. Osteopetrosis should be kept in mind as a rare cause of low back pain and limping and should be mentioned as a differential diagnosis of fluorosis, Paget's disease, malignancies (lymphoma, osteoblastic cancer metastases) and myelosclerosis.

Keywords: Osteopetrosis, marble bone disease, bone trabeculae, Iran.

Osteopetrosis is a rare congenital disorder of osteoclast function and /or development characterized by impaired bone resorption and increased density of all bones¹⁻³. The long bones are usually shortened and frequently exhibit a remodeling defect (the Erlenmeyer flask deformity) characterized by loss of the normal metaphyseal flare.

Despite the increased bone density, the disease is often complicated by multiple fractures resulting from a disturbed Micro-architecture. Reduction in the size of the foramina in the skull leads to optic and auditory nerve compression with visual and auditory defect. Several rare genetic mutations are present. These mutations lead to varying degrees of dysfunction of the osteoclasts^{4,5}. This causes an imbalance between the osteoclasts and osteoblasts,

resulting in excess bone formation and abnormal bone modeling. The end result is variable depending on the severity of osteoclast dysfunction and can range from asymptomatic adults with normal life expectancy to early infantile death⁶. Two genetic types of osteopetrosis are known: autosomal dominant and autosomal recessive⁴. Autosomal dominant osteopetrosis (1/20000 birth) also known as osteopetrosis tarda or Albers Schoinberg disease presents in adulthood. Most patients have a normal lifespan and are asymptomatic approximately 50% of the time⁶. The most common clinical manifestation is increased fragility of bone leading fractures. Autosomal recessive osteopetrosis also known as osteopetrosis congenita, is a rare disease of infancy to early childhood with a rate of 1/300000 birth worldwide with an exception of Costa Rica where the rate is much higher (3-4/100.000 birth). It can cause bone marrow failure due to obliteration of the marrow cavity, as well as blindness and deafness due to narrowing of the bony neural formation⁶.

1.Department of Pathology, School of medicine, Mazandaran University of medical sciences, Sari, Iran.

2.Department of orthopedic surgery, School of medicine, Mazandaran University of medical Sciences, Sari, Iran

*Correspondence to: dr.daneshpoor@gmail.com

Most children with autosomal recessive osteopetrosis do not survive beyond 10 years of age. Intermediate recessive osteopetrosis and marble bone or marble brain disease are 2 types of autosomal recessive osteopetrosis with different clinical presentations. This type caused by a mutation in the gene encoding CAII resulting in carbonic anhydrase II deficiency. The patients with intermediate recessive osteopetrosis are affected to degree between severe autosomal recessive osteopetrosis and mild autosomal dominant osteopetrosis and may have a short stature, anemia, hepatomegaly, and multiple fractures. In marble bone or marble brain disease, patients develop renal tubular acidosis and intracranial calcifications and may be developmentally disabled. The few X-Linked cases have been associated with ectodermal dysplasia, lymphedema and immune deficiency^{1-3,5,6}.

Case Report:

A 25 year old Persian female presented to our clinic with the chief complaint of low back pain and limping. She explained that her problem had been present for a long time. There were no other significant findings in past medical history and her parents and three siblings did not have any disorder of note, however, the parents were first cousin.

On physical examination, an antalgic gait is noted. A shortening of 2 cm and fixed adduction contracture and limitation of all hip motions at the left side were additional findings.

X-rays and biochemical laboratory investigations were ordered. No specific laboratory abnormalities found in the initial evaluation. Serum calcium, phosphate and alkaline phosphatase and sedimentation rate were particularly in normal range. On lumbosacral x-ray, diffuse sclerosis of vertebrae and sandwich bone appearance were seen.

The same feature of diffuse sclerosis was apparent on pelvic and knee x-rays. (Figures (1, 2)).

A Bone biopsy from proximal medial tibia was done.

On microscopic examination, whole-mount transverse sections of the specimen showed increased density of the cortex and part of medullary canal with hematopoietic marrow. Other sections revealed irregular and thickened bone trabeculae (Figure 3) as well as central core of calcified cartilage.

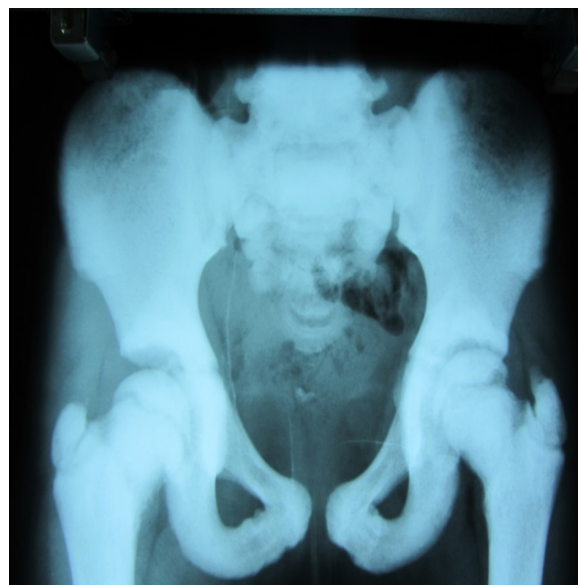

Figure (1): Pelvic x-ray in this patient shows thick dense bone.

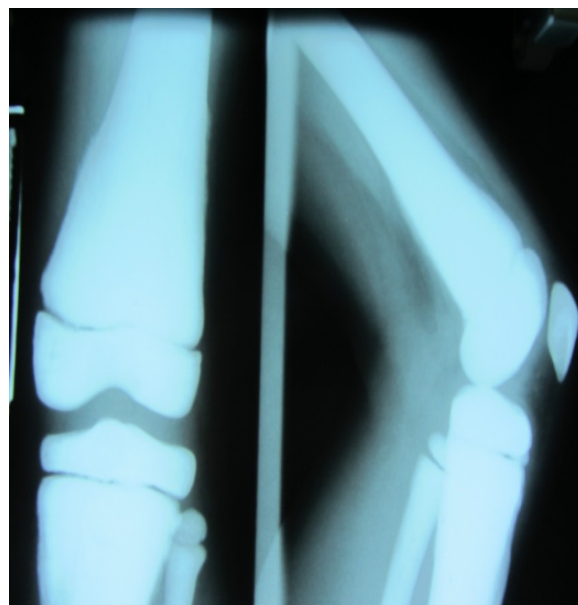


Figure (2): knee x-ray of the patient with marble bone disease.

Numerous osteoclast-like cells adjacent to the bony trabeculae are present (Figure 4). Based on radiographic, clinical and histological presentation; the final diagnosis was osteopetrosis most probably autosomal

dominant form. We suggest total hip arthroplasty for her and she want to decide it.

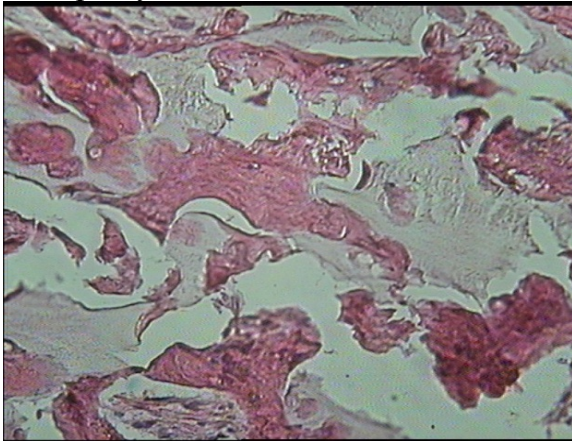


Figure (3): Microscopic section reveals extremely thick bone trabeculae.

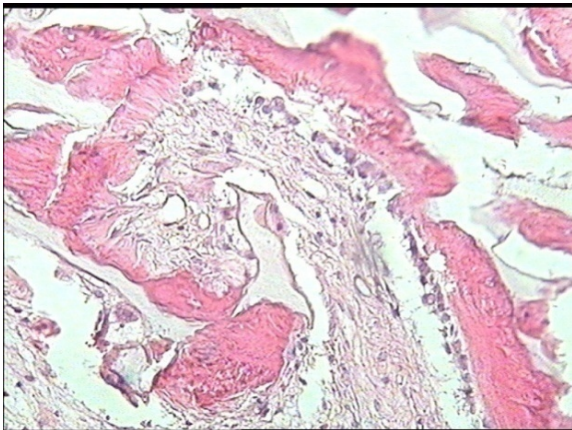


Figure (4): microscopic section shows irregular bone trabeculae with central core of cartilage.

DISCUSSION:

Radiography and computed tomography are the most useful modalities to evaluate osteopetrosis. Magnetic resonance imaging can be helpful in more severe cases of autosomal recessive osteopetrosis to determine the amount of remaining marrow space. Bone marrow distribution of the disease is best shown by technetium-99m sulfur colloid scintigraphy⁸. On radiographs, osteopetrosis presents as dense bone or osteosclerosis⁹. A characteristic radiographic appearance of osteopetrosis has been termed bone-in-bone, in which the dense internal sclerosis appears as cortical bone inside the medullary cavity of the bone^{8,9}.

This is most commonly seen in the iliac wing and epiphyses of the femur, humerus, tarsal

bones and ribs⁸. In the vertebrae, dense sclerosis of the superior and inferior endplates can be observed and has been termed sandwich vertebra⁴. Autosomal recessive osteopetrosis presents early in infants. Pathological fractures are typical. The abnormality in bone remodeling can result in under-tubulation of the long bones, which can have a club like shape or an Erlenmeyer flask appearance. Ribs tend to be sclerotic, and horizontal lucent lines may be present^{4,8}.

Individuals with autosomal dominant osteopetrosis tend to have symmetrical abnormalities. Two types, based on radiograph appearance, are preserved. Type 1 is characterized by marked cranial sclerosis and calvarial thickening with minimal or no sclerosis in the vertebrae, patchy sclerosis in the pelvis, and diffuse sclerosis and cortical thickening in the tubular bones. Type 2 is characterized by a normal calvarium except for sclerosis at the skull base, vertebral involvement with thickening and sclerosis of the endplates, and dense sclerotic bones in the pelvic, especially along the iliac arcs. Transverse sclerotic banding is also common. Dental caries and abscesses, as well as sensory or motor loss in cranial nerves associated with foramina stenosis, are also indicators of type 2 autosomal recessive osteopetrosis^{7,8}.

Grossly the density of the affected bone is increased and they may weigh two to three times more than normal despite usually being somewhat smaller than normal. On sectioning the bone tissue is very compact, showing loss of the normal architecture¹⁰.

Microscopically extremely dense and irregular bone trabeculae are usually seen, nearly all of which have a central core of cartilage. Although a paucity of osteoclasts has been reported in osteopetrosis, microscopic examination shows that osteoclasts are often abundant¹⁰.

When examined under electron microscope, these osteoclasts lack ruffled borders, and although they are close to the bone, they do not show the normal cytologic features of actively resorbing osteoclasts¹⁰. Most cases of osteopetrosis are associated

with a failure of osteoclast function resulting in disturbances of intracellular and extracellular pH of the osteoclast resorption compartment which leads to impaired resorption of organic acid and inorganic bone matrix. In some cases there is a failure of osteoclast development, this autosomal recessive form is associated with a mutation of the RANKL gene^{1-3,5}.

The increased bone sclerosis may show reduced marrow space and impaired myeloid hematopoiesis, anemia, bone marrow failure, and accompanied by extramedullary hematopoiesis with hepatosplenomegally and leukoerythroblastic blood picture⁷.

The differential diagnosis includes primary sclerosing conditions of bone caused by osteoclast dysfunction and need to be distinguished from the large number of conditions in which bone sclerosis can occur as a secondary phenomenon. Some alternative diagnoses to consider include fluorosis; Paget's disease (sclerosing form), malignancies (lymphoma, osteoblastic cancer metastases) and myelosclerosis¹⁰.

Treatment for osteopetrosis is largely based on symptoms⁴. Autosomal dominant osteopetrosis requires no treatment unless pathologic fractures exit. However, more than half of all patients diagnosed with autosomal dominant osteopetrosis will need orthopedic surgery at some time. Because of the abnormal bone remodeling, delayed union or nonunion of fractures are common problems¹¹.

During surgical fixation of fractures in these patients, problems can be encountered due to the hard and brittle bones, including perioperative fracture at the site of stress risers, such as screw holes and broken drill bits^{8,11}. Due to the increased complications of surgery, casting of fractures is the preferred treatment when possible¹¹. Patients with autosomal recessive osteopetrosis may need red blood cell and platelet transfusions, and haematopoietic stem cell transplantation (HSCT) in severe cases of bone marrow dysfunction^{4,5} which is successful in approximately 50% of cases. Interferon γ , can improve immunity, increase bone resorption, and enlarge the marrow space^{4,11}.

Other therapies that can be useful in stimulating osteoclast function in autosomal recessive osteopetrosis include calcium restriction and treatment with calcitriol, steroids, and parathyroid hormone^{12,13}.

After HSCT there is gradual resorption of the abnormal bone structure, regression of the cartilaginous plate, and expansion of the medullary space with abundant hematopoietic tissue. Also regression of splenomegaly and reversal of leukoerythroblastic blood picture are present^{14,15}.

CONCLUSIONS:

Osteopetrosis should be kept in mind as a rare cause of low back pain and limping and should be mentioned as a differential diagnosis of fluorosis, Paget's disease, malignancies (lymphoma, osteoblastic cancer metastases) and myelosclerosis. On the other hand diagnosis of this disease and rule out the others can differentiate the prognosis of the patients.

Competing interests:

The authors declare that they have no competing interests.

Ethical considerations:

Written informed consent was obtained from the patient for publication of this case report and accompanying images.

REFERENCES:

1. Del Fattore A, Cappariello A, Teti A. Genetics, pathogenesis and complications of osteopetrosis. *Bone*, 2008;42: 19-29.
2. Kilpatrick I. Osteopetrosis, In Damjanov I, et al. *Anderson's Pathology*, ed. 10. StLouis, Mosby, 1996; 2585, 2586.
3. Tolar I, Teitelbaum SL, Orchard PI. Osteopetrosis. *N Engl J Med* 2004, 351: 2839-2849.
4. Stark Z, Savarirayan R. Osteopetrosis. *Orphanet J Rare Dis* . 2009;4:5.
5. Askmyr MK, Fasth A, Richter J. Towards a better understanding and new therapeutics of osteopetrosis. *Br J Haematol*: 2008;140(6):597-609.
6. Carolino J, Perez JA, Popa A. Osteopetrosis. *Am Fam Physician*: 1998;57(6):1293-1296.
7. Sobacchi C, Schulz A, Coxon FP, et al. Osteopetrosis: genetics, treatment and new insights into osteoclast function. *Nat Rev Endocrinol*. 2013 Sep;9(9):522-36.

8. Stoker DJ. Osteopetrosis Semin Musculoskelet Radical. 2002;6(4):299-305.
9. Resnick D, Bralow GW. Osteopetrosis Diagnosis of bone and joint Disorders. 4 th ed. Philadelphia, PA:WB Saunders: 2002;4489-4491.
10. Whyte MP, Madson KL, Mumm S, et al. Rapid Skeletal Turnover. In A Radiographic Mimics Of Osteopetrosis. J Bone Miner Res. 2014; 12-14.
11. Landa J, Marrgilis N, Di Cesare P. Orthopaedic Management of the patient with osteopetrosis. J Am Acad Ortop Surg 2007; 15(11):654-662.
12. Kocher MS, Kasser JR. osteopetrosis. Am J Orthop (Belle Mead NJ). 2003;32(5):222-228.
13. Key L, Cames D, Cole S. Treatment of congenital osteopetrosis with high dose calcitriol. N Engl J Med. 1984; (310):409-415.
14. Coccia PI, Krivit W, Cervenka I, et al. Successful bone marrow transplantation for infantile malignant osteopetrosis. N Engl J Med, 1980; 302: 701-708.
15. Gerritsen EI, Vossen IM, van Loo III, et al. Autosomal recessive osteopetrosis: variability of findings at diagnosis and during the natural course. Pediatrics, 1994;93: 2~ 7-253.