

Case Report

Blood Changes after Splenectomy in Portal Hypertension. The 'Amna Model'

Gamal E H A el Shallaly^{1*}, Hatim K Karrar², Aymen EA Doumi³

Abstract

Background: Splenectomy is a frequently performed operation for patients with portal hypertension and hypersplenism in areas endemic for schistosomiasis.

Reactive thrombocytosis (RT) has been described following splenectomy. Nevertheless, data are lacking on the long term changes of platelet count and other blood cells and indices after splenectomy in such patients.

Objectives: To determine the hematological changes following splenectomy in portal hypertension due to schistosomiasis.

Methods: This is a prospective, observational, case study in which we did a series of full blood counts before and after splenectomy on two patients. The periods of study were 12 days and 5 months, respectively.

Results: Platelets ($RT >500 \times 10^9$) occurred after the 7th post-splenectomy day in both patients. In the longer study, RT continued from day 8 to week 10. Extreme thrombocytosis ($> 1000 \times 10^9$) occurred from day 11 to day 21 postoperatively. The count was back to normal by week 17.

Reactive leukocytosis occurred immediately after ligation of the splenic artery, but returned to normal levels during the 2nd postoperative week.

Erythrocytes, however, showed changes different from both platelets and leukocytes. There was 'persistent anaemia' for about one month postoperatively.

Conclusion: This study provides data that were lacking on the long term haematological effects of splenectomy in Sudanese patients with portal hypertension. Knowing these changes can have important implications on the management and follow up of such patients, and provide evidence needed for discussing guidelines of treatment.

RT and leukocytosis occur after splenectomy whereas anaemia persists. RT can reach extreme levels and it is wise to monitor the platelets after the discharge of patients from the hospital. It may also be wise to consider the use of antiplatelet drugs postoperatively till the count normalizes. The persistent anaemia, however, seems to correct itself without giving haematinics or blood transfusion.

Key words: postsplenectomy, thrombocytosis, portal hypertension, hypersplenism.

Splenectomy, alone or as part of a devascularization operation, is a frequently performed procedure for patients with portal hypertension, especially in areas endemic for schistosomiasis. Common indications include a huge spleen and hypersplenism causing anaemia, leucopenia, and thrombocytopenia^{1,2}.

Normal platelet count is between 100 000-450 000/mm³ ($100-450 \times 10^9/L$).

Many authors define thrombocytosis (thrombocythaemia) as a count exceeding 500 000/mm³ ($>500 \times 10^9$).

Extreme thrombocytosis (ET) is a term used when the count exceeds 1000 000/mm³ ($>1000 \times 10^9$)³.

Postsplenectomy reactive thrombocytosis (RT) is a wellknown complication that occurs in up to 82% of cases. It causes thromboembolic complications in about (5%-10%) of cases according to different authors where splenectomy was done mainly for trauma and/or malignancy⁴⁻⁶. These

1. Professor of Surgery, Alazhari University.

2. Associate Professor, and consultant haematologist, Khartoum Medical Science College

3. House officer, Khartoum North Teaching Hospital

*Correspondence to: gamalshallaly@rcsed.ac.uk

thromboembolic complications may affect veins or arteries. They include portal, mesenteric, splenic veins as well as calf (deep) vein thrombosis, and the pulmonary artery causing pulmonary embolism. Arterial thrombosis causing myocardial infarction has also been reported⁷. Higher incidence of portal vein thrombosis, reaching 25% was found in patients with idiopathic portal hypertension with esophageal varices after splenectomy and was related to the decrease in portal blood flow⁸. One of these reports found a positive correlation between the occurrence of portal thrombosis and the size and weight of the removed spleen⁵. The incidence of thrombo-embolism, thus depends on the underlying cause of the splenectomy. Unfortunately data are lacking on patients with portal hypertension and hypersplenism due to schistosomiasis who undergo splenectomy, regarding the extent and duration of RT which may reach extreme levels. Moreover, despite the documented thrombo-embolic complications mentioned above, there are no clear clinical guidelines for postoperative prophylaxis against thrombocytosis. In fact there are controversial reports on the necessity of the use of antiplatelet prophylaxis after splenectomy. Moreover, data on changes of red blood cells (RBCs) and white blood cells (WBCs) after splenectomy for portal hypertension and hypersplenism are lacking.

Case Report:

The first patient was a 50 year old male who underwent splenectomy for hypersplenism and portal hypertension. He had splenectomy and ligation of the left gastric (coronal) vein. He was followed up for 12 days. He disappeared from follow up after feeling well and traveled back to the Western Province of Darfur. The peri-operative period was uneventful but we noticed that his platelets were increasing. They reached $(714 \times 10^9 / L = 714000 / mm^3$ or $/\mu L)$ at day 12 postoperatively, whereas his RBCs were $(<5 \times 10^9 / L)$ and Hb was still below 10 gm/dl (Figure 1).

The patient was lost from follow up. However, these data raised our curiosity to

know about the longer term blood changes following splenectomy in patients with portal hypertension and hypersplenism and was the basis for this study.

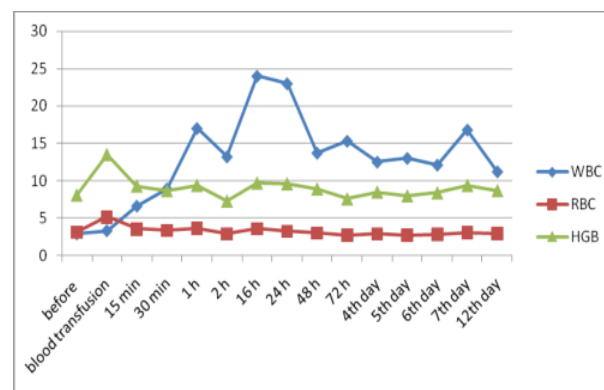


Figure 1. Patient 1: Showing white blood cells (WBC), red blood cells (RBC) and haemoglobin (HGB) levels before and after splenectomy. Note the 'persistent anaemia' (HGB < 10 gm/dl) up to day 12 post-splenectomy.

The 2nd patient was, fortunately, from Khartoum province and was willing to be followed up for a longer period. This was a 35 year old female who lived in Khartoum province all her life. She denies ever living in Gazira province which is an endemic area for schistosomiasis. She couldn't remember suffering from intestinal schistosomiasis as a child. She, however, remembered playing and meddling in canals carrying Nile water at AlhajYousef (East Blue Nile district of Khartoum North).

The patient was referred to us from the medical department as a case of hypersplenism secondary to portal hypertension due to schistosomalperiportal fibrosis diagnosed on ultrasound scan of her abdomen. Her portal hypertension was diagnosed 12 years before, but she was off treatment and had disappeared from follow up for about 6 years before presentation. She presented with a dragging pain in the left upper quadrant area. No history of hematemesis, melena, or jaundice. She was not diabetic or hypertensive and gave no history of blood transfusion. She had a family history of diabetes mellitus. She was not a cigarette smoker, tobacco snuffer, or alcohol

consumer. She was on birth control combined pills and a three monthly injection of Depo-Provera. She had no history of drug allergy. *On examination*, she looked unwell, pale, but was not jaundiced. There was no dyspnoea, no finger clubbing. Her pulse was 80/min, regular with good volume. The blood pressure was 110/70. Abdominal examination revealed a huge splenomegaly that was 25 cm below the left costal margin (Figure2). Examination of other systems was normal.

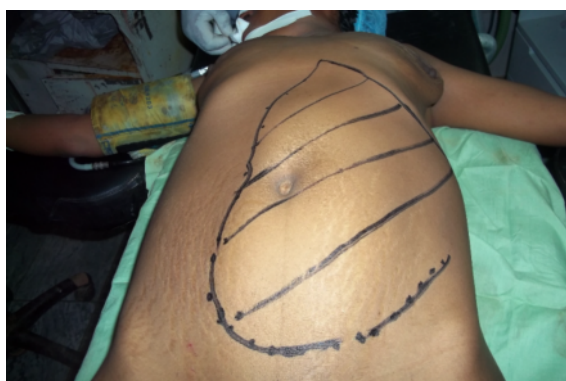

Figure2. Patient2: Note the huge spleen extending almost to pubic symphysis.

Her investigations showed anaemia, with haemoglobin (HGB) of 7.6 gm/dl, and leucopenia with a total white blood cell count (TWBC) of 1.8×10^9 /L, and thrombocytopenia with platelet count of 41×10^9 /L. Urine analysis showed mild infection. Both the liver and renal function tests were normal. Abdominal ultrasound showed an average liver size, displaying extensive periportal fibrosis with a dilated portal vein measuring 25 mm in diameter. It also showed enlarged spleen with dilated splenic vein (22 mm in diameter).

Bone marrow aspiration showed hypercellular marrow with increased elements (megakaryopiosis, erythropoiesis, myelopoiesis, and high erythrocyte/megakaryocyte ratio). Iron stain of the bone marrow showed low iron deposits. We could not do inflammatory factors (e.g. interleukin (IL)-6), erythropoietin or thrombopoietin due to lack of facilities.

The patient received three units of blood and nine units of platelets preoperatively, four units of blood and seven units of platelets and six units of fresh frozen plasma intra-

operatively. Postoperatively, she was given two units of blood and six units of platelets. *The splenectomy* was done via a long midline incision.

The lesser sac was entered and splenic artery, which was abnormally running inferiorly, was identified and ligated. A blood sample was taken immediately after ligation. The spleen was luckily free with no adhesions between it and the diaphragm. Splenectomy was completed by dividing the gastrosplenic vessels. The spleen measured 30 cm x 16 cm (Figures 3), and weighed 3 Kilograms.

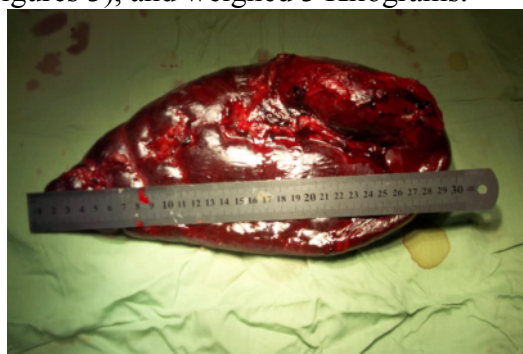

Figure3. Spleen measurements (30 cm in length).

Blood for complete blood count was drawn before, during the operation and postoperatively.

Post operatively the patient was admitted to the intermediate care unit for close monitoring of her vital signs and general clinical condition. We monitored her blood count as well as her renal functions daily.

The patient had an uneventful early recovery. She started oral fluid intake at increments of 30 mls/ hour on the 3rd post operative day, and was allowed free oral intake (diet) by the 5th postoperative day. She received broad spectrum antibiotics intravenously at induction of anaesthesia and continued postoperatively. However, on the 3rd postoperative day she had two peaks of fever at 9:00am and 12:00 midnight with temperature of 39.1°C at its maximum. The immune-chromatographic test (ICT) for Malaria was positive and Artemether injections were given.

On the 7th post operative day the patient's respiratory rate increased to 45/min, PR= 100,

BP=120/80, Temp= 38.4°C. Her fluid balance was negative at (-1.05L/day). There was a raised jugular venous pressure (JVP) and a chest X-ray revealed a moderate right sided pleural effusion. Right sided heart failure and pulmonary embolism were suspected. D-dimer test was 2.3 (normal= less than 0.3mg/L). Ventilation/perfusion (V/Q scan) and CT pulmonary angiography were not available. Meanwhile her platelet count reached extremely high counts with the peak of $1170 \times 10^9/L$ on the 11th post operative day. The patient was, therefore, started on a therapeutic dose of heparin to treat suspected pulmonary embolism, as well as small dose of Aspirin. Intravenous frusemide to help diuresis was given for her right heart failure with K supplementation to guard against hypokalemia.

By the 13th post operative day, the patient’s respiratory rate dropped to 24/min and the pleural effusion subsided on chest X-ray. However, her two daily peaks of high temperature didn’t disappear although her blood culture was sterile and WBC count was normal ($7.8 \times 10^9/L$ or $7800/mm^3$). Two ultrasound examination of abdomen done by a competent radiologist didn’t reveal any intra-abdominal abscess or portal system thrombosis. A careful review of the patient with the nursing staff revealed cellulitis at the cannula site. The cannula was changed. Ciprofloxacin infusion and local mupirocin cream were prescribed. Two days later, the temperature returned to normal.

The patient was followed up for an additional three days during which she was doing very well with no new complaints. The vital signs were normal. The surgical wound healed, and the platelets started to decrease. The patient received pneumococcal and meningococcal vaccination as soon as they became available. The patient was discharged on the 23rd post operative day in a good condition with a platelet count of ($865 \times 10^9/L$). As the patient was on contraceptive plans before the operation, we arranged for the obstetricians to see her for advice.

The patient was scheduled for regular follow up visits in the outpatient clinic. The check

up included full blood counts which was done before each visit for a period of more than 4 months.

Platelets (Figure 4)

Preoperatively the platelet count was very low ($28-32 \times 10^9/L$). Fresh blood and platelet transfusion raised the count to $52 \times 10^9/L$ on theatre day.

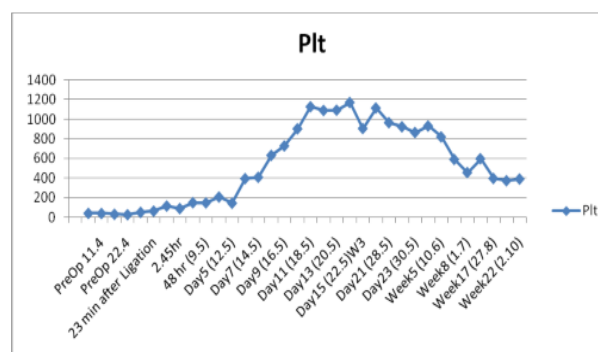


Figure4: Postsplenectomy Platelets. ReactiveThrombocytosis from day8 to week 10 with Extreme levels between from day 11 to day21.

Immediately after ligation of the splenic artery at operation, the platelets count started to increase. Their number exceeded the normal level (RT) after day 7 postoperatively (i.e. during the second postoperative week) as they did in the first patient (Figure 1). The platelet count exceeded the 1000000 mark ($1000 \times 10^9/L$) at day 11. This extreme thrombocytosis (ET) reached a peak ($1170 \times 10^9/L$) at day 14. It started to go below the 1000000 mark from day 21 ($965 \times 10^9/L$), and continued to decrease gradually and slowly. Only at week 17 did it come down to the normal range ($397 \times 10^9/L$). Hence, RT occurred between day 8 and week 17, with ET between day 11 and day 19 postsplenectomy (Table1).

WBCs (Figure 5)

The pre-operative count was low at $2.3-4.9 \times 10^9/L$ reaching its lowest level on theatre day ($2.4 \times 10^9/L$). There was an immediate rise (leukocytosis), the WBC count doubled in less than half an hour (4.8×10^9) after ligation of the splenic artery, and increased gradually reaching five times the preoperative level

(17.4 x10⁹/L) after 24 hours (day 1) postoperatively. It reached a peak (20 x10⁹/L) after 48 hours. Leukocytosis continued till day 10 (12.4 x10⁹/L), then decreased to

normal level (9.7 x10⁹/L) from day 11, staying between 6-7.5 x10⁹/L from week seven till the end of the study (week 22).

Table1. Patient2. Blood counts pre- and post-splenectomy. Follow up period 5months.

Time	WBC	RBC	Hb	Plt
PreOp 1.3	1.8	4.21	7.6	41
PreOp 11.4	1.8		10	40
PreOp 17.4	2.3	5	11.2	32
PreOp 22.4	2.5	4.94	11.2	28
Theatre7.5	2.4	4.14	9.9	52
23 min after Ligation	4.8	4.95	11.3	64
1hr	5.3	5	11.9	116
2.45hr	4.3	4.87	11.4	90
24 hr(8.5)	17.4	2.8	8.6	150
48 hr (9.5)	20	2.8	7.3	148
72hr (10.5)	14.9	2.63	7.3	208
Day5 (12.5)	12.3	3.6	10.2	145
Day6 (13.5)	13	4.34	11.3	395
Day7 (14.5)	14.7	4.03	10.7	409
Day8 (15.5)W2	12	4.21	11	632
Day9 (16.5)	11	4.19	10.7	728
Day10 (17.5)	12.4	4.37	11	902
Day11 (18.5)	9.7	4.28	10.8	1127
Day12 (19.5)	6.7	4.84	12.5	1089
Day13 (20.5)	7.8	4.45	11.4	1092
Day14 (21.5)	5.5	4.4	11.2	1170
Day15 (22.5)W3	5.6	3.91	10.2	905
Day19 (26.5)	5.4	4.3	11.3	1114
Day21 (28.5)	6.3	4.1	11.7	965
Day22 (29.5)W4	6.5	4.45	11.6	923
Day23 (30.5)	9.1	4.3	11.5	865
Day27 (3.6)	8.6	4.68	12.4	931
Week5 (10.6)	8.4	4.79	13.1	820
Week7 (24.6)	6	4.8	12.4	591
Week8 (1.7)	7.5	4.9	13.2	457
Week10 (15.7)3rdM	6.6	5.14	13.3	598
Week17 (27.8)	7.3	5.05	14.4	397
Week19 (11.9)	6	5	13.2	374
Week22 (2.10)	6.2	4.8	12.5	391

During this time the patient had malaria on the3rd postoperative day, suspected, but not

proven- pulmonary embolism between day seven and day 13, and fever due to cannula

site infection till day 15 postoperatively. The WBC remained within normal from day 11 onwards. The patient did not report any complication thereafter and during the follow up period of 17 weeks.

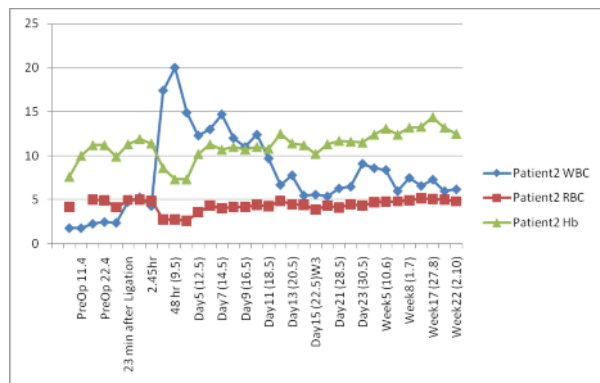


Figure 5. Post splenectomy White and Red blood cells and haemoglobin. Note the leukocytosis and persistent anaemia.

The platelet to WBC ratio was less than 20 pre-operatively and stayed generally below 20 till day five (except for one reading after 2.5 hrs after ligation of splenic artery). Apart from malaria that was diagnosed on the 3rd postoperative day, there was no evidence of infection during this time period. The Platelet/WBC ratio increased to above 20 from day six onwards despite the presence of a right-sided pleural effusion that was evident on a chest x-ray at day seven.

RBCs

When we first received the female patient, her RBCs and HGB were very low with the latter at (7.6 gm/dl). The patient received blood transfusion in the peri-operative period, and on theatre day the HGB was 9.9 gm/dl. She received four units of blood and seven units of platelets and six units of fresh frozen plasma intra-operatively. Postoperatively, there was no erythrocytosis. In fact there was persistent anaemia. She had blood transfusion only once, at day three postoperatively which elevated the HGB from 7.3 to 10.2 gm/dl. Nevertheless, the HGB stayed generally below the 11gm/dl mark till day 11 postoperatively, and only reached the normal level of 12.4 gm/dl on 27th postoperative day. From that day onwards, it

stayed within the normal range, between 12-14.4 gm/dl. The patient was not given iron tablets at any point.

Other Red Blood Cell indices (Figure 6)

These included: the haematocrit (HCT) (N.36-46%), mean corpuscular volume (MCV) (N.83-101 fl), mean corpuscular haemoglobin (MCH)(N.27-32pg), and mean corpuscular haemoglobin concentration (MCHC) (N. 31.5-34.5 gm/dl). All these indices confirmed that the preoperative anaemia of ‘hypersplenism’, which was microcytic hypochromic type, continued for about a month postoperatively. They reached normal levels together with the RBC count and HGB at day 27 postsplenectomy. There was no erythrocytosis at any time, in contrast to the thrombocytosis and leukocytosis that occurred postoperatively.

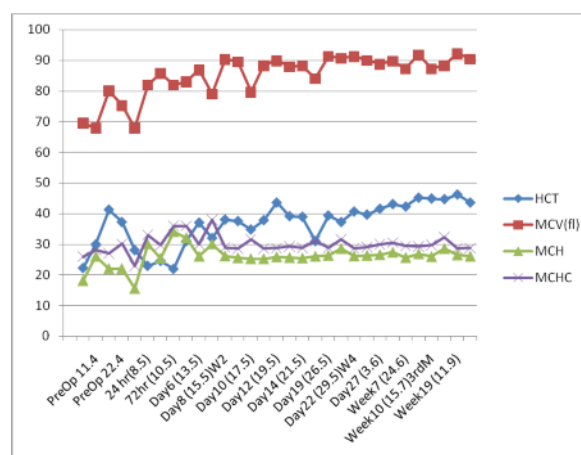


Figure 9. Haematocrit and other RBC indices

The Bone Marrow (BM)

The patient had a BM aspiration once preoperatively and after two weeks postoperatively.

The preoperative BM aspiration showed hypercellular bone marrow with increased elements (Megakaryopiosis, Erythropoiosis, Myelopoiosis, and high E: M ratio). Iron stain of the BM showed low iron deposits. The postoperative BM showed the same preoperative findings. Unfortunately, we could not test for inflammatory factors such as (IL-6), erythropoietin and thrombopoietin, as these tests were unavailable.

Discussion:

This study revisits the effects of splenectomy on blood cells. However, it focuses on patients with portal hypertension and hypersplenism caused by schistosomiasis in a developing country.

Platelets changes

Our results agree with the findings of other authors regarding the occurrence of RT (from day 8-week 17)⁹.

The cause-effect relation between RT and the occurrence of thrombo-embolic complication has been controversial^{5,9-11}.

Those who advocated cause-effect relation^{5, 11} identified three risk factors for thromboembolism. These included high platelet counts ($>650 \times 10^9$), a huge spleen (>650 gm), and thrombophilia disorders. Both the first and second factors were present in our patients, and a large spleen is frequently seen in portal hypertension patients.

Hypercoagulable state and increased blood viscosity after splenectomy and associated with increased platelets and decreased RBC deformability were reported^{12, 13}.

From the above studies, it is clear that the risk of thromboembolic complications varies greatly according to the condition for which splenectomy is performed. We think that the occurrence of postsplenectomy thrombocytosis that can reach extreme levels can only add to those risks of thromboembolism in patients with schistosomal portal hypertension.

Most thromboembolic complications occur 7-35 days after splenectomy⁶. This coincides with the period of RT in our case (day 8 to week 10). Our patient developed what we thought clinically as pulmonary embolism (PE) on day seven and hence we started heparin treatment. The score for high clinical suspicion of PE is (3), together with the tachycardia (1.5), and the history of immobilization (1.5) give a score of 6 on Well's criteria¹⁴. In addition the D-dimer was more than seven times higher than the normal. Unfortunately we were not able to do further investigations such as pulmonary angiography CT scan, or a ventilation perfusion scan to prove PE. The patient luckily responded

promptly to the anticoagulant treatment within six days. The patient received a small dose of aspirin thereafter for about two months. The omission of warfarin and the use of aspirin instead occurred unintentionally. Although Poullis suggested that aspirin in combination with heparin could have beneficial effects¹⁵, there is no published evidence to support the use of aspirin in acute pulmonary embolism¹⁶. This case suggests a probable benefit when the cause of embolism is thrombocytosis. However, this assumption needs further study.

The finding that RT and the extreme peak of rise of platelets occurred after the 7th day postoperatively and at day 14, respectively, should have important implications for planning the management and follow up of such patients. This is because thrombocytosis occurs after patients with uncomplicated splenectomy have been discharged from hospital⁹. We, therefore, add our voice to those who recommend that post-splenectomy patients should be given anti-platelet prophylaxis, and have their platelets monitored. The regime we propose is aspirin, after the 7th postoperative day until the platelet count returns to normal.

Some of our Sudanese patients may travel back to their far away homes where medical facilities may not be easily available. It is therefore important that both surgeons and patients know about the risk of thromboembolism after splenectomy. Patients should be followed up for two weeks at least after discharge, at the outpatient department. Those patients who need to travel away should be strongly advised to stay within a reasonable distance from a health facility until given the clear, and this is when their platelets return to normal.

RBCs

Unlike the change (increase) in the platelets and WBC count following splenectomy, there was no erythrocytosis (or polycythaemia). On the contrary, the anaemia persisted for almost a month (27 days) after the splenectomy. Our finding of 'persistent anaemia' following splenectomy has been noticed a long time before¹⁷. The patient's HGB was 7.3 g/dl

48hrs and 72hrs after the operation despite blood transfusion of four units during and in the immediate postoperative period. We gave her two more units to get her HGB at or just above 10 g/dl. This was achieved on the 5th post-op day (10.2g/dl). From that day the HGB corrected itself gradually to 12 gm/dl by the 27th post-op day without further blood transfusions or iron tablets. It has to be mentioned that there are no National Sudanese Haemoglobin Reference values. It has been noticed that many Sudanese seem to lead normal life with lower HGB levels than the international reference range of 12-15gm/dl female, and 13-17 gm/dl male. The cause of this (quasi-anaemia) may be multifactorial. Malnutrition and chronic diseases such as schistosomiasis and malaria are but a few causes.

Other RBC indices such as HCT, MCH, MCHC, MCV showed a microcytic hypochromic picture in association with a low bone marrow iron. This confirms that the cause of the anaemia was hypersplenism. All of these returned to normal level after about a month postoperatively. The reason why erythrocytosis did not occur despite a hypercellular bone marrow is not known.

Relation between reactive thrombocytosis and iron deficiency anaemia:

Iron deficiency anaemia by itself is thought to be an important cause of reactive thrombocytosis¹⁸. Some authors, such as Hirch and Dacy, noted an apparent association of persistent anaemia and the late occurrence of thrombosis (months to years), and suggested that the persistent anaemia is the cause of thrombocytosis¹⁷. Our case showed, however, the co-existence of thrombocytopenia (not thrombocytosis) with iron deficiency anaemia for a long time before the splenectomy. This, together with the leukopenia, was attributed to hypersplenism. After splenectomy thrombocytosis appeared and reached extreme levels while the anaemia persisted and was only corrected partially by blood transfusion. The anaemia was fully corrected naturally after a month while the thrombocytosis persisted for about four months

postoperatively. This pattern does not support a causal relationship between iron deficiency anaemia and thrombocytosis. In addition, the finding of bone marrow hypercellularity explains the thrombocytosis as due to increased production of platelets. Alteration of the bone marrow megakaryocyte count in iron deficiency anaemia was mentioned in only two earlier reports^{19, 20}.

The absence of a causal relationship may explain the controversy in literature on the mechanism causing RT in iron deficiency anaemia, particularly regarding the role of erythropoietin, thrombopoietin, cytokines such as interleukin 6 and 11, and leukaemia inhibitory factor^{21, 22}. Unfortunately these tests were not available to us.

Cases of central retinal vein thrombosis, and carotid artery thrombosis were reported in patients with extreme thrombocytosis (not after splenectomy) and iron deficiency anaemia^{23, 24}. This further supports our proposal of using antiplatelet drugs during the period of thrombocytosis. We tend, nevertheless, to think and agree with Schilling et al that the persistent anaemia in the early postoperative period may be protective against the development of thrombosis²⁵. This anaemia is fortunate since there is usually an increased coagulability of blood and increased rigidity of red blood cells following splenectomy^{5, 12, 13}. The liability to thrombosis would have duplicated if there was erythrocytosis. The mechanism that orchestrates this anaemia to coincide with the period of extreme thrombocytosis (that ended at day 21) is, however, unknown.

The absence of a reactive increase in the RBCs (erythrocytosis/polycythaemia) after splenectomy is worth thinking about. It could suggest that the spleen itself might not be the major cause of the anaemia of 'hypersplenism'. Other factors may play a role, such as chronic infection. It could also suggest that the cytological destruction of RBCs by the spleen might not be the only way the spleen regulates RBC count. The spleen might also have an influence on erythropoiesis via a humoral factor. Further

studies are needed to define the role of spleen in the anaemia of portal hypertension.

WBCs

Leukocytosis occurred almost immediately from $1.3 \times 10^9/l$ to 4.8×10^9 after the ligation of the splenic artery at splenectomy. The count reached $17 \times 10^9/l$ after 24 hours postoperatively. There was no evidence of infection to which this rise could be attributed to. It can only be explained by the splenectomy itself.

The patient postoperative course was complicated by malaria infection diagnosed by the ICT test on the 3rd postoperative day. The WBC count was $14 \times 10^9/l$. The response to the antimalarial treatment was good and by day five the count was 12.5. There was another peak on day seven when the WBC increased to $14.7 \times 10^9/l$. This is the time when pulmonary embolism was suspected but could not be proven. There was right-sided pleural effusion and raised JVP.

Relationship between platelets and WBCs

Some reports indicated that, after splenectomy for trauma, a platelet (PC)/WBC ratio below 20 on day five postoperatively, was a reliable marker of infection^{26, 27}. This was because a rise of WBC over $15 \times 10^9/l$ could markedly decrease the ratio.

Our findings, however, contradict this observation. The PC/WBC ratio stayed generally below 20 during the preoperative period and up to day five postoperatively, except at one and 2.5 hours after ligation of the splenic artery. Apart from malaria at day three postoperatively there was no evidence of infection during this period. The platelets increased so tremendously thereafter that the ratio was well above 20 from day six onwards despite the development of pleural effusion.

The plt/wbc ratio has, thus, not been a reliable evidence of the presence or absence of infection after splenectomy for portal hypertension. Clinicians have to rely on clinical symptoms and signs.

Conclusion:

This study provides data for the first time in Sudan on the long term haematological effects of splenectomy on patients with portal

hypertension. It has important clinical relevance as it provides evidence needed for discussing guidelines for management and follow up of these patients.

Blood elements undergo different changes post-splenectomy. While the platelet and white cells increase, the RBCs (and haemoglobin) stay below the normal level. The pattern and time of blood cell changes also differ. The spleen (and its absence) seems to affect blood cell lines differently.

Reactive thrombocytosis (RT) occurs following splenectomy in patients with portal hypertension. This phenomenon was noted from day seven till week 17, with extreme levels ($>1000 \times 10^9/l$) between days 11 and 19 postoperatively. It seems wise to monitor the platelet count after discharge of the patient from the hospital as this is the time when extreme thrombocytosis can occur. It may also be wise to give aspirin as a prophylaxis against the thrombocytosis from the 5th or 6th day postoperatively after the patient starts to take oral diet normally until the platelet count returns to normal.

On the other hand, there seems to be no need for blood transfusions or oral iron therapy after day seven post-splenectomy, as the anaemia will not respond and it will slowly correct itself before the end of the first month. The persistent anaemia after splenectomy in contrast to the RT may suggest that the spleen has a different effect on cell lines. Further studies are needed to re-investigate the role of the spleen in erythropoiesis.

References:

1. Lewis FM. The Spleen. In: Hoffbrand AV, Catovsky D, Tuddenham EG eds. Postgraduate Haematology. 5th Ed. Blackwell publishing, Oxford 2005: 364.
2. Traetow W D, Fabri PJ, Carey LC. Changing indications for splenectomy. Arch Surg. 1980;15(4):447-451.
3. Greer JP, Foerster J, Lukens JN, Rodgers GM, Paraskevas F, Glader B, eds. Wintrobe's Clinical Hematology, 11th ed. Philadelphia: Lippincott Williams & Wilkins, 1981:1128-1134.
4. Winslow ER, Brunt LM, Drebin JA et al. Portal vein thrombosis after splenectomy. Am J Surg 2002; 184(6): 631-635.

5. Stamou KM, Toutouzas KG, Kekis PB et al. Prospective study of the incidence and risk factors of postsplenectomy thrombosis of the portal, mesenteric, and splenic veins. *Arch Surg* 2006; 141(7):663–669.
6. Mohren M, Markmann I, Dworschak U et al. Thromboembolic complications after splenectomy for hematologic diseases. *American Journal of hematology* 2004; 76(2): 143-147.
7. Gaffari S, Pourafkari L. Acute myocardial infarction in a patient with post-splenectomy thrombocytosis: a case report and review of literature. *Cardiology Journal* 2010; 17(1): 79-82.
8. Eguchi A, Makoto Hashizume M, Kitano S et al. High Rate of Portal Thrombosis After Splenectomy in Patients With Esophageal Varices and Idiopathic Portal Hypertension. *Arch Surg*. 1991; 126(6):752-755.
9. Coon WW, Penner J, Clagett P et al. Deep Venous Thrombosis and Postsplenectomy Thrombocytosis. *Arch Surg* 1978; 13: 429-431.
10. Oida T, Kano H, Mimatsu K et al. Thrombocytosis following splenectomy: with or without additional organ resection. *Hepatology* 2012; 59(116):1033-5.
11. Canonico S, Sciaudone G, Santoriello A et al. Abstract: Blood coagulation changes in patients with post-splenectomy persistent thrombocytosis. *Chir Ital*. 2001; 53(4):537-42.
12. Cray SE, Buchanan GR. Vascular complications after splenectomy for hematologic disorders. *Blood* 2009; 114(14): 2861-68.
13. Robertson DA, Simpson FG, Losowsky MS. Blood viscosity after splenectomy. *Br Med J (Clin Res Ed)*. 1981; 283(6291):573-575.
14. Wells P S, Anderson D R, Rodger M et al. Excluding Pulmonary Embolism at the Bedside without Diagnostic Imaging: Management of Patients with Suspected Pulmonary Embolism Presenting to the Emergency Department by Using a Simple Clinical Model and D-Dimer. *Annals Intern Med* 2001;135:98-107.
15. Poullis M. Aspirin for the treatment of pulmonary embolism: vasoconstriction versus physical obstruction. *Am Heart J* 2000;140: E22.
16. Lee C, Ferguson C. Aspirin in the treatment of acute pulmonary embolism. *Best Evidence Topic Reports (BETs)*. Carley SD (Editor). Downloaded from emj.bmj.com on December 9, 2012. *bmj*: p365.
17. 17.J. Hirsh, J. V. Dacie. Persistent Post-Splenectomy Thrombocytosis and Thromboembolism: A Consequence of Continuing Anaemia. *British Journal of Haematology* 1966; 12 (1):44-53.
18. Dan K. Thrombocytosis in iron deficiency anaemia. *Internal Medicine* 2005; 44 (10): 1025-1026.
19. Kasper CK, Whissel DY, Wallerstein RO. Clinical aspects of iron deficiency. *JAMA* 1965: 191; 359-363.
20. Alexander MB. Iron deficiency anaemia, thrombosis, and cerebrovascular accidents. *South Med J* 1983;76: 662-663.
21. Bilic E, Bilic E. Amino acid sequence homology of thrombopoietin and erythropoietin explain thrombocytosis in children with iron deficiency anaemia. *J PedHematolOncol* 2003; 25:675-676.
22. Geddis AE, Haushansky K. Cross reactivity between erythropoietin and thrombopoietin at the level of mpl does not account for the thrombocytosis seen in iron deficiency. *J PedHematolOncol* 2003;25:919-920.
23. Nagai T, Kumatsu N, Sakata Y et al. Iron deficiency anaemia with marked thrombocytosis complicated by central retinal vein thrombosis. *Intern Med*. 2005; 44: 1090-1092.
24. Akins PT, Glenn S, Nemeth PM et al. Carotid artery thrombus associated with severe iron-deficiency anaemia and thrombocytosis. *Stroke* 1996; 27: 1002-1005.
25. Schilling RF, Gangnon RE, Traver M. Arteriosclerotic events are less frequent in persons with chronic anemia: evidence from families with hereditary spherocytosis. *Am J Hematol*. 2006; 81(5):315-317.
26. Toutouzas KG, Velmahos GC, Kaminski A et al. Leukocytosis after posttraumatic splenectomy: a physiologic event or sign of sepsis? *Arch Surg*. 2002; 137(8):924-8.
27. Weng J, Brown CV, Rhee P et al. White blood cell and platelet counts can be used to differentiate between infection and the normal response after splenectomy for trauma: prospective validation. *J Trauma*. 2005 Nov; 59(5):1076-80.