

Cyclops lesion of the knee

R de Villiers (MB ChB, MMed (RadD))¹
D Hoffman (MB ChB, FCS (Orthop)) SA²

¹Radiologist in private practice (Drs van Wageningen and Partners), Somerset West, and Honorary Consultant, Department of Radiology, Tygerberg Hospital, University of Stellenbosch

²Orthopaedic surgeon in private practice, Vergelegen Medi Clinic, Somerset West

Introduction

A 30-year-old man presented with knee pain 9 months post-arthroscopic autograft repair of a ruptured anterior cruciate ligament.

Case report

Clinically there was an effusion and tenderness over the lateral joint line. Knee extension was also limited. Magnetic resonance imaging (MRI) of the left knee was requested which showed a PD (proton density) iso-intense, T2 mildly hyperintense, non-enhancing, well-circumscribed soft-tissue mass protruding anteriorly between the tibio-femoral joint-

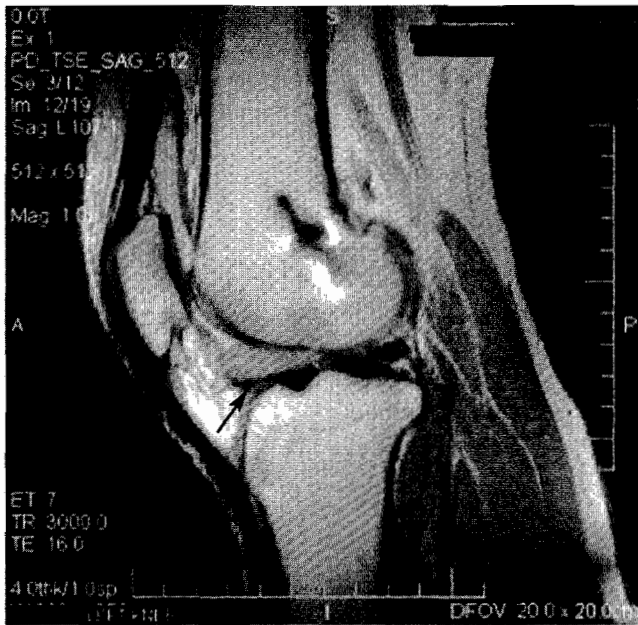

Fig. 1. Sagittal MRI knee proton-density Cyclops lesion.

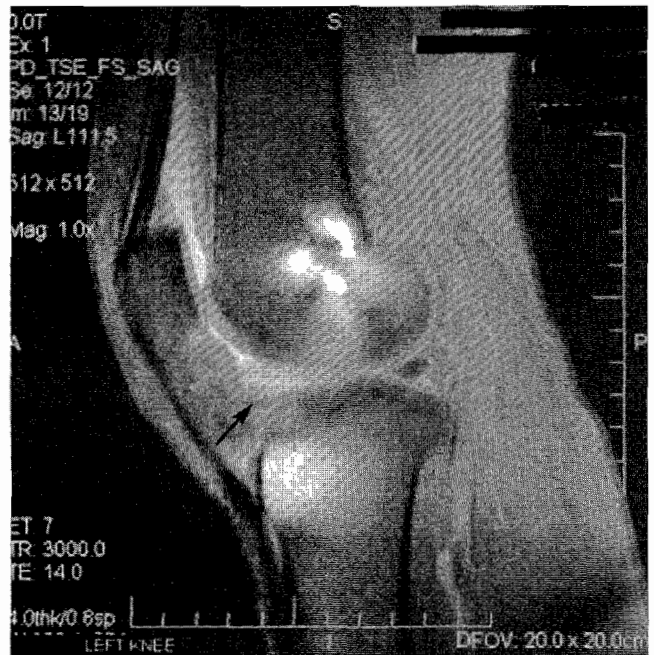

Fig. 2. Sagittal MRI knee PD fat-saturation Cyclops lesion.

space (Figs 1 and 2). The reconstructed graft was intact and no meniscal tear was present. A moderately sized effusion was present.

The orthopaedic surgeon proceeded to arthroscopy. A

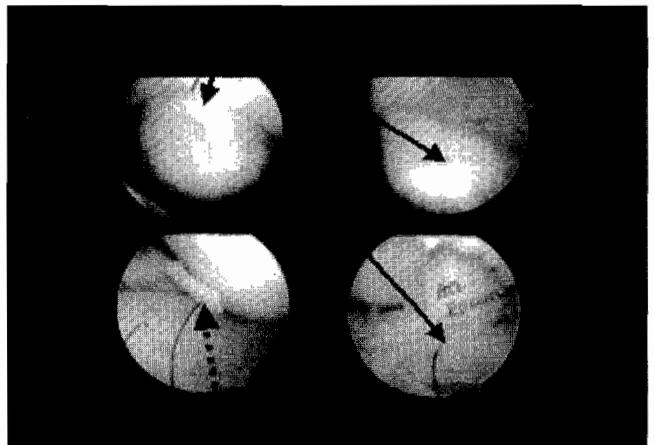


Fig. 3. Arthroscopic findings of Cyclops lesion (black arrow) and cartilaginous loose body (dotted arrow).

CORRESPONDENCE:

R V P de Villiers
PO Box 317
Somerset West
7129
Tel: 021-851 5545
Fax: 021-852 2697
E-mail: richard.devilliers@email.mediclinic.co.za

large Cyclops lesion was removed arthroscopically and tissue was sent for histological examination (Fig. 3). A loose intra-articular chondral fragment was also removed. Synovitis was also present in the lateral gutter and the anterior compartment. The anterior cruciate ligament graft was revascularised and appeared to be normal. Routine postoperative mobilisation was prescribed.

Histology of the specimen showed fibrocartilagenous tissue consistent with a Cyclops lesion.

Follow-up after 1 month showed significant improvement. There was no residual joint effusion and there was full knee extension.

Discussion

Clinical findings suggestive of roof impingement are: (i) knee joint effusion; (ii) extension deficit; (iii) recurrent instability; (iv) anterior knee pain; and (v) a combination of these findings. When loss of full extension persists for 2 months after anterior cruciate disruption despite aggressive rehabilitation, presence of a Cyclops lesion should be considered.⁴ A cyclops lesion may develop from the residual anterior cruciate ligament stump left at arthroscopic reconstruction or may develop from a minor, primarily torn, non-operated anterior cruciate ligament tear.^{4,9}

Arthroscopic patterns of graft injury associated with roof impingement include the development of fibrocartilagenous nodule or Cyclops lesion anterior to the distal third of the anterior cruciate ligament, graft fracture bundles of the graft, guillotined fibres at the entrance to the notch, parallel fragmentation of the graft fibres (lax bundles), and the extrusion or moulding of the graft at the distal end of the notch.^{8,10} The localised fibrocartilagenous nodule or Cyclops lesion may limit knee extension after anterior cruciate ligament reconstruction.

MRI is a special investigation which allows the assessment of: (i) tunnel position and alignment; (ii) graft integrity; (iii) the menisci for possible re-tear or extension of previous tears; and (iv) joint for scar tissue and cartilaginous bodies either loose or fixed.⁶ The bony tunnel houses the graft and the position and alignment of the tunnel is important to demonstrate the positioning of the graft. With cruciate ligament injury there is often an associated meniscal tear or cartilaginous injury.

The lesion shows low to intermediate signal intensity on T1 and T2 fast spin echo images and is best visualised in the sagittal plane between the leading edge of the distal cruciate ligament graft and Hoffa's fat pad.^{3,5,7,8} The sensitivity and

specificity and accuracy of revealing a Cyclops lesion on MR imaging were 85.0%, 84.6% and 84.8% respectively using arthroscopy as the gold standard.¹

Histologic examination of the excised nodules show a fibroelastic connective tissue proliferation, thromboangiitis, and areas of necrotic bone and foreign body giant cell granulomas.⁹

Conclusions

In patients presenting with a loss of knee extension after anterior cruciate ligament reconstruction, a large amount of thick, immobile scar tissue may be found immediately anterior to the anterior cruciate ligament. This is consistent with a Cyclops lesion.⁵ The intercondylar notch frequently has to be enlarged by removing scar tissue and bony osteophytes. A multifactorial pathogenesis is most likely responsible for the development of the Cyclops lesion. The fibrocartilagenous nodule (Cyclops lesion) is a natural fibroproliferative tissue process originating either from drilling debris from the tibial tunnel or from remnants of the anterior cruciate ligament stump and, more rarely, from broken graft fibres. Sometimes, when the graft is malpositioned, the scar tissue can result from repeated graft impingement on the notch at terminal extension.²

REFERENCES

1. Bradley DM, Bergman AG, Dillingham MF. MR imaging of Cyclops lesions. *Am J Roentgenol* 2000; **174**: 719-26.
2. Delince P, Krallis P, Descamps PY, Fabeck L, Hardy D. Different aspects of the Cyclops lesion following anterior cruciate ligament reconstruction: a multifactorial etiopathogenesis. *Arthroscopy* 1998; **14**: 869-76.
3. Jacobson JA, Lenchik L, Ruhoy MK, Schweitzer ME, Resnick D. MR imaging of the infrapatellar fat pad of Hoffa. *Radiographics* 1997; **17**: 675-91.
4. McMahon PJ, Dettling JR, Yocum LA, Glousman RE. The Cyclops lesion: a cause of diminished knee extension after rupture of the anterior cruciate ligament. *Arthroscopy* 1999; **15**: 757-61.
5. Nuccion SL, Hame SL. A symptomatic cyclops lesion 4 years after anterior cruciate ligament reconstruction. *Arthroscopy* 2001; **17**(2): E8.
6. Olson PN, Rud P, Griffiths HJ. Cyclops lesion. *Orthopedics* 1995; **18**: 1041, 1044-5.
7. Recht MP, Piraino DW, Cohen MA, Parker RD, Bergfeld JA. Localized anterior arthrofibrosis (Cyclops lesion) after reconstruction of the anterior cruciate ligament: MR imaging findings. *Am J Roentgenol* 1995; **165**: 383-5.
8. Stoller DW, Cannon WD, Anderson LJ. *MRI in Orthopaedics and Sports Medicine*. 2nd ed. Philadelphia: Lippincott-Raven, 1997: 340.
9. Tonin M, Saciri V, Veselko M, Rotter A. Progressive loss of knee extension after injury. Cyclops syndrome due to a lesion of the anterior cruciate ligament. *Am J Sports Med* 2001; **29**: 545-9.
10. Watanabe BM, Howell SM. Arthroscopic findings associated with roof impingement of an anterior cruciate ligament graft. *Am J Sports Med* 1995; **23**: 616-25.