


CASE REPORT

A diagnostic dilemma for a common but not-so-typical street pesticide

F Uys,¹ MB ChB, DA ; M O'Neill,¹ MB ChB, FCA; Z Farina,^{2,3} MB ChB, FCA; J Belford,¹ MB ChB, DA

¹ Department of Anaesthesia and Critical Care, Harry Gwala Regional Hospital, Pietermaritzburg, South Africa

² Head, Clinical Department: Anaesthesia and Critical Care, Greys Hospital, Pietermaritzburg, South Africa

³ Honorary lecturer, Department of Anaesthesia and Critical Care, University of KwaZulu-Natal, Pietermaritzburg, South Africa

Corresponding author: F Uys (fuys24@gmail.com)

The illegal practice of combining organophosphates (OPs) with other compounds such as carbamates and pyrethroids, creating 'street pesticides', is common in South Africa. These agents contain mostly unknown quantities of unregulated toxins and contribute to atypical and unpredictable clinical presentations following human ingestion. We present such a case in a patient with intentional rodenticide ingestion. The initial presentation in the emergency department was a classic cholinergic toxidrome, and clinical resolution was achieved after provision of atropine. This was followed 12 hours later by an acute decompensation resulting from an apparent sympathetically driven episode of autonomic instability and acute pulmonary oedema requiring immediate respiratory and haemodynamic support. In our discussion, we explore this secondary decompensation and suggest various pathophysiological explanations for this atypical clinical course following what had appeared to be OP poisoning. The patient was discharged home after a total of 6 days in hospital.

S Afr Med J 2023;113(2):57-60. <https://doi.org/10.7196/SAMJ.2023.v113i2.16832>

Organophosphate poisoning (OPP) represents a major healthcare burden in South Africa (SA) and is probably the most common cause of admissions to intensive care units (ICUs) due to poisoning from drugs and toxin ingestion.^[1] In the developing world, including SA, commercial pesticides may be unaffordable for much of the population. 'Street pesticides' are illegally compounded from agricultural pesticides and other compounds. These are decanted and sold in unlabelled bottles for unregistered uses.^[2,3] The variable composition contributes to unpredictable clinical presentations.^[1-6]

Organophosphorus compounds irreversibly bind to acetylcholinesterase (AChE), rendering this enzyme non-functional. AChE is the enzyme responsible for hydrolysis of acetylcholine (ACh), and inhibition leads to an overabundance of ACh at the neuronal synapses and the neuromuscular junction. The consequence of this is overstimulation of muscarinic and nicotinic receptors and therefore upregulation of the parasympathetic, and to a lesser extent sympathetic, nervous systems.^[7,8] The return of enzyme function is entirely dependent on the synthesis of new enzyme units.^[4,8] Carbamates are another class and are chemically similar to pure organophosphates (OPs). Ingestion results in reversible AChE inhibition, and the enzyme regains its function in ~48 hours, resulting in a short-lived clinical syndrome.^[4]

The nature of the clinical manifestations depends on the predominant site of overstimulation. In most cases this is muscarinic receptor stimulation, as the parasympathetic nervous system is particularly dependent on ACh regulation.^[7] Common muscarinic side-effects include miosis, bronchorrhoea, diarrhoea, hypotension and bradycardia, while the typical nicotinic features include fasciculations, hypertension, and occasionally episodes of tachyarrhythmias.^[1,9] The mainstay of treatment is atropine, a muscarinic antagonist, and pralidoxime, an AChE-reactivating agent.^[7,8] Pralidoxime is not available in SA.

In this case study, we explore a scenario of autonomic instability triggering clinical deterioration.

Case presentation and management

A timeline of the clinical presentation is summarised in Fig. 1.

A 30-year-old woman with no known comorbidities presented to the emergency department at Harry Gwala Regional Hospital, Pietermaritzburg, SA, with her partner. Her partner provided the history of intentional ingestion of a single sachet of an unknown rat poison ~2 hours prior to arrival.

Acute presentation consisted of a decreased level of consciousness, Glasgow Coma Scale (GCS) 6/15 (M4V1E1), pinpoint pupils, urinary incontinence, excessive respiratory secretions, sinus bradycardia of 25 beats per minute (bpm), and severe hypoxia (oxygen saturation of 45%). A clinical diagnosis of a cholinergic toxidrome secondary to OP/carbamate poisoning was made.

Emergency management was initiated by intubation via a modified rapid-sequence induction using ketamine 100 mg and rocuronium 70 mg. Atropinisation was achieved via incremental doses of atropine to a total dose of 30 mg. The end-point target was the clearing of respiratory secretions. After atropinisation was achieved, an atropine infusion was initiated at 10% of the atropinisation dose (3 mg/h). She was admitted to the ICU for continued atropine infusion via a central venous catheter, ventilatory support, and cardiovascular monitoring including invasive blood pressure monitoring.

In the ICU, the atropine infusion was gradually titrated down to a target heart rate of 80 - 100 bpm. The infusion was discontinued 30 hours after initiation. There was resolution of the bronchorrhoea, the GCS improved to 10T (M6E4VT), and the pupil size normalised. She was extubated 4 hours after discontinuation of the atropine infusion. The extubation was uneventful. Intravenous fluid administration was maintained at 10 mL/h of Ringer's lactate. Shortly after extubation, she was noted to be alert and her vital signs were within normal limits. Urine output of 0.7 mL/kg/h was recorded. Twelve hours after extubation, she became increasingly distressed over the course of 30 minutes.

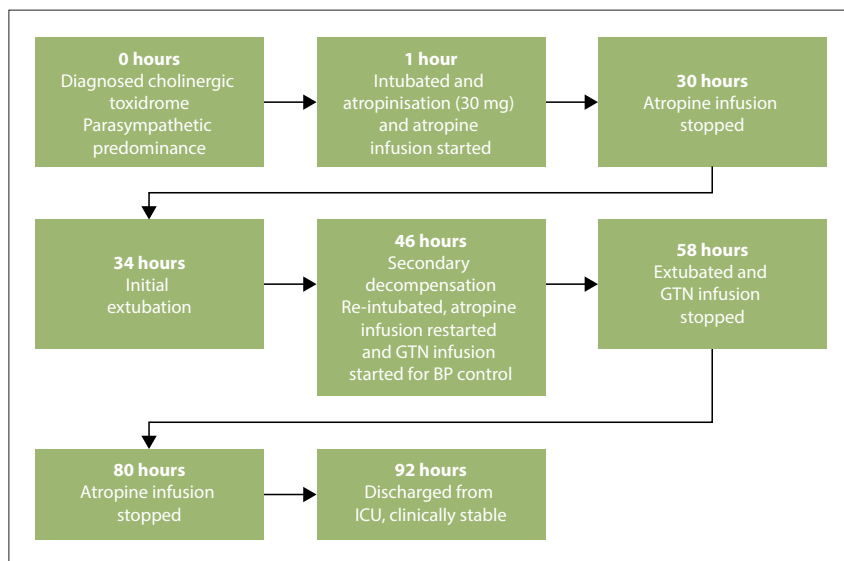


Fig. 1. Timeline of presentation (GTN = glyceryl trinitrate; BP = blood pressure; ICU = intensive care unit).

Secondary decompensation

Twelve hours after extubation, the patient complained of acute-onset dull left-sided chest pain with associated difficulty in breathing. A 3-lead electrocardiogram (ECG) showed sinus rhythm with no ST-segment changes. An informal point-of-care ultrasound scan revealed uniformly appropriate systolic ventricular function with multiple, bilateral pathological B-lines on lung ultrasound suggestive of pulmonary oedema. When the patient was laid supine, she became diaphoretic and developed acute respiratory distress with features of autonomic instability. Her respiratory rate was recorded at 50 breaths per minute. This was combined with copious pink frothy secretions and diffuse bilateral ronchi with no audible wheeze. She was unable to verbalise because of the “air hunger” she was experiencing. Arterial blood gas analysis at this time revealed an uncompensated respiratory alkalosis (pH 7.57, partial pressure of carbon dioxide 2.6 kPa, partial pressure of oxygen 8.7 kPa, bicarbonate 20 mEq/L, base excess 2.6 mmol/L) on 60% oxygen via a non-rebreather face mask. Sustained severe hypertension (mean arterial pressures 120 - 150 mmHg), tachycardia (120 - 150 bpm), bilateral pupillary dilation (>8 mm) and diaphoresis were noted. Neurological examination revealed no obvious cranial nerve or demonstrable neurological fallout. Normal renal function had been recorded in the ICU prior to this event. Importantly, the patient and family members did not report any pre-existing endocrine, cardiac or renal conditions.

The differential diagnoses at the time consisted of a reoccupation of muscarinic

and nicotinic ACh receptors by excessive ACh with a cholinergic toxidrome, or a sympathetically driven acute pulmonary oedema of unknown origin.

Based on the differential diagnoses, this secondary decompensation was managed by an immediate bolus of glycopyrrolate 0.4 mg as an antimuscarinic and antisialagogue prior to securing the airway. She was re-intubated via a rapid-sequence induction using propofol 130 mg and rocuronium 70 mg. Positive-pressure ventilation using pressure-control ventilation was recommenced with the following settings: inspiratory pressure 16 cm H₂O to generate tidal volumes 350 - 380 mL, positive end-expiratory pressure 12 cm H₂O, and respiratory rate 16 breaths per minute. The atropine infusion was re-initiated at 0.5 mg/h in order to account for the possible reoccupation of muscarinic receptors. Severely elevated blood pressure was controlled using a 1 mg/mL nitroglycerine infusion at 1 - 3 mg/h titrated to target pressures <160/110 mmHg.

Outcome and follow-up

Subsequent to these initial measures, there was a steady improvement in lung compliance, respiratory secretions and blood pressure, as well as normalisation of pupil size, with successful re-extubation 12 hours later. The nitroglycerine infusion was weaned and stopped after extubation. The atropine infusion was gradually weaned and stopped 24 hours after secondary initiation. The patient was discharged from the unit 24 hours after extubation and 12 hours after discontinuation of atropine. She was subsequently discharged from hospital after 2 days of observation in the ward with

no further intervention required. This case was notified as mandated by the National Department of Health (National Health Act 61 of 2003).^[3]

Discussion

This is an unusual case of OPP and to our knowledge not a common clinical course, which presented us with a diagnostic dilemma. We reviewed the AfriTox database^[10] and were unable to find our patient’s clinical presentation described under OP poisoning. In this discussion, we attempt to produce five potential pathophysiological explanations for the subsequent autonomic instability with marked sympathetic signs.

The traditional approach to clinical features in acute OP poisoning has centred on receptor-specific effects on muscarinic, nicotinic and central nervous system (CNS) receptors.^[11] A systematic review by Peter *et al.*^[11] concerning the presentation of OPP demonstrated that muscarinic symptoms and signs were the most frequent (84%), followed by CNS (78%) and nicotinic (17%). We most often focus on the parasympathetic overstimulation, and the clinical toxidrome is recognised by use of the well-known acronym ‘SLUDGE’ (salivation, lacrimation, urination, diarrhoea, gastric dysfunction and emesis), which are the symptoms driven by muscarinic receptor stimulation.

Irreversible binding of OP to AChE in the cholinergic synapses in the CNS and peripheral nervous system results in high concentrations of ACh in the synaptic clefts that cause initial excessive stimulation and, later, blockade of synaptic transmission.^[11] Symptoms produced by OPP may well vary depending on the predominant receptor overstimulation by the abundance of ACh (Table 1).

1. Sympathetic overstimulation with subsequent pulmonary oedema

The ACh binds disproportionately and unpredictably to nicotinic and muscarinic receptors. The initial presentation to the emergency unit was typical of muscarinic overstimulation and was appropriately managed with atropine. The excessive ACh molecules bind to the muscarinic receptors producing overstimulation, which may paradoxically result in inactivation of these receptors.^[7,10-12] Furthermore, the abundant ACh may also overstimulate preganglionic sympathetic nicotinic receptors (Table 1), triggering upregulation of the sympathetic effects of various end-organs, resulting in hypertension, diaphoresis, mydriasis and tachycardia. This sympathetic response has

Table 1. Effects of excessive acetylcholine on receptors

	Parasympathetic	Sympathetic	Somatic	CNS
Preganglionic neurotransmitter and receptor	Acetylcholine Nicotinic receptor	Acetylcholine Nicotinic receptor	Acetylcholine Nicotinic receptor	Acetylcholine Nicotinic receptor
Ganglia and post-ganglionic receptors	Muscarinic receptor	Muscarinic receptor Adrenal medulla Nicotinic receptor Sympathetic ganglia	Neuromuscular junction	Neurotransmission
Post-ganglionic neurotransmitter	Acetylcholine	Acetylcholine Epinephrine Noradrenaline	Acetylcholine	Acetylcholine
End-organ effects	Bradycardia Bronchoconstriction Miosis Smooth-muscle contraction	Diaphoresis Mydriasis Tachycardia Hypertension Bronchodilation	Fasciculations Weakness	Agitation Confusion Coma Seizures Respiratory depression

CNS = central nervous system.

been postulated to be due to overwhelming cholinergic effects on the CNS, the sympathetic ganglionic synapses, or the adrenal medulla with the resultant release of catecholamines.^[11-14]

The patient's deterioration after admission to the ICU was associated with features suggestive of acute sympathetic overstimulation, which included diaphoresis, tachycardia, severe hypertension and mydriasis. This was followed by rapid respiratory decompensation, seemingly due to pulmonary oedema. Non-cardiogenic pulmonary oedema has been reported in multiple case reports.^[15,16] Rapid clinical improvement was seen after initiation of measures to reduce cardiac loading conditions, namely positive-pressure ventilation and nitroglycerine infusion. Although uncommon, hypertension, mydriasis and tachycardia have been described as presentations due to nicotinic stimulation by excessive ACh caused by OPP in a systematic review.^[11]

2. A combination of pyrethroid and OP intoxication leading to acute pulmonary oedema

Pyrethroids are ion channel toxins (predominantly sodium channels). Disruption of voltage-sensitive sodium channel function keeps these channels open for prolonged periods, resulting in hyperexcitation of the entire nervous system.^[5,6,10,16] Pyrethroid insecticides are widely used. Illegal mixing of OPs and pyrethroids in marketed agricultural insecticides is becoming prevalent in developing countries. Toxicity is divided into type 1 and 2 based on clinical presentation. Type 1 syndrome presents as a reflex hyperexcitability and fine tremor. Type 2 syndrome is characterised by choreoathetosis, salivation, seizures and potent sympathetic activation.^[5,6,9]

Pyrethroid toxin in isolation is not toxic to humans because of the efficient hydrolysis by AChE, but in combination with OP, which inhibits AChE, it causes potent sympathetic surges and subsequent pulmonary oedema.^[5,6,17] In a case series of eight patients in Nepal with a confirmed combination of pyrethroid and OPP, Tripathi *et al.*^[6] describe severe pulmonary oedema related to the pyrethroid-induced neuroexcitation and sympathetic surge. Pyrethroid toxin is a common additive in SA pesticides and could be implicated in such atypical presentations.

3. Cholinergic toxicity with bronchorrhoea

After discontinuation of the atropine infusion, the ACh molecules could potentially have rebounded to the muscarinic receptors, leading to excessive bronchorrhoea and respiratory compromise due

to cholinergic toxicity. This patient had no features of cholinergic toxicity other than those listed during the second decompensation.

4. Intermediate syndrome

Intermediate syndrome is caused by excessive nicotinic stimulation due to excess ACh. The onset is usually 1 - 5 days after symptom resolution. Neurological findings include neck flexion weakness, decreased deep-tendon reflexes, cranial nerve abnormalities, proximal muscle weakness and respiratory insufficiency. Our patient did not present with these neurological symptoms and had a rapid recovery. Intermediate syndrome generally requires 2 - 3 weeks of mechanical ventilation.^[7,10]

5. Drug error (excessive atropine with anticholinergic toxidrome) or excessive intravenous fluid administration

Hypertension, mydriasis and tachycardia would fit with this anticholinergic syndrome. Of note, atropine was discontinued 12 hours prior to her secondary decompensation, and she received low infusion rates of intravenous fluids.

Study limitations

We acknowledge that the following could have aided in our differential diagnosis at the time:

- Red blood cell AChE levels, to confirm the diagnosis of OP poisoning.
- A 12-lead ECG and formal echocardiography by an accredited, experienced practitioner might have identified structural cardiac abnormalities that could have contributed to the clinical course.
- A chest radiograph at the time of presentation, to exclude or confirm pulmonary oedema.
- Analysis of the sample of toxin ingested, to identify compounds that could account for the presentation.

Teaching points

- Unpredictable quantities of toxins are found in a variety of street pesticides that are sold illegally and are unregulated in SA. As illegal mixing of compounds in insecticides is becoming more prevalent, more cases of mixed poisoning will occur and could lead to a variety of clinical presentations.
- Both muscarinic and nicotinic receptors may be stimulated. This initial action on the receptors is primary stimulation, followed by inhibition (blockage) of the receptor function.

- Owing to the commonality in OPP presentations, triggering the well-known 'SLUDGE' symptoms, cholinergic poisoning has become synonymous with parasympathetic symptoms. We hope to have demonstrated, with our clinical case and the pathophysiology discussed, that this pathway is more complicated because of unpredictable binding of ACh to nicotinic and muscarinic receptors.
- Variable sympathetic and parasympathetic symptoms may be present depending on the predominant receptor bound, the action on that receptor (inhibited or stimulated), and the type or mixture of compounds ingested.

Declaration. None.

Acknowledgements. None.

Author contributions. FU designed the case report with the input of MN. FU collected the data and conducted the literature review. FU wrote the case report, which was critically reviewed and edited by MN and ZF. ZF and JB reviewed additional literature and edited the manuscript. FU designed the figure and the table.

Funding. None.

Conflicts of interest. None.

1. Omar S, Bahemia IA, Toerien L, San Pedro KM, Khan AB. A retrospective comparison of the burden of organophosphate poisoning to an intensive care unit in Soweto over two separate periods. *Afr J Emerg Med* 2021;11(1):118-122. <https://doi.org/10.1016/j.afjem.2020.09.007>
2. Rother H-A. Falling through the regulatory cracks: Street selling of pesticides and poisoning among urban youth in South Africa. *Int J Occup Environ Health* 2010;16(2):183-194. <https://doi.org/10.1179/107735210799160336>

3. Rother H-A. Improving poisoning diagnosis and surveillance of street pesticides. *S Afr Med J* 2012;102(6):485-488. <https://doi.org/10.7196/SAMJ.5838>
4. Bruins J, Menezes CN, Wong ML. Organophosphate poisoning at Chris Hani Baragwanath Academic Hospital 2012 - 2015. *Afr J Thorac Crit Care Med* 2019;25(3). <https://doi.org/10.7196/AJTCCM.2019.v25i3.001>
5. Ray DE, Forshaw PJ. Pyrethroid insecticides: Poisoning syndromes, synergies, and therapy. *J Toxicol Clin Toxicol* 2000;38(2):95-101. <https://doi.org/10.1081/ct-100100922>
6. Tripathi M, Pandey R, Ambesh SP, Pandey M. A mixture of organophosphate and pyrethroid intoxication requiring intensive care unit admission: A diagnostic dilemma and therapeutic approach. *Anesth Analg* 2006;103(2):410-412. <https://doi.org/10.1213/01.ane.0000222470.89210.5a>
7. Bird S, Traub SJ, Grayzel J. Organophosphate and carbamate poisoning. UpToDate, 2022. <https://www.uptodate.com/contents/organophosphate-and-carbamate-poisoning?search=organophosphate> (accessed 9 November 2021).
8. Eddleston M, Buckley NA, Eyer P, Dawson AH. Management of acute organophosphorus pesticide poisoning. *Lancet* 2008;371(9612):597-607. [https://doi.org/10.1016/S0140-6736\(07\)61202-1](https://doi.org/10.1016/S0140-6736(07)61202-1)
9. Aardema H, Meertens JHJM, Ligtenberg JJM, Peters-Polman OM, Tulleken JE, Zijlstra JG. Organophosphorus pesticide poisoning: Cases and developments. *Neth J Med* 2008;66(4):149-153.
10. AfriTox. AfriTox poisons information database 2022. <http://www.afritox.co.za/> (accessed 21 January 2022).
11. Peter JV, Sudarsan TI, Moran JL. Clinical features of organophosphate poisoning: A review of different classification systems and approaches. *Indian J Crit Care Med* 2014;18(11):735-745. <https://doi.org/10.4103/0972-5229.144017>
12. Karki P, Ansari JA, Bhandary S, Koirala S. Cardiac and electrocardiographical manifestations of acute organophosphate poisoning. *Singapore Med J* 2004;45(8):385-389.
13. Petroianu GA. Organophosphate poisoning: The lesser-known face of a toxidrome. *Eur J Emerg Med* 2005;12(2):102-103. <https://doi.org/10.1097/00063110-200504000-00013>
14. Brvar M, Chan MY, Dawson AH, Ribchester RR, Eddleston M. Magnesium sulfate and calcium channel blocking drugs as antidotes for acute organophosphorus insecticide poisoning – a systematic review and meta-analysis. *Clin Toxicol (Phila)* 2018;56(8):725-736. <https://doi.org/10.1080/15563650.2018.1446532>
15. Kass R, Kochar G, Lippman M. Adult respiratory distress syndrome from organophosphate poisoning. *Am J Emerg Med* 1991;9(1):32-33. [https://doi.org/10.1016/0735-6757\(91\)90009-9](https://doi.org/10.1016/0735-6757(91)90009-9)
16. Saadeh AM, Al-Ali MK, Farsakh NA, Ghani MA. Clinical and sociodemographic features of acute carbamate and organophosphate poisoning: A study of 70 adult patients in north Jordan. *J Toxicol Clin Toxicol* 1996;34(1):45-51. <https://doi.org/10.3109/15563659609020232>
17. Basrai Z, Koh C, Celedon M, Warren J. Clinical effects from household insecticide: Pyrethroid or organophosphate toxicity? *BMJ Case Rep* 2019;12(11):e230966. <https://doi.org/10.1136/bcr-2019-230966>

Accepted 3 October 2022.