

Erosions of the Petrous Temporal Bone

B. L. WOLFOWITZ, A. SOLOMON

SUMMARY

Diseases of the ear, nose, and throat which produce erosion of the petrous temporal bone, are rare. A classification of such lesions is proposed, and the incidence and aetiology of these lesions in South African Blacks is discussed.

S. Afr. Med. J., 48, 1799 (1974).

Destructive lesions of the petrous temporal bone are rare. This article presents the incidence and aetiology of such lesions in the South African Black population; it is a review based on patients treated in the Department of Otorhinolaryngology, Baragwanath Hospital, during the years 1968 - 1972.

CLASSIFICATION OF LESIONS

The following classification of erosive lesions affecting the petrous bone is proposed:

Congenital

Primary cholesteatoma of the cerebellopontine angle.

Acquired

Erosion by epithelium: keratosis obturans, and cholesteatoma.

Erosion by infection: acute mastoiditis, and apical petrositis.

Erosion by neoplasms: those which arise in the petrous bone include carcinoma of the middle-ear cleft; glomus tympanicum and glomus jugulare; rhabdomyosarcoma; meningioma; plasmacytoma; giant-cell tumour; adenocarcinoma; neurofibrosarcoma; melanoma; and acoustic neuroma and facial-nerve neuroma.

Malignant neoplasms which invade from adjacent structures include brain tumours; tumours of the nasopharynx; tumours of the parotid gland; tumours of the paranasal sinuses; and tumours of the surrounding skin.

Metastatic tumours include those from the breast, prostate, kidney, lung, and testis.

Erosion by cysts: mucocele of the sphenoid sinus and arachnoidal cyst.

Department of Otorhinolaryngology, Baragwanath Hospital and University of the Witwatersrand, Johannesburg

B. L. WOLFOWITZ, F.R.C.S.

A. SOLOMON, M.B. CH.B., DIP. MED., M.MED.

Date received: 13 March 1973.

Erosion by blood vessels: aneurysm of the internal carotid artery.

Erosion by bone disorders: fibrous dysplasia; Hand-Schüller-Christian disease; and hyperparathyroidism.

The clinical features and pathology of these conditions are beyond the scope of this article. The following discussion deals with the incidence of erosive lesions of the petrous bone in the South African Black population, and gives reports of rare cases of special interest.

EROSION BY EPITHELIUM

Cholesteatoma produces typical erosion of bone, whether it involves the middle-ear cleft, the external acoustic canal (keratosis obturans), the nasal cavity, or the deep recesses of the petrous bone, the primary epidermoid tumours reported by Cawthorne and Griffith.¹

We have not encountered a case of primary epidermoid cholesteatoma in Black patients. Cholesteatoma of the middle-ear cleft, however, is extremely common, and extensive destruction of the temporal bone and even the occipital bone, has not infrequently been observed. The following report documents a case of keratosis obturans, which is unusual in that the middle-ear cleft was eroded by a cholesteatoma in the external acoustic canal.

Case 1

A 45-year-old South African Black male presented with a history of left-sided deafness of several years' duration. The external acoustic canal was filled with cholesteatoma, and he had a severe left-sided conductive deafness (50 - 70 dB). X-ray films and tomograms of the temporal bone showed severe erosion of the anterior and posterior walls and floor of the external acoustic canal. The external canal was cleaned under general anaesthesia. The tympanic membrane, although intact, was retracted over the promontory. The posterior and superior walls of the external acoustic canal were eroded and the cholesteatoma extended into the antrum and attic. There were no bony sequestra. A facial nerve graft was placed over the exposed attic. The ossicles were not eroded. Postoperative audiometry showed an improvement of 30 dB in the conductive hearing loss.

Similar cases have been reported by Harpman,² Tumarkin,³ and Morrison.⁵ The mechanism of erosion of bone is not fully understood. Altman and Waltner⁴ postulated that the formation of a cholesteatoma in the external acoustic canal was the result of secondary ingrowth of stratified squamous epithelium into a cavity formed by sequestration of a superficial area of the bony wall. They regarded the cause of the necrosis as a circumscribed periostitis. Harpman⁷ drew attention to the association

between keratosis obturans, chronic sinusitis and bronchiectasis in many cases. He suggested an underlying causal defect in the mucous membrane of the sinuses, the lungs, and the surface epithelium. Link⁸ and Schröder⁹ raised the possibility that the embryological excavating activity of epithelium may continue into adult life, to result in the erosion by a cholesteatoma. There is evidence that proliferation of epithelium of the type found in the cholesteatoma matrix, with its deep rete pegs, active dermis and thick spinous cell layer, occurs only as the result of chronic irritation such as infection and moisture.¹⁰⁻¹³ McGuckin¹⁴ claimed that cholesteatoma does not cause dissolution of bone by pressure alone; he suggested that chemical or enzymatic factors derived from the breakdown of keratin might be involved.

EROSION BY INFECTION

Necrosis of bone is often part of the clinical picture of acute mastoiditis. Erosion of the petrous bone as a result of acute mastoiditis and acute petrositis is still common in South African Blacks. During the 5-year period 1968-1972, 47 cases of otitic meningitis were treated at Baragwanath Hospital, indicating the frequency of this disease. Twenty-seven of these cases have been reported,¹⁵ and many of them demonstrated extensive bony destruction of the temporal bone, and in some instances destruction of the occipital bone.

NEOPLASTIC EROSIONS

Table I gives the incidence, age, sex, clinical features and course of middle-ear tumours treated in the ENT Department, Baragwanath Hospital, from 1968 to 1972. The follow-up of these patients is given as the number of years of survival/the number of years during which the patient was regularly observed. This method is used because the follow-up of Black patients is often interrupted.

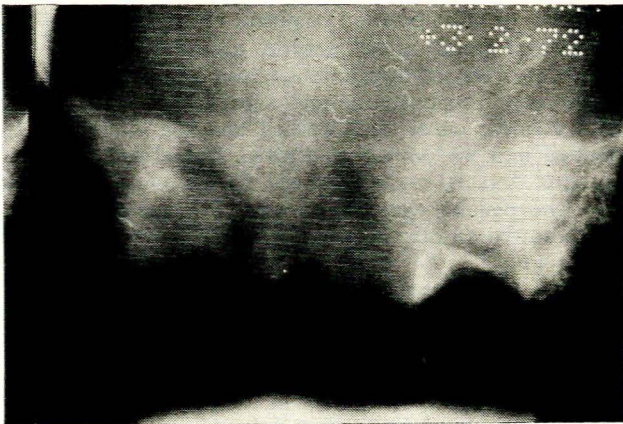


Fig. 1. Postero-anterior tomograph of temporal bones showing destruction of the right middle ear, inner ear and jugular bulb by glomus jugulare tumour.

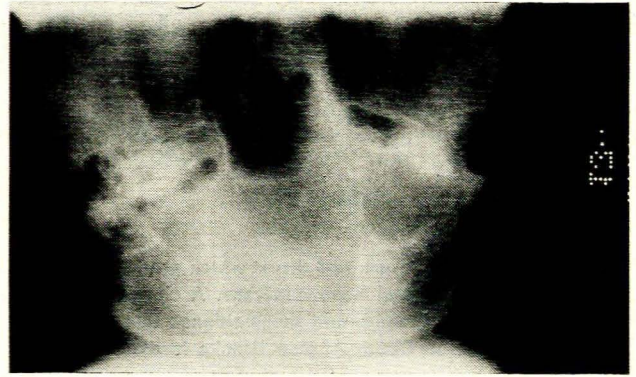


Fig. 2. Subintervertebral tomograph of the skull showing erosion of left jugular bulb by glomus jugulare tumour.

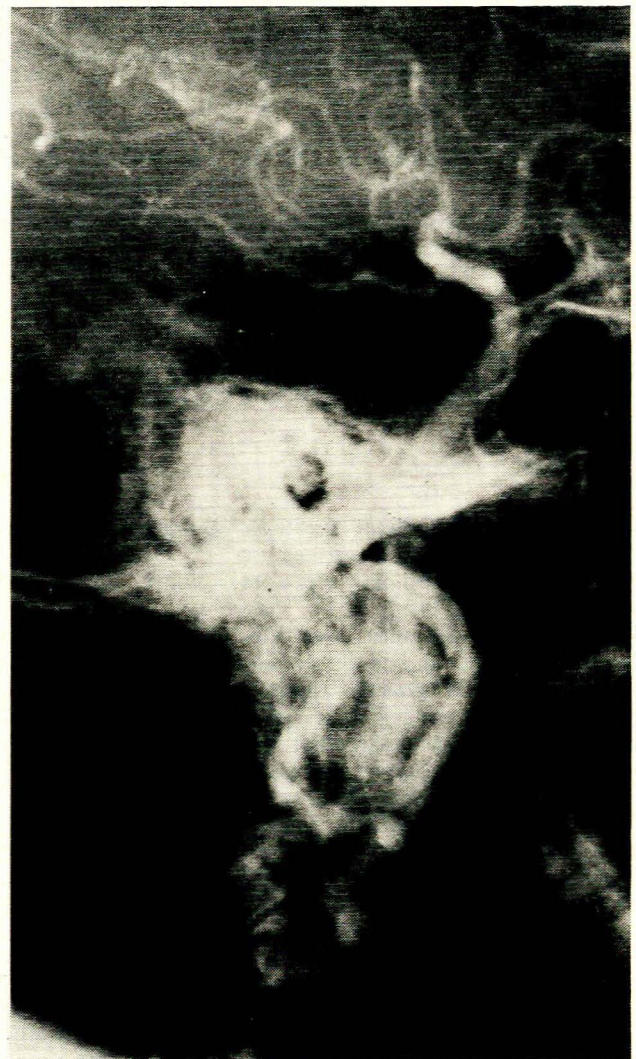


Fig. 3. Carotid angiogram showing vascular tumour in the neck and temporal bone (glomus jugulare).

TABLE I. PRIMARY MIDDLE-EAR TUMOURS, BARAGWANATH HOSPITAL, 1968 - 1972

Case	Age	Sex	Histology	Cranial nerve lesions	TM	Treatment	Course (years of survival)
1	20	F	Glomus jugulare	4 - 12	Granulations and pus	Excision	Well 3/3
2	46	F	Glomus tympanicum	Conductive deafness	Red	Excision	Well 3/3
3	44	F	Glomus tympanicum	Conductive deafness	Red	Excision	Well 2/2
4	35	F	Glomus tympanicum	Conductive deafness	Polyp	Excision	Well 3/3
5	40	F	Glomus jugulare	7, 12	Polyp	Radiotherapy	Well 3/3
6	41	F	Glomus jugulare	8, 12	Polyp	Radiotherapy	Well 2/2
7	50	F	Glomus jugulare	7, 12	Polyp	Radiotherapy	Well 2/2
8	43	F	Glomus jugulare	8, 12	Red	Radiotherapy	Well 2/1
9	45	F	Glomus jugulare	7 - 12	Polyp	Radiotherapy	Well 1/1
10	50	F	Glomus jugulare	8 - 12	Polyp	Radiotherapy	Well 1/1
11	65	F	Glomus jugulare	5 - 12	Granulations	Radiotherapy	Well 1/1
12	50	F	Glomus jugulare	9 - 12	Red	Radiotherapy	Well 1/1
13	54	F	Glomus tympanicum	7, 8	Polyp	Radiotherapy	Well 1/1
14	50	F	Glomus tympanicum	Conductive deafness	Red	Excision	Well 1/1
15	19	F	Squamous carcinoma	5 - 12	Tumour	Radiotherapy	Died 1/1
16	60	M	Papillary adenocarcinoma	7, 8	Tumour	Radiotherapy and petrosectomy	Well 3/3
17		M	Squamous carcinoma	7 - 9	Tumour	Radiotherapy and petrosectomy	Well 3/3
18	67	F	Squamous carcinoma	5, 7 - 10	Tumour	Radiotherapy	Died 2/2
19	42	F	Squamous carcinoma	5, 7, 8	Tumour	Radiotherapy	Well 2/2
20		F	Squamous carcinoma	7, 8	Tumour	Refused	Lost
21	17	F	Giant-cell tumour	5 - 12	Tumour	Radiotherapy	Well 1/2/1

Seven cases of middle-ear chemodectoma have been reported previously¹⁶ (Table I, cases 1 - 7). Seven more cases are included in the present study, indicating the extent of petrous erosion which may occur in this disease (Table I, cases 7 - 14; Figs 1 - 3). Five cases of middle-ear carcinoma have been reported,¹⁷ and another case is included in this study (Table I, case 20). A patient suffering from a giant-cell lesion (tumour or reparative granuloma) of the temporal bone (Table I, case 21), forms the subject of a separate report.¹⁸ During the same 5-year period, 4 White patients were treated at the Johannesburg General Hospital for carcinoma of the middle ear. The incidence of carcinoma of the middle ear is probably about equal in White and Black South Africans. The incidence of middle-ear chemodectomas, however, appears to be different in White and Black South Africans. While 14 South African Black patients with middle-ear chemodectomas were being treated at Baragwanath Hospital during the 5 years (1968 - 1972), only 3 cases of middle-ear chemodectoma in Whites were diagnosed at the Johannesburg General Hospital. The population of Blacks served by Baragwanath Hospital is probably about twice that of Whites served by the General Hospital, but accurate comparisons cannot be made because of the number of patients treated privately. There appears to be, however, a significantly greater incidence of chemodectomas in Blacks. It is significant, also, that the 14 patients with middle-ear chemodectomas were female, indicating an overwhelming sexual preponderance.

Tumours of the Postnasal Space

Carcinoma of the postnasal space is not common in South African Blacks. An average number of 4 cases

per year are treated in the ENT Department of Baragwanath Hospital. A patient with nasopharyngeal carcinoma presenting with hypopituitarism, in whom there was gross destruction of the pituitary fossa, the floor of the middle cranial fossa, and petrous apices, has been the subject of a separate report.¹⁹ In this patient the tumour was found at autopsy to have spread along the carotid arteries, producing erosion of the petrous bones.

Juvenile fibro-angiomas of the nasopharynx may reach a great size and destroy the facial bones and base of the skull by pressure. Extrapharyngeal extension of a nasopharyngeal fibro-angioma is not uncommon; 7 cases have been reported in which the angiofibroma appeared to arise from the maxillary sinus,²⁰ and 1 from the sphenoid sinus.²¹

In the case of very extensive tumours, the site of origin may be difficult to determine. These tumours are known to extend into the infratemporal fossa, probably between the base of the skull and the upper border of the superior constrictor,²² and into the maxillary and sphenoid sinuses.²³ The case described below demonstrates, in addition, erosion of the greater and lesser wings of the sphenoid bone and erosion of the base of the skull as far as the petrous apices (Fig. 4).

Case 2

A 16-year-old South African Black youth presented with a history of nasal obstruction and proptosis on the left, of 1 year's duration. The left nasal cavity was filled with a firm, pink tumour, which displaced the nasal septum to the right. Proptosis was marked, but without impairment of visual acuity. There was a 6-cm diameter, soft, pulsating

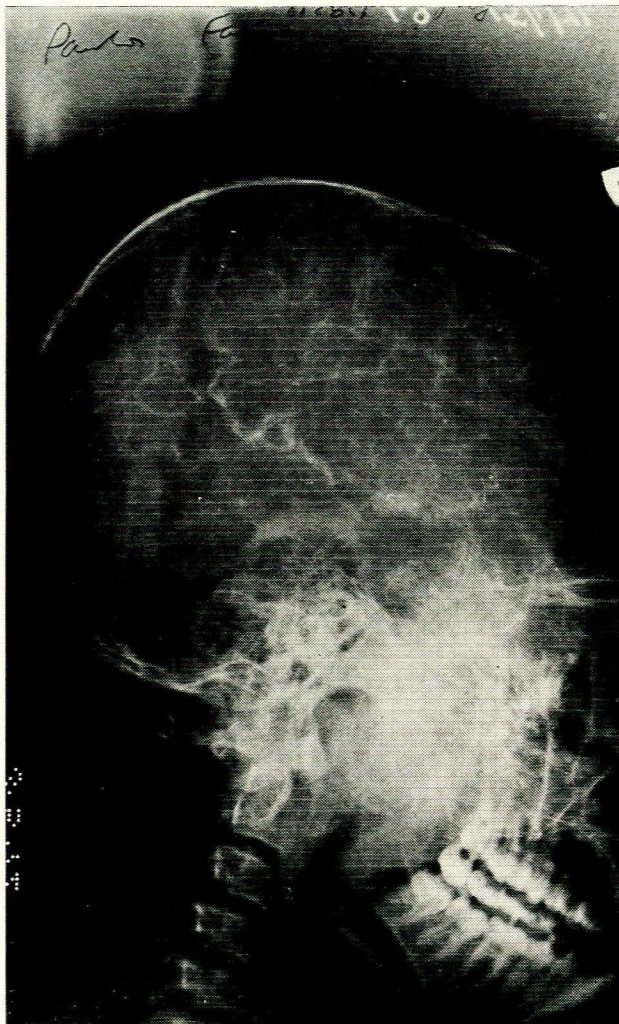


Fig. 4. Carotid angiogram showing vascular tumour of nasopharynx extending posteriorly to petrous bone.

swelling in the left temporal area, lateral to the orbit, above the zygomatic arch and in front of the pinna. X-ray films showed extensive destruction of the medial wall of the maxillary sinus, the ethmoidal air cells, the middle of the floor of the anterior cranial fossa, the front of the sphenoid sinus, the pituitary fossa, and the greater and lesser wings of the sphenoid bone on that side, and the base of the skull as far back as the petrous apices. A biopsy specimen taken of the nasal tumour showed a juvenile fibro-angioma of the nasopharynx. The patient was given 3 000 rads cobalt teletherapy and was in good health 6 months after therapy.

Parotid Tumours

Case 16 (Table I) was a patient with a papillary adenocarcinoma of the parotid gland which involved and largely destroyed the temporal bone. This case has been reported.¹⁷

CYSTIC EROSIONS

Mucoceles of the sphenoid sinus may produce erosion of the petrous apex.²⁴ There were no cases in this series. The following case report documents a second type of cyst which may produce erosion of the petrous temporal bone, viz. an arachnoidal cyst.

Case 3

A 40-year-old South African Black woman presented with severe right otalgia. The external acoustic canal was full of pus and there was a central perforation of the tympanic membrane. The mastoid process was acutely tender. After cleansing of the external acoustic canal, the posterior wall was seen pulsating with the heartbeat, from concha to drumhead. X-ray films showed destruction of the mastoid air cells. A diagnosis of acute mastoiditis was made and a cortical mastoidectomy performed. The operative findings were unusual. There was no cholesteatoma, yet the tegmen tympani, lateral sinus plate, sinodural angle and posterior canal wall were completely eroded. The cerebellar dura was distended and pulsated against the skin of the posterior wall of the external acoustic canal. At this stage the lateral sinus was not visible, despite a wide clearance of squamous temporal bone. A needle biopsy was done of the distended cerebellar dura, and the swelling proved to be a large cyst filled with clear cerebrospinal fluid. The meninges were not inflamed, and after drainage of the cyst, the contour of the temporal lobe and cerebellum appeared normal; the lateral sinus was identified and found to be thrombosed. A modified radical mastoidectomy was performed because the posterior canal wall was absent, and the patient recovered uneventfully. Subsequent neurological investigation did not reveal any abnormality. A diagnosis of an arachnoidal cyst containing cerebrospinal fluid was made, with acute mastoiditis, lateral sinus thrombosis, and erosion of the mastoid, petrous and tympanic parts of the temporal bone.

REFERENCES

1. Cawthorne, T. and Griffith, A. (1961): *Arch. Otolaryng.*, **73**, 252.
2. Harpman, J. A. (1953): *J. Laryng.*, **67**, 189.
3. Tumarkin, A. (1950): *Ibid.*, **64**, 611.
4. Beck, J. C. in Jackson, C. and Coates, G. M., eds (1930): *Diseases of Nose, Throat and Ear*. Philadelphia: W. B. Saunders.
5. Morrison, A. (1956): *J. Laryng.*, **70**, 317.
6. Altman, F. and Waltner, J. G. (1943): *Arch. Otolaryng.*, **38**, 236.
7. Harpman, J. A. (1951): *J. Laryng.*, **65**, 453.
8. Link, R. (1952): *Z. Laryng. Rhinol.*, **31**, 289.
9. Schröder, R. (1956): *Arch. Ohr., Nas., u. Kehlk.-Heilk.*, **169**, 426.
10. Fernández, C. and Lindsay, J. R. (1960): *Laryngoscope*, **70**, 1119.
11. Walsh, T. E., Covell, W. P. and Ogura, J. M. (1951): *Ann. Otol.*, **60**, 1100.
12. Harris, A. J. (1962): *Laryngoscope*, **72**, 954.
13. Friedman, I. (1956): *Reports of the Institute of Laryngology and Otolaryngology*, **6**, 120.
14. McGuckin, F. (1950): *J. Laryng.*, **64**, 693.
15. Wolfowitz, B. L. (1972): *Arch. Otolaryng.*, **96**, 220.
16. Wolfowitz, B. L. and Hunt, J. (1972): *S. Afr. Med. J.*, **46**, 100.
17. Wolfowitz, B. L. and Solomon, A. (1971): *Ibid.*, **45**, 543.
18. Wolfowitz, B. L., Schman, A. and Solomon, A. (in press).
19. Wolfowitz, B. L. and Fernandes, C. (1971): *S. Afr. Med. J.*, **45**, 601.
20. Herbert, F. and Kean, H. (1964): *Laryngoscope*, **74**, 1550.
21. Harma, R. (1958): *Acta Otol.*, suppl. 146.
22. Samy, L. L. and Girgis, I. H. (1965): *J. Laryng.*, **79**, 782.
23. Bualva, M. L. and Mishra, S. C. (1967): *Ibid.*, **81**, 1395.
24. Phelps, P. D. and Toland, J. A. (1969): *Brit. J. Radiol.*, **503**, 845.