

Proptosis in Perspective

GROOTE SCHUUR HOSPITAL, 1950-1970

D. C. BURGER

SUMMARY

A survey of 185 cases admitted with non-endocrine proptosis to the Department of Ophthalmology at Groote Schuur Hospital from 1950 to 1970 was undertaken to establish the incidence and aetiology of this condition. In addition, the results of management of these cases were assessed.

This retrospective analysis was aimed at providing a workable formula for investigation and management of similar problems of proptosis in future.

S. Afr. Med. J., 48, 1121 (1974).

Proptosis accounts for roughly 0,003% of all admissions to Groote Schuur Hospital, and is therefore comparatively rare. An urgent ophthalmological assessment is necessary, since the integrity of the patient's vision may be seriously threatened. As proptosis may be the premonitory sign of systemic disease, or be associated with pathology of the paranasal sinuses and central nervous system, the opinions of the physician, otorhinolaryngologist and neurosurgeon are mandatory.

Statistical Analysis (Table I)

Developmental conditions, e.g. craniofacial dysostosis, acute inflammatory and post-traumatic conditions, do not provide diagnostic problems. The chronic inflammatory and neoplastic groups, accounting for 70% of the total series, have very few pathognomonic signs to make a confident pre-operative diagnosis. Since the management of the two groups is radically different, an aetiological diagnosis is essential.

DISCUSSION

Over the past decade more sophisticated investigations for proptosis have been undertaken before surgical exploration of the orbit.

In general, pre-biopsy tests for proptosis confirm what is suspected clinically, i.e. the presence of a space-occupying lesion in the orbit. These tests do not replace the histopathological diagnosis.

Department of Ophthalmology, University of Cape Town and Groote Schuur Hospital, Cape Town

D. C. BURGER, M.B. CH.B., M.MED. (OPHTH.), D.O.

Date received: 25 January 1974.

TABLE I. THE INCIDENCE AND AETIOLOGY OF PROPTOSIS, GROOTE SCHUUR HOSPITAL, 1950 - 1970

Condition	No.	Total	%	Total
Developmental anomalies		8		4,3
Crouzon's disease	6		3,3	
Fibrous dysplasia	2		1	
Inflammatory conditions		80		43,2
Pseudotumours	15		8,1	
Orbital cellulitis	40		21,5	
Mucocele	12		6,5	
Hydatid disease	7		3,8	
Superior orbital fissure syndrome	5		2,7	
Tuberculoma	1		0,6	
Traumatic conditions		24		13,0
Retrobulbar haemorrhage	18		9,7	
Carotid cavernous fistula (CCF)	6		3,3	
Circulatory abnormalities		6		3,3
Spontaneous CCF	6		3,3	
Tumours of the orbit		53		28,6
Primary	30		16,2	
Secondary	12		8,5	
Metastatic	1		5,0	
Unknown causes	14	14	7,6	7,6
Total		185		100

During this survey it became apparent that the relative lack of investigation before 1960 did not materially change the ultimate prognosis with regard to vision or life expectancy. Not only was hospitalisation then shortened, but a definite diagnosis was reached earlier.

Management

We propose the following guidelines for the investigation of proptosis where an orbital tumour is suspected. Generalisations are based on past experience in the Eye Department at Groote Schuur Hospital.

Routine investigations: Haematological examinations should include full blood count, erythrocyte sedimentation rate and examination of the bone marrow. Serum chemistry examinations should include those for serum proteins, calcium/phosphate, acid phosphatase and alkaline phosphatase. The fluorescent treponemal antibody absorption test (FTA-ABS) should also be carried out.

Urine should be analysed for Bence-Jones protein, and vanillylmandelic acid. Casoni and Mantoux skin tests

should be performed; and X-ray films taken of the skull, optic canals and orbital fissures, paranasal sinuses, post-nasal space, chest, tomography of orbit and skeletal survey.

Proptosis presenting with a palpable mass: A surgical approach should be chosen so as to ensure minimal trauma to surrounding vital structures, but yet provide adequate exposure. If the mass is well encapsulated and anteriorly situated, it should be removed *in toto*. If the lesion appears infiltrative, only a biopsy specimen should be taken. Following histology, definitive treatment is instituted. In this category, the more common conditions found were: (i) dermoid and parasitic cysts in children; and (ii) chronic ethmoidal mucoceles and lacrimal tumours in adults.

Proptosis presenting without a palpable mass: This group represents two-thirds of the chronic inflammatory and neoplastic cases seen.

It is essential to exclude ophthalmic Grave's disease. Following the recent availability of thyroid-releasing hormone (TRH), we now favour thyroid-stimulating hormone (TSH) assays as being the most reliable method of studying thyroid function. It has recently been found that most patients in this category are slightly hypothyroid when the TSH response to TRH stimulation is assayed.¹

Secondly, an examination is required to exclude pathology in the postnasal space and sinuses.

Thirdly, investigations are carried out in order to demonstrate the locality of the mass in the orbit, and several techniques are employed.

Serial tomography of the orbit is of value to determine the exact extent of soft tissue tumours and of bony involvement.

Technetium-99 brain scans with the head in the extended position may often reveal the presence of a tumour if there is an increased uptake in the orbit.

In order to establish the presence of possible vascular connections or a vascular tumour, a carotid angiogram is performed. With the special subtraction techniques now employed it has been possible to outline the tumour. At the same time an orbital venogram is performed, which may be useful in the localisation of a tumour or demonstration of venous connections.

The β scan has proved an accurate method of localisation by some workers using ultrasonography.²

We do not advocate orbital pneumatography, because interpretation of radiographs of a lesion outside the muscle cone is very difficult and, in addition, the gas injected in the orbit causes an increase of intra-orbital pressure and may compromise the blood supply to the optic nerve. Blind punch biopsies are contra-indicated for fear of haemorrhage from a vascular tumour or dissemination of tumour cells.

Proptosis where no mass can be demonstrated: If no tumour can be demonstrated, a diagnostic exploratory orbitotomy is done if there has been a progression of the proptosis and/or a reduction in visual acuity due to optic nerve compression.

Should the proptosis remain unaltered or regress, surgical exploration is not done. If the proptosis remains static, the patient is observed for 6 months before repeating special investigations (*vide supra*).

Where an inflammatory pseudotumour is clinically suspected, trial therapy with steroids is discouraged, since neoplasms may show a similar shrinking response.³ Antibiotics are used if inflammatory signs are severe.

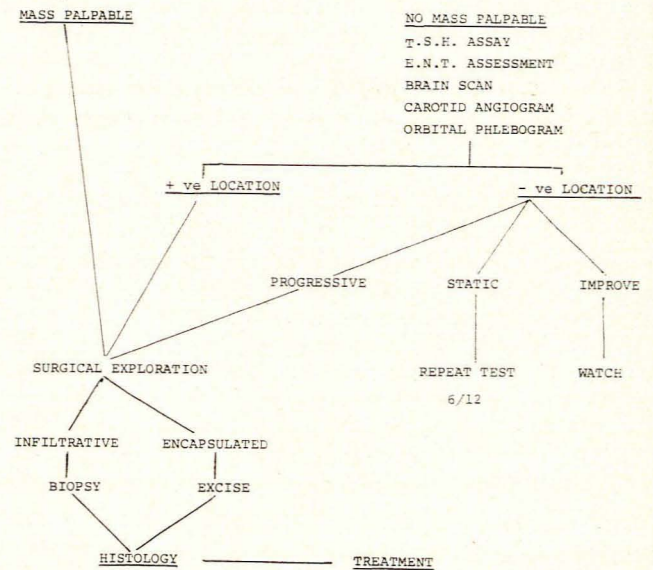


Fig. 1. Special investigations.

Fig. 1 summarises our general approach to the problem of proptosis. No attempt has been made to delineate individual conditions or treatment.

This project was financed by the Gratitude Fund for Ophthalmology, the Department of Ophthalmology Research Fund and the Goosen Trust Fund.

REFERENCES

1. Ormston, B. J., Alexander, L., Evered, D. C., Clark, F., Bird, T., Appleton, D. and Hall, R. (1973): Clin. Endocr., 2, 369.
2. Catford, G. V. and Taylor, H. W. (1972): Transactions of the Ophthalmological Societies of the United Kingdom, vol. 92. London: Churchill-Livingstone.
3. Walsh, F. B. and Hoyt, W. F. (1969): Clinical Neuro-Ophthalmology, 3rd ed, p. 2018. Baltimore: Williams & Wilkins.