

Right Aortic Arch and Associated Anomalies

REPORT OF TWO CASES COMPARED WITH A CASE OF COMPLETE SITUS INVERSUS

T. MULLER

SUMMARY

Two cases of right-sided aortic arch are presented. The topographical changes in the surrounding structures are described with special reference to the recurrent laryngeal nerve, the ligamentum arteriosum and the thoracic duct. The anatomy is compared with the right-sided aortic arch as seen in a case of complete situs inversus.

S. Afr. Med. J., 48, 1059 (1974).

Aortic arch anomalies and right-sided aortic arch are well known from the literature. The cases described here present certain interesting features as regards the anatomy of the ductus arteriosus, recurrent laryngeal nerve and the thoracic duct associated with a right-sided aortic arch.

DESCRIPTION OF THE ANATOMICAL FINDINGS

Case 1

During routine dissection of the thorax of a Black male aged 58 years, a right-sided aortic arch was noted. The cause of death had been given as hepatoma. Unfortunately, only the trunk was available for dissection. The dissection of the abdomen was extremely difficult due to infiltration and matting of the intestines and enlarged lymph glands. Multiple renal arteries could be identified.

The superior vena cava and azygos veins showed no deviation from the normal. The thoracic duct, however, emerged from between the right subclavian and right common carotid arteries and joined the junction of the right and left brachiocephalic veins, i.e. on the right side of the superior mediastinum (Fig. 1). The thoracic duct could be traced deep into the right-sided aortic arch, but because of matted lymph glands could not be followed further than this. The first branch of the aortic arch was the right subclavian artery which extended upwards for 4.5 cm before giving off its branches which showed several variations. The most striking was the origin of the suprascapular artery from the internal thoracic artery (Fig. 2). Daseler and Anson⁷ found this variation in 29 of 775 extremities (3,74%).

Department of Anatomy, University of Pretoria
T. MULLER, M.B. CH.B.

Date received: 7 December 1973.

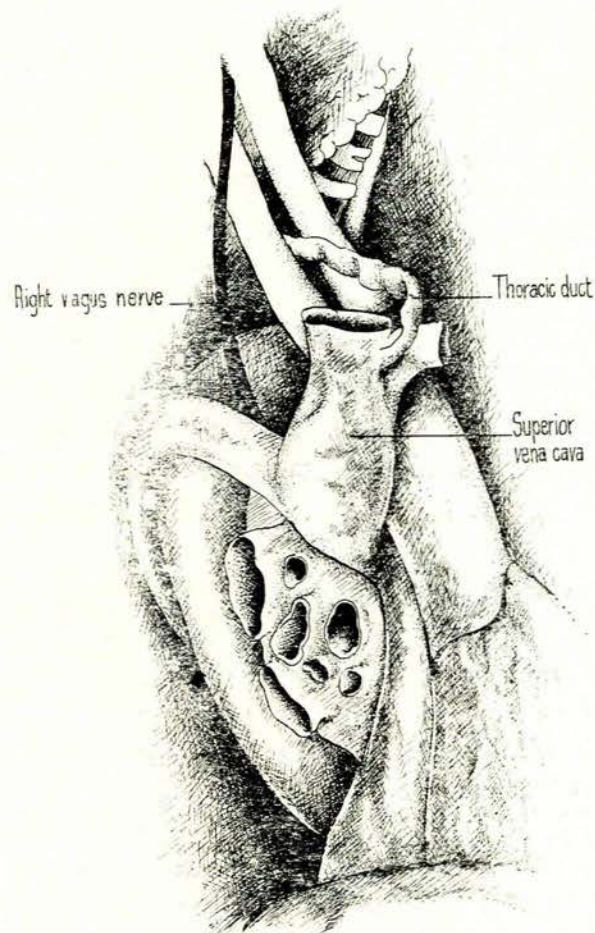


Fig. 1. Case 1—illustrating right view of heart to show right aortic arch. Note the thoracic duct opening on the right side at the junction of the right and left brachiocephalic veins.

The next branch of the aortic arch was the right common carotid artery and immediately next to it was a left brachiocephalic artery 2 cm in length. The left common carotid artery originated here and was the direct continuation of the left brachiocephalic artery. An arch-like dilatation was seen from where the left subclavian artery arose (Fig. 3). This was the point where the left vagus nerve crossed the subclavian artery and gave off its recurrent branch. A 4-cm-long left ductus arteriosus

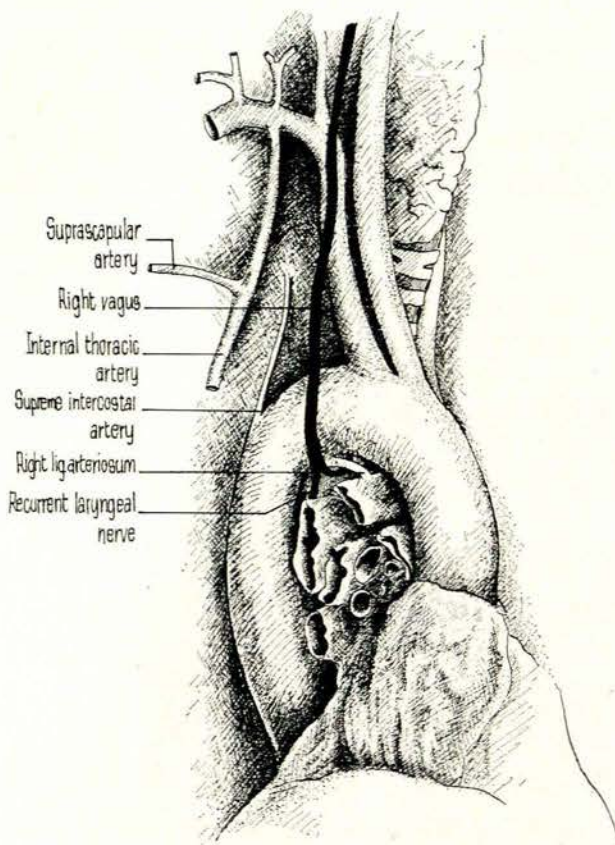


Fig. 2. Case 1—illustration of aortic arch and branches. Branches of the right subclavian artery are shown. Note the right vagus, right recurrent laryngeal nerve and right ligamentum arteriosum.

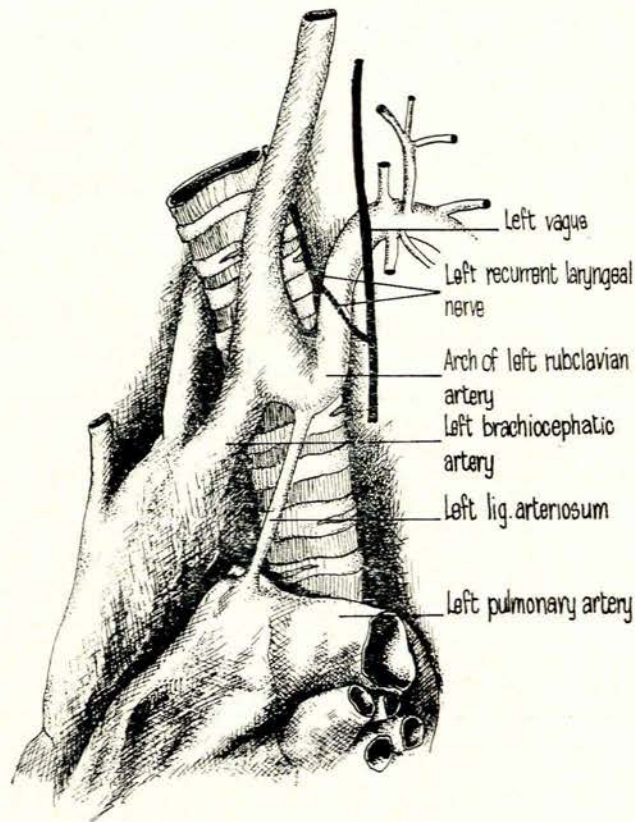


Fig. 3. Case 1—illustration of left aspect of aortic arch. Note the unusual arch of the left subclavian artery and the long ligamentum arteriosum which had no relationship to the recurrent laryngeal nerve of the left vagus.

stretched from this dilatation to the junction of the pulmonary trunk and the origin of the left pulmonary artery. The recurrent laryngeal nerve had no relation to the ligamentum arteriosum.

The right vagus nerve crossed the right-sided aortic arch from where its recurrent laryngeal branch arose deep into the right ligamentum arteriosum which was attached to the smaller right pulmonary artery and the aortic arch. In other respects the heart appeared normal.

Case 2

During routine dissection of the thorax of a 4-year-old Black male a right-sided aortic arch was noted. The cause of death was given as cardiac failure. The superior vena cava and the azygos vein showed no deviation from the normal. The thoracic duct was found on the right side of the neck and opened at the junction of the right and left brachiocephalic veins on the right side of the superior mediastinum. The first branch of the aortic arch was the right subclavian artery, the second the right common carotid artery and the third the left brachiocephalic artery (Fig. 4). From the latter the left common carotid and the left subclavian artery arose. The ligamentum arteriosum was 1 cm long. Proximally it was attached to the point of origin of the left subclavian artery and had

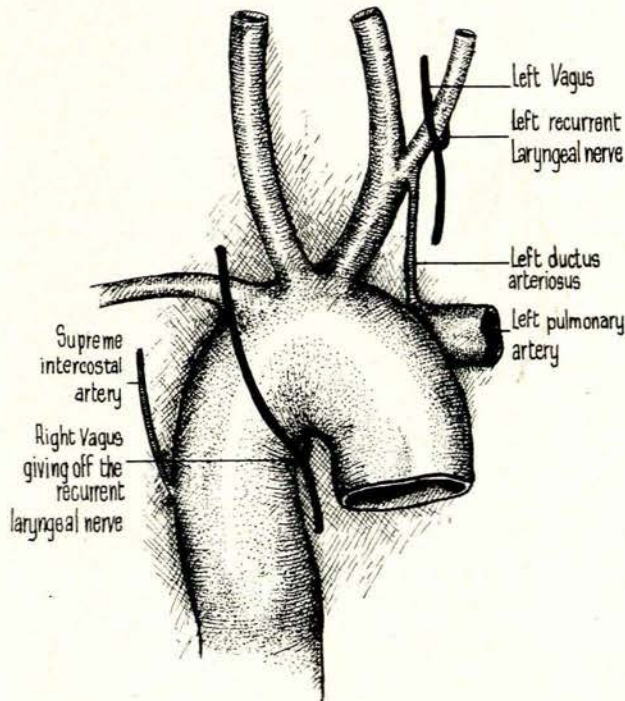


Fig. 4. Case 2—illustration of the right aortic arch with its branches. Note the left-sided ductus arteriosus which had no relationship to the left recurrent laryngeal nerve.

a patent lumen. Distally it was attached to the left pulmonary artery and the lumen appeared to be partially obliterated. The right vagus nerve crossed the aortic arch and the right recurrent laryngeal nerve originated here and hooked back deep into the aortic arch. No ligamentum arteriosum could be found. On the left side the left vagus nerve crossed the left subclavian artery from where the left recurrent laryngeal nerve arose. It had no relationship to the ductus arteriosus, being situated 1 cm to the left of it.

The external appearance of the heart was narrow and pointed. A large right atrium overlapped the unusually large, peculiarly shaped, ascending aorta. There was very marked right ventricular preponderance of 4 to 1 (Fig. 5). Unfortunately the heart was rather hard and dry and the detail of the internal structure was not well preserved. The right atrium was large and the foramen ovale completely closed. The tricuspid valve appeared to be normal and led to a very large right ventricle from where a very large ascending aorta took origin. The three semilunar valve cusps showed some deformity and were somewhat ragged. There was a 5-mm opening in the membranous part of the interventricular septum. The pulmonary trunk ended blindly in solid cardiac muscles which appeared to belong to the right ventricle. The left ventricle had a

slit-like lumen with a miniature mitral valve connecting the small left atrium posteriorly, into which the pulmonary veins opened.

Case 3

An adult Black male who had died accidentally, showed complete situs inversus of all the organs of the body. Complete mirror image of normal anatomy was seen as opposed to abnormal anatomy described in the previous 2 cases (Fig. 6).

DISCUSSION

The explanation of these deviations is directly related to the aortic arch derivatives in the human adult. The work of Congdon² and Poynter³ has left but few gaps in our understanding of the morphological development of this system. Barry,⁴ in his classical article on the aortic arch derivatives in the human adult, as referred to by Patten⁵ and others, emphasises the chief inadequacy of this type of diagram in that it cannot by its nature show the adult configuration of the great vessels leaving the heart, nor

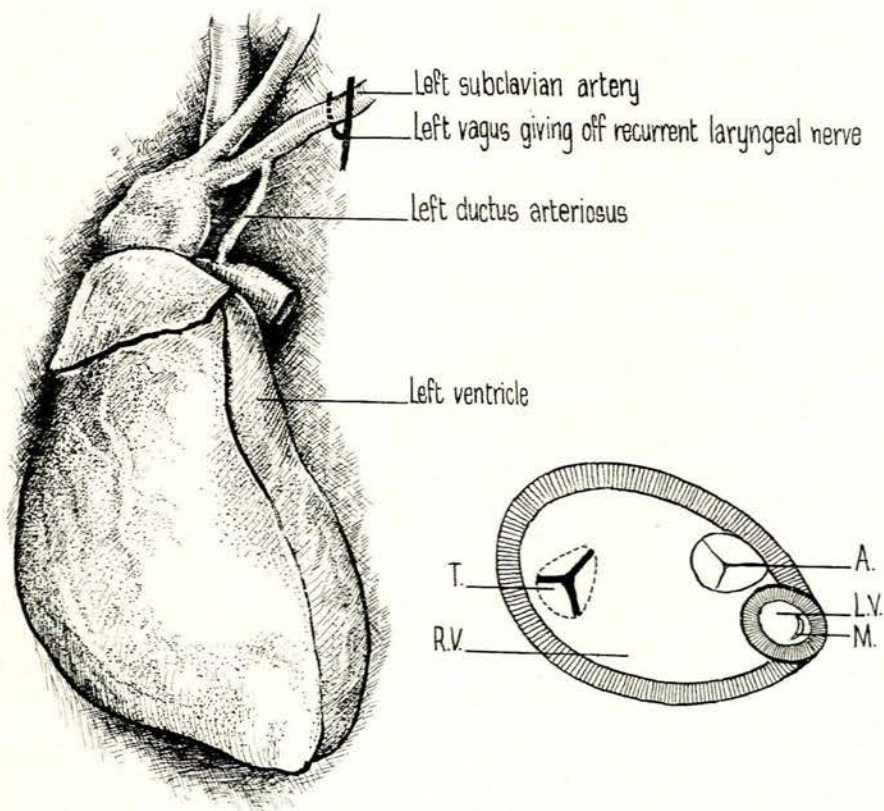


Fig. 5. (a) Case 2—left view of heart is illustrated. Note the left ventricle is situated posteriorly. (b) Diagrammatic cross-section of heart to show the relative sizes of the ventricles and position of the valves: T = tricuspid valve, A = aortic valve, R.V. = right ventricle, L.V. = left ventricle, M = mitral valve.

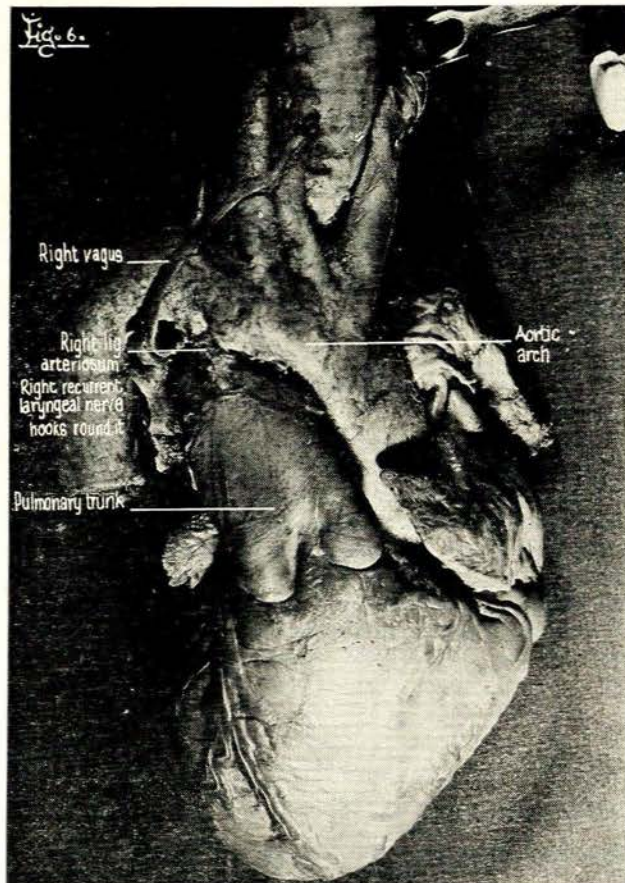


Fig. 6. Case 3—the heart in a case of complete situs inversus in an adult male.

can it show the relatively tremendous alterations in proportion and relationship that have occurred during development. One of the most profound of these is the cephalic shift of the origin of the subclavian arteries (Figs 7 and 8).

In the light of this embryological background, Patten⁶ considered some of the more important anomalies involving aortic arch derivatives. These included right-sided aortic arch, which results from the retention of the right fourth aortic arch and right dorsal aortic root instead of the left as the main feeder channel to the dorsal aorta (Fig. 9 (a) and (b)). In itself such an arrangement of vessels is efficient, as was seen in case 1, and it presents none of the mechanical complications which are liable to occur in some of the other types, such as the condition commonly known as aortic ring. Patten points out that awareness of the possibility of such a condition is important when interpreting X-ray films, and failure to have recognised its existence before undertaking surgical procedure in this region can result in serious difficulties.

Sprung and Cutler⁹ reviewed the literature of 100 cases of right aortic abnormalities and presented a case of their own. They suggested that to facilitate discussion, the cases of right aortic abnormalities should be considered in the following groups, according to the associated amount

of transposition and abnormal branching: (a) situs inversus viscerum; (b) right aorta, without inversion of other viscera: (i) double aorta, (ii) right aorta, giving off the left carotid, right carotid, right subclavian and left subclavian, and (iii) right aorta, giving off left brachiocephalic A. anonyma, right carotid, right subclavian. Case 1 presented here falls into this latter group, with the additional feature of the attempt at a double aortic arch, bilateral ligamentum arteriosum and right-sided thoracic duct. Case 2 also belongs to this category with left-sided ductus arteriosus. The question of the ductus arteriosus will be discussed in conjunction with the recurrent laryngeal nerve at a later stage.

Apart from the right-sided aortic arch, case 2 had an unusual cardiac anomaly, and the question arose how life was maintained for 4 years (Fig. 10). The venous blood entered the right atrium and passed through the tricuspid valve to the very large right ventricle and out through the enlarged aorta. To reach the lungs the blood had to pass through the left brachiocephalic artery, left subclavian artery, ductus arteriosus and then to the junction of the pulmonary trunk with the left pulmonary artery. The arterial blood returned from the lungs through small pulmonary veins to the left atrium through the small mitral valve to the left ventricle, which obviously had little function except to pump the small amount of arterial blood through the interventricular septum into the right ventricle and out into the aorta. The arterial stream of blood must have been very small in comparison with the venous blood pumped out into the aorta. Most of the arterial blood was probably injected into the branches of the aortic arch and very little reached the lower limbs.

We now come to the variations of the ductus or ligamentum arteriosum as seen in the 2 cases presented and their association with the recurrent laryngeal nerve. Poynter³ states that abnormalities in the development of the pulmonary arches are rare, except in the condition of persistence of the ductus arteriosus. Persistence of both pulmonary arches is very rare. He refers to a case of Breschet in 1826 and Peacock in 1868. In the former the aortic arch was normal, the common pulmonary artery short and from its left branch the ductus arteriosus extended in the usual way. From the right branch of the pulmonary artery, a slender artery extended upwards to the right, joining the subclavian artery in its proximal portion. In case 1 the reverse was found, due to the right-sided aortic arch. Persistence of the right arch with atrophy of the left ductus arteriosus is not as unusual as persistence of both arches (case 2). Poynter does not refer to the recurrent laryngeal nerve and its relationship to the abnormal ductus arteriosus.

Edwards⁷ points out that when discussing double aortic arches one would expect right and left ducti arteriosi (or ligaments), which were seen in case 1, but usually only one ductus arteriosus is present. In his opinion, malformation of the aortic arch derivatives may be divided into 2 groups, depending on whether the ductus arteriosus took origin from the left or right pulmonary artery (case 2). Mirror image of the normal was seen in situs inversus. Edwards does not mention the recurrent laryngeal nerve and its relationship to the ductus arteriosus.

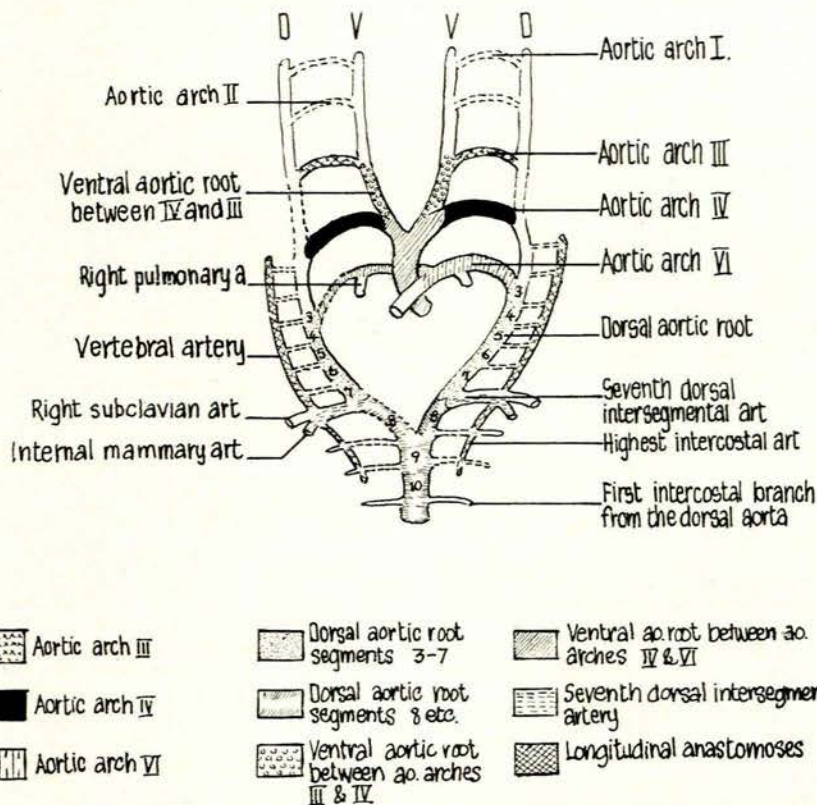


Fig. 7. Schematic diagram indicating the various components of the aortic arch complex in the human embryo as redrawn from Barry⁴ and Patten.⁵ Basic plan: Those components which do not normally persist in the adult are indicated by broken outlines. Since the fifth arch appears, if at all, only in rudimentary form, it has been omitted from the diagram altogether. V = primitive ventral aortic arch, D = primitive dorsal aortic arch.

The developmental history of the aortic arches has a direct influence on the relationship of the nerves. According to Starck⁶ the changes that take place in the primitive aortic arches or branchial arteries determine the ultimate relationship of the nerves concerned. The glossopharyngeal nerve belongs to the third arch. The nerves for the consecutive arches originate from the vagus. The nerve associated with the fourth arch is the superior laryngeal branch of vagus (X_1), whereas the nerve to the fifth arch is absent in mammals but has been demonstrated in reptiles (X_2). The recurrent laryngeal nerve (X_3) is associated with the sixth arch, and it follows the typical course round the artery of the sixth arch. It is transformed into a long loop by the elongation of the neck and the descensus of the heart. On the left side the sixth arch remains as the ductus arteriosus, later to become ligamentum arteriosum. On the right side the fifth and sixth arches disappear and the recurrent laryngeal nerve hooks round the right subclavian derivative of the embryonic fourth arch.

Grant and Basmajian⁹ give a very lucid explanation of the fate of the aortic arches and their relationship to the associated nerves (Figs 11 (a) and (b) and 12 (a) and (b)). They point out that in the neck the chief function of

the vagus is to supply the alimentary and respiratory tubes. This it does via 3 branches: pharyngeal, superior laryngeal and recurrent laryngeal. In the embryo, these 3 pass between the primitive ventral and dorsal cephalic aortic arches. Postnatally the pharyngeal branch continues on this course. With the breaking down of the segment of the primitive dorsal aorta between the third and fourth arches, the superior laryngeal nerve can rise to a higher level and slip behind the internal and external carotids. On the disappearance of the right fifth and sixth primitive aortic arches, the right recurrent laryngeal nerve rises to the fourth primitive arch (subclavian artery), curves below it, and passes behind the common carotid artery. The left recurrent laryngeal nerve continues its original course round the primitive sixth arch (ductus arteriosus).

From the cases described it becomes clear that the sixth arch, the ductus arteriosus, can develop according to the normal embryological pattern irrespective of the side on which it occurs, as was seen in case 1 on the right side and in the case of complete situs inversus. On the other hand, what is not mentioned in the literature is an abnormal development of the sixth arch in that it apparently develops out of line with the other aortic arches, probably anteromedially so that the ductus arterio-

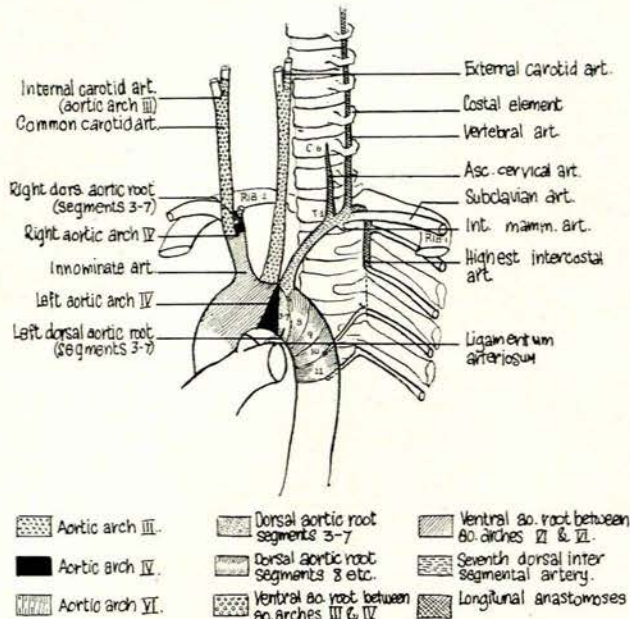


Fig. 8. Diagram of adult aorta and its main branches with the location and extent of the vessels derived from the various embryonic aortic arch components indicated by use of the same schematic analysis employed for Fig. 7. (As redrawn from Barry⁴ and Patten.⁵)

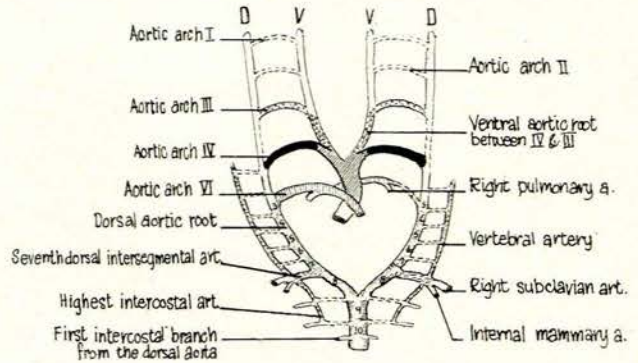


Fig. 9. (a) Schematic diagram indicating the various components of a right-sided aortic arch in the human embryo. (b) Diagram of right adult aortic arch and the main branches. Various embryonic aortic arch components indicated by use of the same schematic analysis employed for Fig. 7. (As redrawn from Patten.⁶) V = primitive ventral aortic arch, D = primitive dorsal aortic arch.

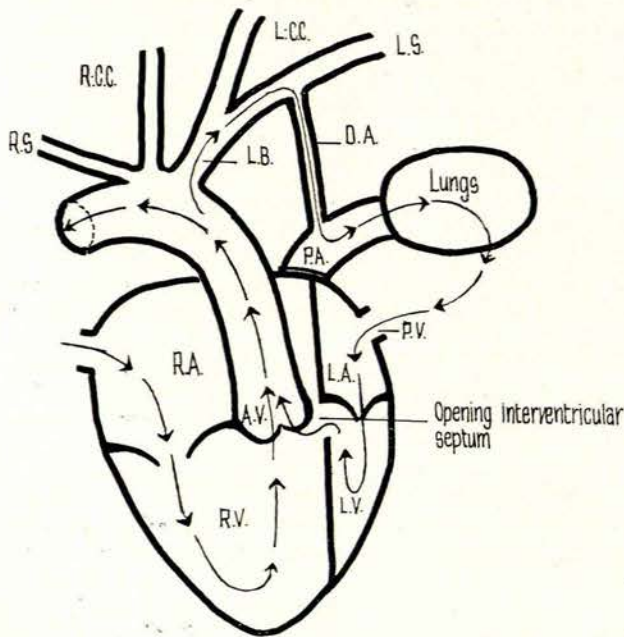


Fig. 10. Schematic representation of circulation through heart and lungs in Case 2. R.A. = right atrium, L.A. = left atrium, A.V. = aortic valve, R.C.C. = right common carotid, L.B. = left brachiocephalic, D.A. = ductus arteriosus, P.V. = pulmonary veins, R.V. = right ventricle, L.V. = left ventricle, R.S. = right subclavian, L.C.C. = left common carotid, L.S. = left subclavian, P.A. = pulmonary artery.

...sus or subsequent ligament bear no relationship to the recurrent laryngeal nerve, which then hooks round the subclavian artery as was seen in cases 1 and 2 on the left side (Figs 3 and 4). The explanation postulated for this anomaly is diagrammatically represented in Fig. 13 (a), (b) and (c).

Poynter⁷ refers to variations of the thoracic duct associated with arterial anomalies of the aortic arches. He states that more observations are needed at the cephalic end to determine whether the right duct normally develops as the right aorta does and disappears by a similar atrophy. Persistence of the right duct and obliteration of the left have been observed in cases of right aortic arch, of the type presenting a left brachiocephalic artery. It has also been observed in the right aortic arch of the type in which the left subclavian is the last branch. Poynter finally concludes that it is difficult to discover an exact relationship between arterial variations and thoracic duct variations. Duct variations are independent of arterial variations, except in so far as developmental disturbances affecting the arteries may be so far reaching as also to affect the thoracic duct.

In Sprong and Cutler's case⁸ of right aortic arch, the upper part of the thoracic duct together with the jugular

veins had been removed. They point out, however, that the part of the duct caudal to the fifth thoracic vertebra was situated distinctly to the left of the midline rather than to the right as is normally the case.

Discussing double aortic arch, Lockhart¹⁰ is the only author to refer to the thoracic duct being enclosed in the arterial collar, but no mention is made as to whether the duct opened in the normal position or not. Davis¹¹ made a statistical study of the occurrence of the thoracic duct in man and points out that if one assumes that the embryonic thoracic duct is bilaterally symmetrical, varia-

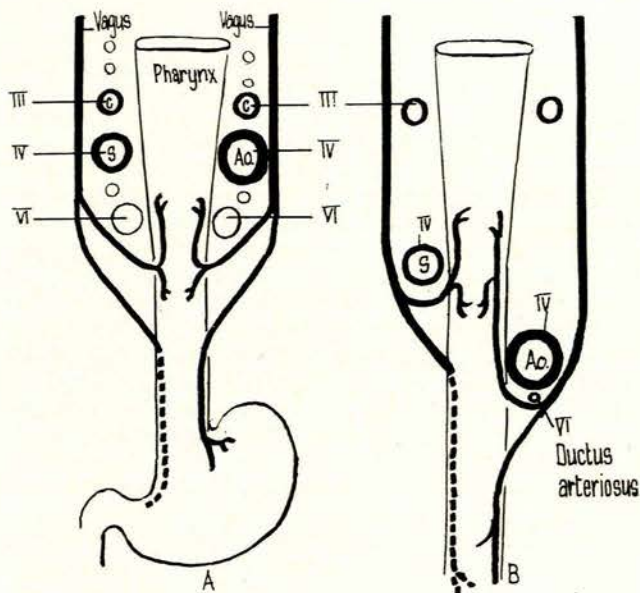


Fig. 11. (a) Early embryonic life to show the relationship of the vagus and recurrent laryngeal nerves to the primitive aortic arches. (b) Late stage to explain the asymmetrical courses of the recurrent laryngeal nerves. C = common carotid, S = subclavian, Ao = aortic arch. (As redrawn from Grant and Basmajian.⁹)

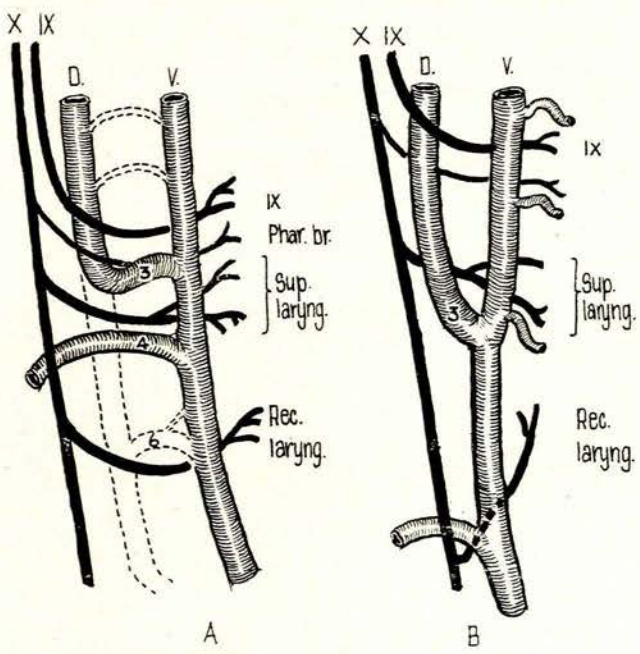


Fig. 12. Developmental explanation of the relationship of the glossopharyngeal, superior laryngeal and recurrent laryngeal nerves to the carotid arteries. (a) Early stage; (b) late stage. (As redrawn from Grant and Basmajian.⁹)

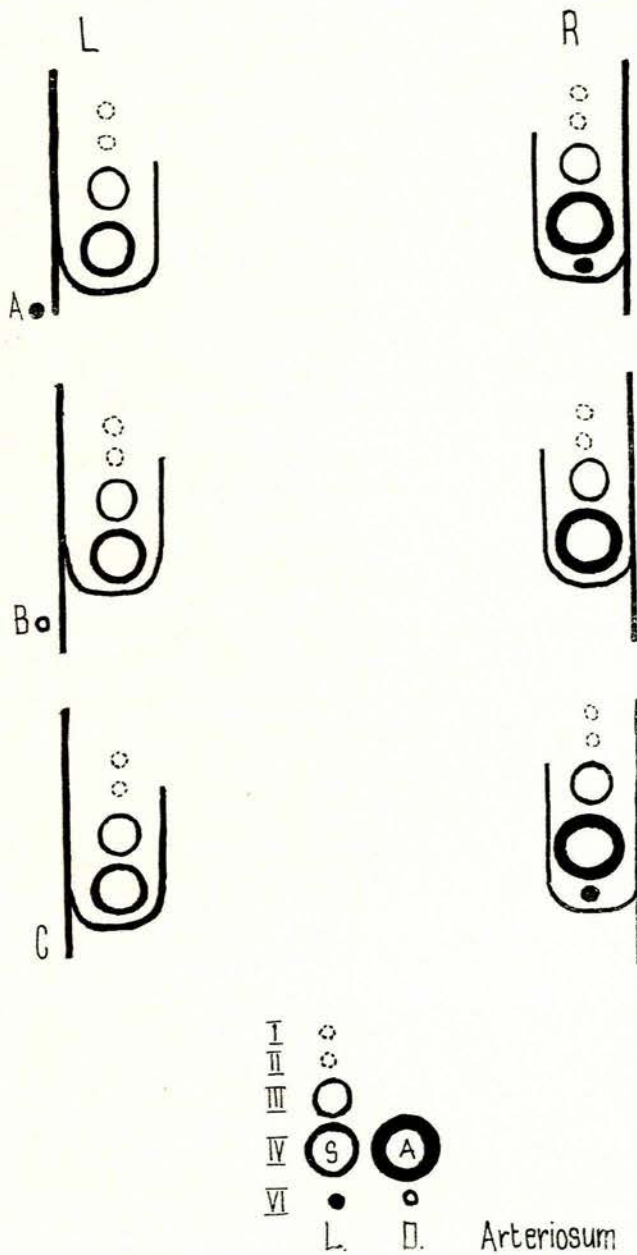


Fig. 13. Diagrammatic reconstruction of the vagus nerve and its recurrent laryngeal branch to the aortic arches in: (a) Case 1—left and right sides, (b) Case 2—left and right sides, (c) situs inversus left and right sides. I, First aortic arch; II, Second aortic arch; III, Third aortic arch; IV, Fourth aortic arch; VI, Sixth aortic arch. S = subclavian artery, A = aorta, L = ligamentum arteriosum, D = ductus arteriosus.

tions will depend on which portions of the embryonic thoracic ducts atrophy and disappear, and which continue to develop. He divides the possible varieties into 9 types. In all his illustrations he shows the thoracic duct opening at the junction of the internal jugular and subclavian vein, irrespective of it being right, left, or bilateral. He tabulates the mode of termination of the thoracic duct in his own 22 cases and compares them with the 50 of Parsons and Sargent¹² and finds a close correlation in the mode of termination. None of these authors refers to a thoracic duct terminating on the right side at the junction of the right and left brachiocephalic veins, and no mention is made of what happens to the thoracic duct in a right-sided aortic arch.

Van Pernis¹³ made a study of 1 081 cadavers. He found that from the upper orifice of the thorax the combined or main thoracic duct arched 3-5 cm above the clavicle, crossing anteriorly to the subclavian artery in 92% of the cases, and in the remainder it crossed posteriorly. The duct ended in the angle or within 1 cm of the angle formed by the junction of the left subclavian and left internal jugular veins. He states that a right thoracic duct is not easily demonstrable. Again no mention is made of the thoracic duct opening at the junction of the right and left brachiocephalic veins, and no mention is made in this large series of a thoracic duct associated with a right-sided aortic arch. Cameron¹⁴ described a case of right aortic arch with abnormal disposition of the left brachiocephalic vein and thoracic duct. According to Davis this belongs to the type 9 where the thoracic duct runs in its entire course on the left side of the aorta.

Romer,¹⁵ in his description of the comparative anatomy of the thoracic duct, refers to the tendency of a pair of longitudinal lymphatic ducts to develop along the back of the body cavity, running parallel to the posterior cardinal or vena cava, with anterior and sometimes posterior openings. These ducts serve as collectors for the lacteals. Paired ducts are common in fish, reptiles and birds, but in some fish, reptiles and mammals generally the pair tend to fuse into a single asymmetrical duct. No mention is made of the side, or whether there is a difference in the amphibia with double aortae and birds with right-sided aortae.

In both my cases of right-sided aortic arch the thoracic duct was situated on the right side and opened at the junction of the brachiocephalic veins on the right side of the superior mediastinum. In the case of situs inversus, unfortunately, no special attention was paid to the dissection of the thoracic duct. Cleveland,¹⁶ in his case of situs inversus, described the thoracic duct as curving outward and to the right in front of the right subclavian artery, terminating in a bulbous enlargement that emptied at the junction of the right subclavian and right internal jugular veins. Varono and Merklin¹⁷ described the anatomical findings in a 45-year-old Black with situs inversus. He described the thoracic duct as follows: 'After crossing through the aortic hiatus of the diaphragm, the thoracic duct immediately crossed to the right side and ascended first along the right side of the aorta and then in relation to the right side of the azygos vein. At the cervical level the thoracic duct left the right border of the oesophagus, turned laterally and passed under the subclavian artery to terminate in the first part of the right brachiocephalic vein.' In a vast amount of literature on situs inversus there are very few references to the thoracic duct, which is probably due to the fact that it is not always easy to demonstrate, and often damaged if not identified and dissected in the first instance.

REFERENCES

1. Daseler, E. H. and Anson, B. J. (1959): *Surg. Gyn. Obstet.*, **108**, 149.
2. Congdon, E. D. (1922): *Carnegie Contrib. to Embr.*, **14**, 47.
3. Poynter, C. W. M. (1916): *Univ. Studies*, **16**, 229.
4. Barry, A. (1951): *Anat. Rec.*, **111**, 221.
5. Patten, B. M. (1968): *Human Embryology*, 3rd ed., pp. 554-558. New York: McGraw-Hill.
6. Sprong, D. H. and Cutler, N. L. (1930): *Anat. Rec.*, **45**, 365.
7. Edwards, J. E. (1948): *Med. Clin. Amer.*, **32**, 925.
8. Starck, D. (1965): *Embryologie*, 2nd ed., pp. 542-545. Stuttgart: George Thieme Verlag.
9. Grant, J. C. B. and Basmajian, J. V. (1965): *Grant's Method of Anatomy*, 7th ed., pp. 520-522, 658. Baltimore: Williams and Wilkins.
10. Lockhart, R. D. (1930): *J. Anat. (Lond.)*, **64**, 189.
11. Davis, H. K. (1915): *Amer. J. Anat.*, **77**, 211.
12. Parsons, F. C. and Sargent, P. W. G. (1909): *Lancet*, **1**, 1173. (As quoted by Davis¹³)
13. Van Pernis, P. A. (1949): *Surgery*, **25**, 806.
14. Cameron, S. (1903): *Lancet*, **2**, 670. (As quoted by Davis¹³)
15. Romer, A. S. (1950): *The Vertebrate Body*, 1st ed., pp. 458-461. Philadelphia and London: W. B. Saunders.
16. Cleveland, M. (1926): *Arch. Surg.*, **13**, 342.
17. Varono, N. R. and Merklin, R. J. (1960): *J. Int. Coll. Surg.*, **33**, 131.