

A Comparative Study of Pycnodysostosis, Cleidocranial Dysostosis, Osteopetrosis and Acro-osteolysis

A. WOLPOWITZ, A. MATISONN

SUMMARY

A radiological study of cases of pycnodysostosis, osteopetrosis, cleidocranial dysostosis and acro-osteolysis revealed an interwoven relationship as regards the X-ray findings with numerous identical signs that these conditions had in common. Open fontanelles and sutures as well as metopic sutures were found in all 4 conditions; wormian bones, diminution or complete loss of mandibular angles, and hypoplastic paranasal sinuses and facial bones were noted in cleidocranial dysostosis, pycnodysostosis and acro-osteolysis. Undertubulation of long bones is seen in cleidocranial dysostosis and osteopetrosis. Osteopetrosis and pycnodysostosis show sclerosis of bone, dense orbital margins, fractures after minimal trauma with abundant callus and rapid healing in common, while there is absorption of terminal phalanges and disturbance in the development of the teeth in both pycnodysostosis and acro-osteolysis.

Furthermore, a review of the literature shows bone-within-bone appearance in cleidocranial dysostosis and osteopetrosis, defective clavicles in cleidocranial dysostosis and pycnodysostosis and erosion of the distal phalanges of the feet and hands in osteopetrosis, pycnodysostosis and acro-osteolysis.

S. Afr. Med. J., 48, 1011 (1974).

PYCNODYSTOSIS

Pycnodysostosis is a term introduced by Maroteaux and Lamy in 1962¹ derived from the Greek *pycnos* (dense), *dys* (defective) and *ostosis* (bone). It is a genetic disorder, inherited as an autosomal recessive trait, and some degree of dwarfism is present. Toulouse-Lautrec is surmised to have suffered from this malady.² Parental consanguinity is noted in more than 30% of cases.³

Patients suffering from this disorder have short fingers and toes with clubbing and typical facies, a large head with frontal and occipital bulging, a parrot-like nose and a receding chin. Often there is an accompanying exoph-

thalmos, and blue sclerae have been noted. There may be a high, grooved palate. Platybasia may be found. There are often poor dental formation and dental caries. Madelung's type of deformity has been reported.

Laboratory findings are usually normal but reduced alkaline phosphatase values and slight hypercalcaemia have been reported. In recent reports cases with anaemia, thrombocytopenia and splenomegaly were described.^{4,5}

Radiological Findings

The most striking radiological finding is increased density of bone. In spite of the bone sclerosis the medullary canals are evident and the tubular bones are usually more delicate in calibre than normal, but normal in shape. There has, however, been a report of a case with splaying of the metaphyseal ends.⁶

There is widening of the anterior fontanelle and skull sutures and there may also be persistent metopic sutures. The parietal bones frequently show evidence of wormian bone formation. The mastoids may be non-aerated. The paranasal sinuses and maxillary bones are hypoplastic. Some hypoplasia of the mandible is usually seen and a striking feature is the almost total disappearance of the mandibular angle. There may be poor dental formation, with a double row of teeth, but permanent teeth usually appear on schedule. The orbital rims may be very dense.

An almost constant finding is some aplasia of the terminal phalanges of the hands and feet. The appearance may or may not be accompanied by shortening of other phalanges, metacarpals and metatarsals. A recent report⁵ states that the absorption most probably occurs after birth. In this particular case radiographs taken on first admission, when the patient was 6 months old, revealed well-formed terminal phalanges, but at 4 years of age they were strikingly atrophic. There may be total aplasia of the clavicle or only hypoplasia of the acromial end of the clavicle.⁶ Agenesis of the first rib has been reported.

There may be S-shaped tibiae or radii, the latter often associated with a Madelung deformity. The vertebrae are dense and of the infantile type. There is frequently lack of closure of the neural arches. There may be spondylolysis, especially of the 5th lumbar component. The pelvis may show shallow acetabula with increase in the angulation of the acetabulum in relation to the perpendicular plane of the body. Coxa valga and coxa vara have both been reported.⁷

Department of Radiodiagnosis, Kalafong Hospital, Pretoria

A. WOLPOWITZ, M.B. CH.B., D.M.R., M.D., Professor

A. MATISONN, M.B. B.CH.

Date received: 11 December 1973.

Case 1

A female patient aged 19 years was admitted to hospital with a fracture of the right tibia after a trivial incident. She was of normal intelligence, small in stature but well-proportioned and her enlarged head had wide-open sutures. She had a parrot-like nose, a receding chin, some degree of proptosis with blue sclerae, short stubby fingers with clubbing, and striation of fingernails.

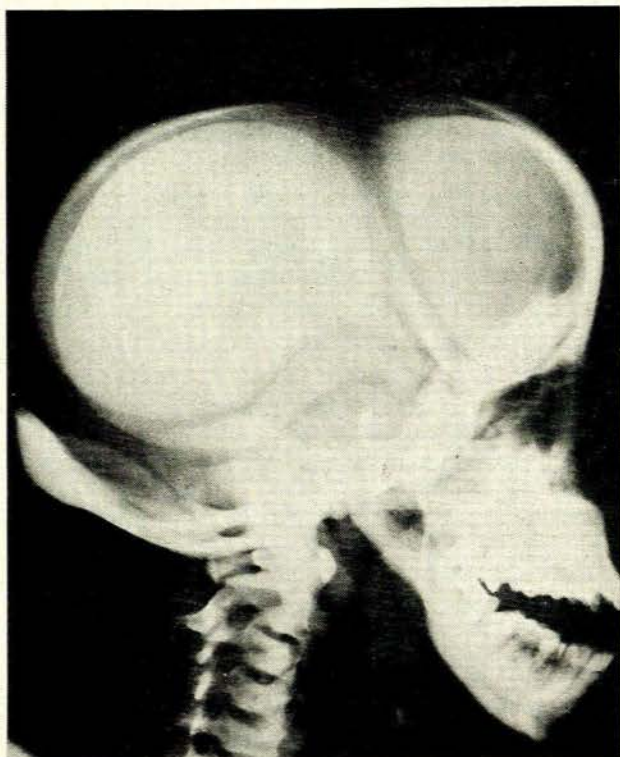


Fig. 1. Case 1. Bone sclerosis, wide sutures and open fontanelles. Non-developed paranasal sinuses. Straightened mandibular angle.

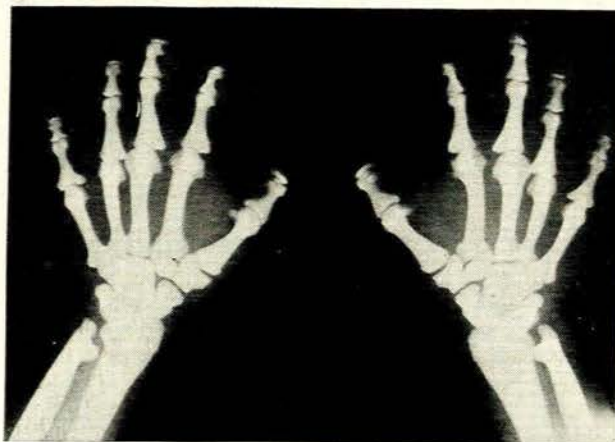


Fig. 2. Case 1. Bone sclerosis. Absorption of terminal phalanges.

The mother stated that the patient was born at term, was a miserable baby with an abnormally big head, cut 3 upper and three lower teeth at 4 months and lost them at 7 months. After this teething was normal.

The patient suffered frequent headaches since childhood and 5 incidents of fracture, viz. left femur, right femur, left tibia and fibula, right tibia and fibula and right tibia. No other member of the family was abnormal and further clinical and laboratory examinations were normal.

Radiological examination showed increased density of bone throughout the whole skeleton except in the spine, where the transverse and spinous processes were of normal texture. The lateral view showed infantile type of vertebral bodies. The pelvis showed no evidence of formation of a sciatic notch.

The skull was sclerotic with wide sutures and open fontanelles. The orbital rims were dense and there was a metopic frontal suture. Wormian bones were noted in the parietal and occipital regions. There was no development of the frontal and maxillary sinuses and minimal aeration of ethmoid, sphenoid and mastoid cells. There was marked reduction of the mandibular angle.

The hands and feet showed absorption of terminal phalanges. An old united fracture of the lower left tibia was noted. There was encroachment of cortical bone upon the medullary cavities but the latter were still recognisable as such. The clavicles were normal.

OSTEOPETROSIS

Osteopetrosis is known by a number of synonyms, viz. Albers Schönberg disease;⁸ osteosclerosis fragilis generalisata; osteopetrosis generalisata; marble bones; chalk bones.

There is failure of absorption of primary spongiosa. Vascular mesenchyma is absent. An enzyme deficiency may be the basis of this condition. The disease is hereditary with a strong familial tendency and a high incidence of parental consanguinity.⁹

Two types of this condition have been described: malignant (childhood), thought to be autosomal recessive and usually fatal; and benign (adult), thought to be autosomal dominant. Individuals attain adulthood and even a full life-span. There may be splenomegaly, hepatomegaly, lymphadenopathy and jaundice. Optic nerve atrophy is common.

Laboratory Findings

The blood picture may range from normal to marked depression of all elements, most commonly normocytic normochromic anaemia and thrombocytopenia. Abnormal cells may be present, such as immature myeloid cells. There is no correlation between the severity of the anaemia and the degree of bone involvement.

There have been reports of hypercalcaemia and raised acid phosphatase levels. An association with chronic hyperparathyroidism has been described, in that excretion of about 80% of the total phosphorus in the urine was found

and therefore the coexistence of hyperparathyroidism seemed logical.

The condition may be recognised *in utero*. Patients usually present with fracture after minimal trauma. There may be a sudden onset of carious teeth and even osteomyelitis of the mandible or maxilla, or both.

Radiological Findings

The bones are uniformly dense without any recognisable distinction between cortex and medulla in the epiphysis, metaphysis or diaphysis. The bone ends are splayed at the sites of maximal growth, indicating an error in modelling. The tubular bones are usually normal in length. Patients frequently present with fractures after minimal trauma. There is rapid healing with abundant normal callus. There may be longitudinal or transverse radiolucent areas in the metaphysis.

The pelvic contours are normal. There may be arcuate bands of normal density in the iliac bones, running parallel to the iliac crests. The vertebrae may be uniformly dense but may present with dense upper, inferior and posterior margins with normal density of the central portion, the so-called sandwich or rugby-jersey appearance. There can also be a vertebra-within-a-vertebra picture. This bone-within-a-bone presentation is also commonly seen in the bones of the wrists, hands and feet.

The appearance of normal density interspersed with sclerotic changes is indicative of periods of reversibility of the underlying abnormality. There have been reports of cases of osteopetrosis with erosion of the distal portions of the terminal phalanges of the hands and feet.^{10,21}

The skull is thickened, mainly at its base. When the vault is involved there are no recognisable diploë. There may be hydrocephalus. The sella is usually small with clubbing of the posterior clinoids. The paranasal sinuses are hypoplastic and the mastoids poorly aerated. The mandible frequently escapes the sclerotic change but dentition may be delayed. The facial bones are thickened. There may be invasion and reduction in size of various cranial nerve foramina.

The mandibular angle may be diminished in osteopetrosis but is not abolished and the anterior fontanelle never persists.

Treatment

It is reported that prednisone benefits the malignant type in that it helps to combat superimposed infections. Others employed splenectomy, with good results, and suggested that the haemolytic process and thrombocytopenia are associated with hypersplenism.

Case 2

Case 2 was a male aged 43 years. The lateral view of the lumbar spine showed the rugby-jersey or sandwich-type of change due to sclerotic changes along the superior and inferior margins of the vertebral bodies.

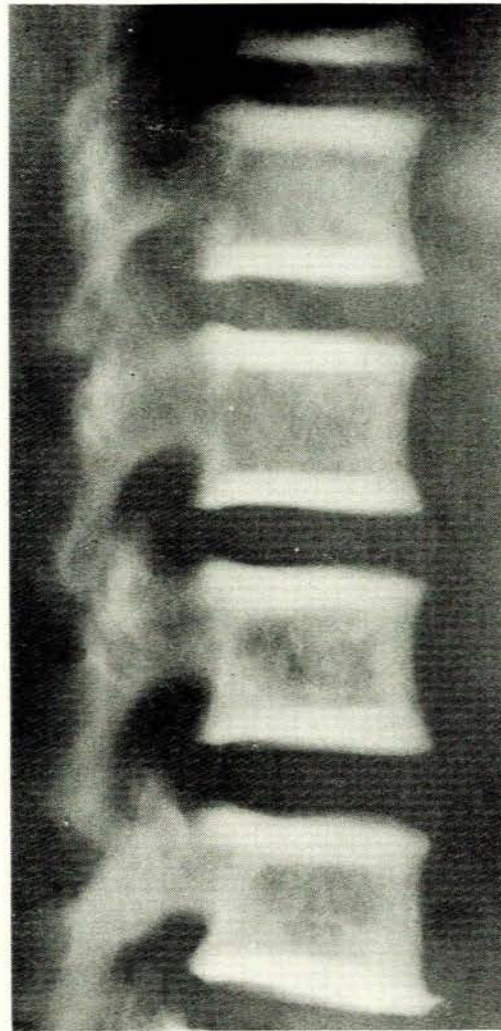


Fig. 3. Case 2. Rugby-jersey type of change in the vertebral bodies.

Case 3

Case 3 was a female aged 7 months. She presented with a painful left leg. The skull showed widened sutures with sclerotic change involving the bones of the base of the skull as well as the orbital margins and facial bones. The sella was small.

The chest radiograph showed dense ribs with clubbed anterior extremities. There were dense vertebral bodies and glenoid regions of the scapulae, the latter having a bone-within-a-bone appearance. The rest of the scapulae appeared normal. The humeri showed transverse lines of translucency proximally and distally.

The spine had a typical vertebra-within-a-vertebra appearance and the pelvis arcuate bands of translucency running parallel to the iliac crests. The ischial and pubic bones also had arcuate lines of translucency.

The femora and tibiae demonstrated sclerotic change with uniform density of bone. There was a fracture of

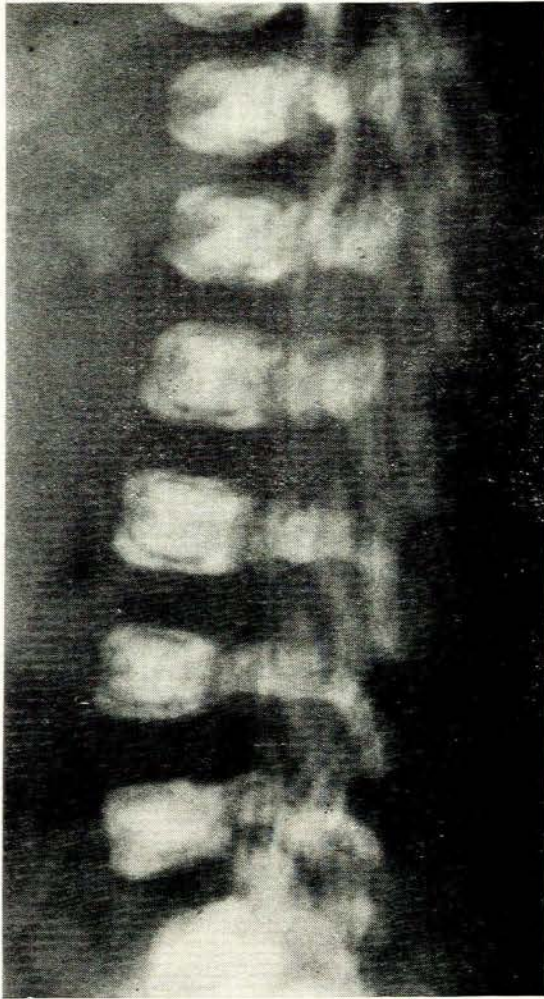


Fig. 4. Case 3. Vertebra-within-vertebra appearance of the spine.

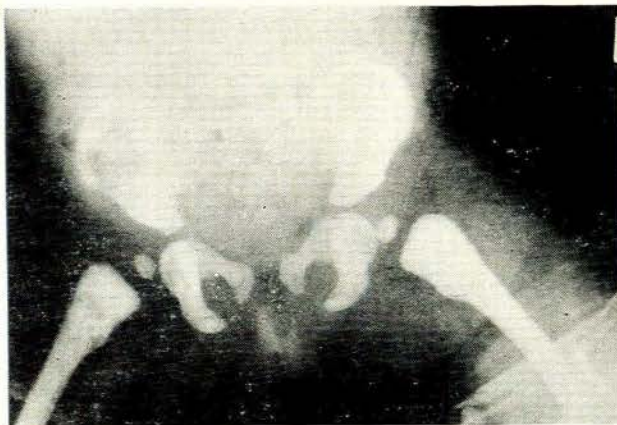


Fig. 5. Case 3. Arcuate lines of translucency in the pelvic bones and transverse lines of translucency in the proximal femora.

the distal left femur. The distal femora and proximal tibiae were flared and the distal metaphyseal margins were irregular. There were transverse lines of translucency involving the proximal and distal extremities of the femora and tibiae on both sides.

Follow-up radiographs showed abundant callus with firm union at the site of the fracture of the left femur.

Case 4

Case 4 was a female aged 52 years. The skull showed densely sclerotic bone involving the vault and the base. The sella was small and there was clubbing of the posterior clinoids. The facial bones and mandible appeared normal in texture. The sinuses and mastoids were well aerated and the mandibular angle was normal.

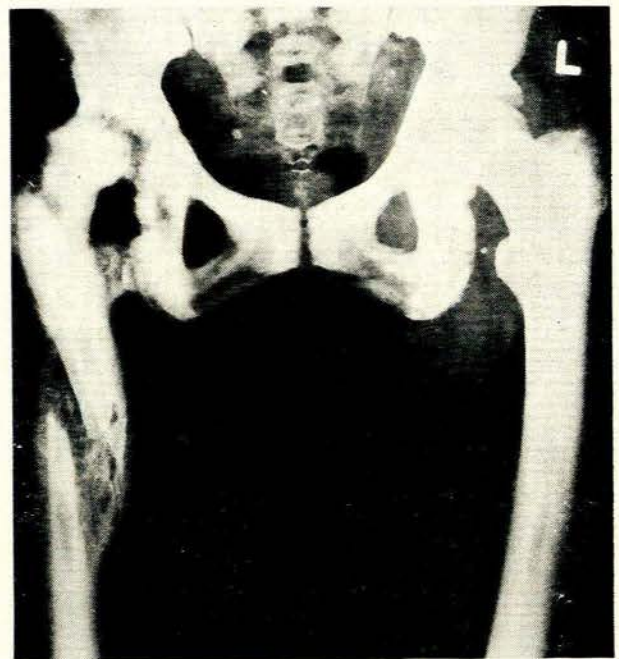


Fig. 6. Case 4. Multiple fractures involving the pelvis and proximal right femur. Note the normal callus formation. A rudimentary medullary cavity is present in both femora.

The thorax demonstrated a dense vertebral column and sclerosis of the ribs. The scapulae showed sclerotic glenoids otherwise appearing normal. The lumbar spine had a vertebra-within-a-vertebra appearance with densely sclerotic vertebral bodies. The transverse processes were not sclerotic but there were fractures of the 4th and 5th right as well as the 5th left transverse process.

The pelvis showed arcuate lines of translucency running parallel to the iliac margins, fractures of the left os pubis and ischium and bilateral femoral artery calcification.

In the right femur old united fractures in the vicinity of the hip joint and a more recent fracture of the shaft with abundant normal callus were noticed. Both femora were densely sclerotic but some demarcation between medulla and cortex could be defined in the mid-diaphysis.

CLEIDOCRANIAL DYSOSTOSIS

In this condition there is mesenchymal or connective tissue failure at the junction of various bones, particularly in midline structures. There thus appear to be superficially, incongruous clavicular defects. Embryologically the mediolateral centres of ossification of the clavicle are separated by a fibrocellular mass. This bone is not identical with a long bone, in that endochondral (cartilagenous) growth is preceded by intramembranous bone formation. If there is a defect in connective tissue it is plausible that this bone is selected rather than tubular bones whose waists are preformed in cartilage anlage.

There is an autosomal-dominant pattern of inheritance. The exact aetiology of the primary error of development is unknown, but the cause is presumably a defect in the parental germ plasm. The blood chemistry is normal.

The characteristic appearance includes a large head and small face, drooping shoulders and narrow chest. Some degree of dwarfism has been reported. Late eruption and impaction of permanent teeth are common but deciduous teeth are usually normal. There may be a high cleft palate.

Radiological Findings

The membranous part of the skull is involved, not the base. There is brachycephaly. The anterior fontanelle and sutures remain open, especially the sagittal suture. Wormian bones adjacent to the lambdoid suture are common. Defective fusion of the frontal bones may extend into the nasal process, accounting for a depression in the bridge of the nose. The foramen magnum is often enlarged. The zygomatic processes of the malar bones may be absent because of failure of fusion. The paranasal sinuses are often hypoplastic. Fusion at the mandibular symphysis may be delayed. The mandible is usually prominent.

Abnormalities of the clavicles are frequent and one or more of the sternal, middle or distal segments of the clavicle, in any combination, may be absent.

There may be defective bone formation around the symphysis pubis and in the spine, with failure of union of the neural arches. A bone-within-a-bone appearance has been reported in the spine. There may be defective ossification of the ischial bones, poorly formed sacrum and coccyx and deformity of the pelvic inlet.

The tubular bones are usually normal but coxa vara has frequently been reported. It is surmised that there is defective ossification of the femoral neck, which may be deformed or absent. Others again reported coxa valga deformity.

There may also be hypoplasia or complete absence of the radius, undertubulation of the tibia, fibula and radius, and increased obliquity of the distal radial and tibial articulating surfaces with some angulation at the wrist and ankle joints.

Abnormalities of the bones of the hands and feet, particularly of the metacarpals and metatarsals, are reported, viz. elongation of metacarpals, especially the second, with the heads of the 3rd, 4th and 5th showing

a steplike shortening. The hands may show multiple accessory ossification centres of the metacarpals and phalanges. Transverse clefts may be present in the distal phalanges and terminal phalangeal hypoplasia. Sprengel's deformity of the shoulder may be present.

Case 5

Case 5 was a female aged 26 years with defective development of clavicles on both sides with non-fusion of the medial and middle segments and the lateral extremities missing on both sides.

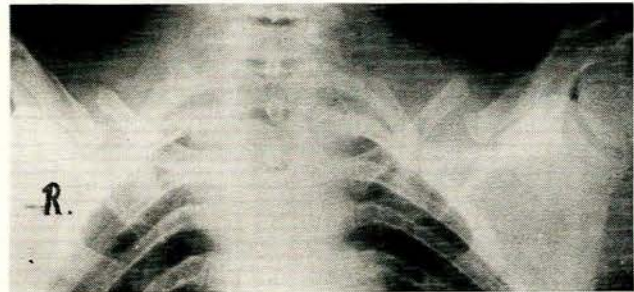


Fig. 7. Case 5. Defective development of clavicles on both sides.

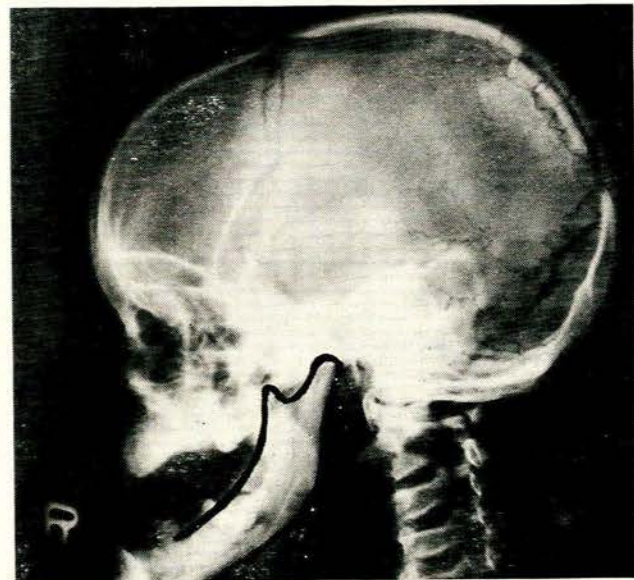


Fig. 8. Case 6. Wormian bones adjacent to the lambdoid suture. Fontanelles open. Poor aeration of paranasal sinuses and mastoids. Straightening of the mandibular angle.

Case 6

Case 6 was a male aged 17 years. The skull showed wormian bones adjacent to the lambdoid suture, open anterior and posterior fontanelles, defective fusion of the

frontal bones extending into the nasal process, poor aeration of the paranasal sinuses and mastoid cells. The mandible was elongated relative to the upper jaw with some diminution of the mandibular angle.

The clavicles showed defective development, being 2 widely separated components. There was scoliosis of the dorsal spine.

Case 7

Case 7 was a male aged 5 months. The skull showed wormian bones and widely separated coronal and sagittal sutures, as well as defective fusion of the frontal bones extending into the nasal process.

There was maldevelopment of the clavicles with 2 central components and absence of the medial and lateral extremities on both sides. There were also non-development of both first ribs, an enlarged thymus, defective bone formation around the symphysis pubis and some splaying of the distal femora.

FAMILIAL IDIOPATHIC ACRO-OSTEOLYSIS

In 1948 Hajdu and Kauntze¹² described a case of cranio-skeletal dysplasia, and in 1950 Harnasch¹³ described a similar case, naming it acro-osteolysis. These cases were examples of non-familial acro-osteolysis. Further cases were reported.¹⁴⁻¹⁶

Acro-osteolysis includes two types—one familial with dominant inheritance and the other non-familial. Cheney,¹⁷ in reviewing the literature, believes that they represent one disease entity. The aetiology is unknown but it is probably a developmental mesodermal abnormality.

The patients have a characteristic facial appearance with some degree of hypertelorism, an upturned nose and protuberant eyes. There is usually some dwarfism which is progressive. A protuberant lower jaw is common.

Radiological Findings

Radiological changes previously described include absorption of the terminal phalanges of the hands and feet, the tufts often said to be spared.¹⁸ Cystic areas of rarefaction and erosions in the proximal and middle phalanges are reported.

Developmental anomalies of the joints of the hands and wrists, valgus deformity and hypermobility at the knee joint, hypoplasia of the proximal radius with subluxation of the radial head, as well as atrophy around the acromioclavicular joint, the margins of the symphysis pubis and along the lateral borders of a deformed sacrum, have been described.

Eventually severe generalised osteoporosis develops with biconcave vertebral bodies and compression fractures at multiple sites as well as basilar impression of the skull. There may be contour defects of the posterior vertebral margins. The skull is usually scaphocephalic. There are open fontanelles and sutures, especially the lambdoid, as

well as persistent metopic suture. Wormian bones are common. The accessory nasal sinuses are poorly developed, there is early loss of teeth and erosion of alveolar margins can be present in the mandible and upper jaw. The maxillae are small and the chin protrudes. Fusion of spinous processes of cervical vertebrae may be seen. There is usually a thin, delicate bone texture with bowing of the tibiae and lack of tubulation and remodelling of diaphysis and metaphysis. Fractures are frequent.

Case 8

Case 8 was a male aged 18 years with a typical facial appearance. The neck and fingers were short and the fingers showed some clubbing with transverse striations of the nails. There was valgus deformity of the knees, and pubic and axillary hair was scanty. No neurological, cardiovascular or abdominal abnormalities were detected. Laboratory investigations, including estimates of urinary mucopolysaccharides, were normal, other than an elevated lactic dehydrogenase reading of 83 IU and an alkaline phosphatase level of 60 IU.

Radiologically the distal phalanges of the feet showed slight resorption. The base of the middle phalanx of the right second toe showed a ball-and-socket epiphysis, and a cystic area was noted in the distal extremity of the proximal phalanx of the left 5th toe. The metatarsals were foreshortened and varus deformity of both feet was demonstrated. The hands showed osteolysis of the distal phalanges. Transverse clefts were seen in the distal phalanges of the 2nd and 5th fingers on the right side, as well as cystic change in the epiphyses of the proximal phalanges of the 2nd and 3rd fingers of the right hand. The 1st metacarpals on both sides and the 5th metacarpal on the left were shortened.

The skull was scaphocephalic, the sutures were open but not widened and the multiple wormian bones were present. Basilar invagination was demonstrated. The anterior and posterior fontanelles were patent. There were bony defects in the superior aspects of both parietal bones. The frontal and maxillary sinuses were undeveloped and there was infantile-type ethmoid and sphenoid sinus formation.

The lumbar and dorsal spine showed osteoporosis and compression fractures of dorsal vertebrae 9 and 12 and lumbar vertebrae 1, 3 and 4.

Case 9

Case 9 was the brother of case 8, 1.5 m tall, very similar in appearance but with a prominent occiput. Laboratory investigations were normal, except for an elevated lactic dehydrogenase (80 IU).

Radiological examination demonstrated an increase in the soft tissue of the distal phalanges of the hands producing clubbing and osteolysis of the distal phalanges of all the fingers, sparing the margins of the tufts in some. Subluxation of the left distal radio-ulnar joint was seen. Small cystic translucencies were present in the distal epiphysis of the ulna and radius. Hypoplasia of the radial

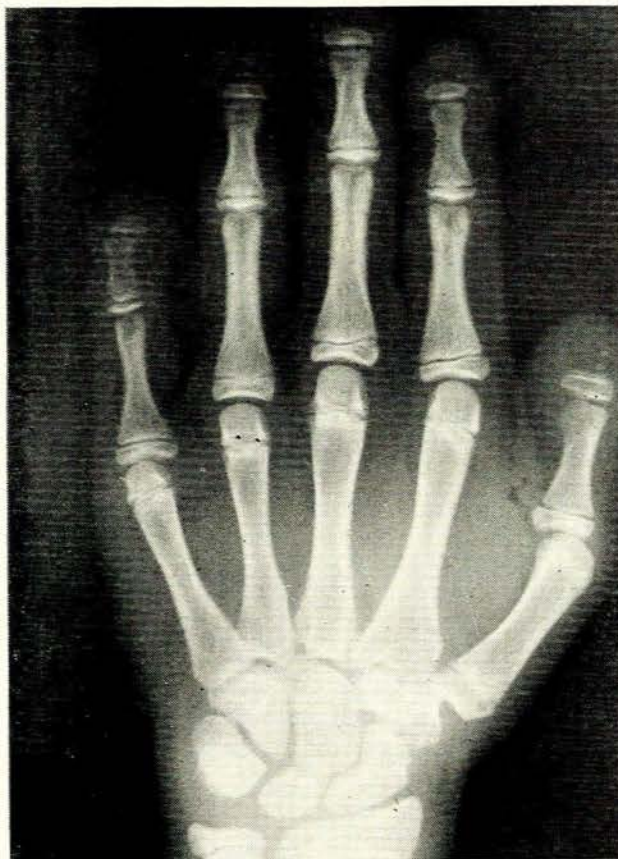

Fig. 9. Case 9. Osteolysis of the distal phalanges of the fingers.

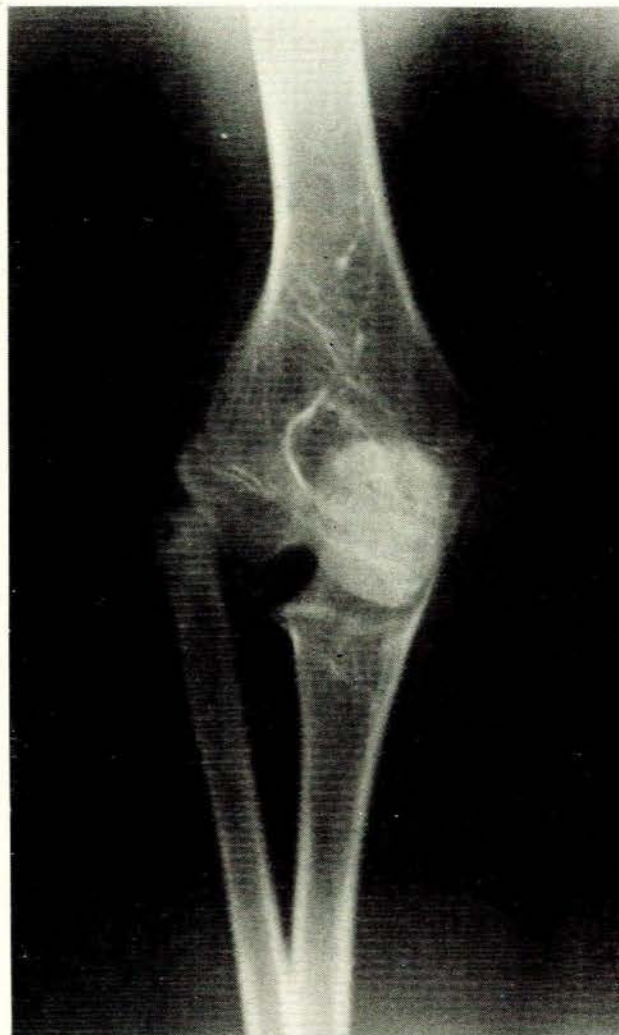


Fig. 10. Case 9. Subluxation of the radius and hypoplasia of the head of the radius and the capitellum.

head and the capitellum with dislocation of the radius on the left side was demonstrated. There was cystic change in the head of the radius.

The feet demonstrated resorption of the distal phalanges not as pronounced as in the hands. The proximal phalanx of the left hallux had a distal and proximal epiphysis with the former divided into two. The sesamoid bone of the right hallux as well as the lateral aspect of the head of the 1st metatarsal showed resorption. Marginal absorption at the proximal interphalangeal joint of the 5th right toe was present. There were transverse clefts in the distal phalanges of both big toes. There were subluxation of the proximal interphalangeal joint of the left little toe and minimal absorption of the calcaneal margins of the cuboid bones.

The skull was scaphocephalic, the lambdoid suture open but not widened, and wormian bones were present around this suture. The frontal sinus was absent and the maxillary sinuses were hypoplastic. A severe degree of basilar invagination and some diminution of the mandibular angle were present.

Family History

The father and mother were not related. The father had died (cause of death unknown), but his photograph showed

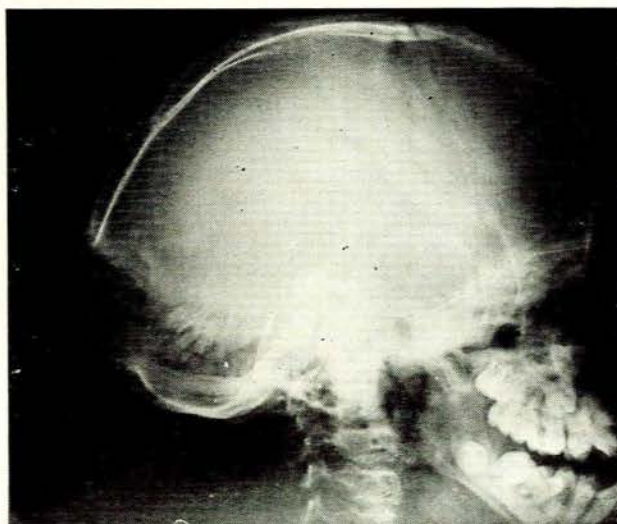


Fig. 11. Case 9. Skull showing severe basilar invagination.

TABLE I. COMPARATIVE SUMMARY

	Alterations in mandibular angle	Bone sclerosis	Open sutures and fontanelles; metopic sutures	Wormian bones	Hypoplastic paranasal sinuses and mastoids	Absorption of terminal phalanges	Fractures after minimal trauma	Flared long bone ends	Disturbance in development of teeth
Pycnodysostosis	Complete disappearance of mandibular angle	Yes. Dense orbital rims. Recognisable medullary cavities. Transverse processes of vertebrae escape	Yes	Yes	Yes	Yes	Yes. Massive callus. Normal healing	No	Yes
Osteopetrosis	No	Yes. Dense orbital rims. Transverse processes escape. Recognisable medullary cavities	Yes	No	No	No	Yes. Massive callus. Normal healing	Yes	Yes
Cleidocranial dysostosis	Diminution of angle	No	Yes	Yes	Yes	No	No	Yes	No
Familial idiopathic acro-osteolysis	Diminution of angle	No	Yes	Yes	Yes	Yes	Yes in spine	No	Yes

a very close resemblance to the facial appearance of his 2 sons. There were 4 children born from this marriage but the girls had no skeletal defects. No details of other members of the family with similar disorders could be obtained.

DISCUSSION

Table I summarises the findings.

Involvement of the mandibular angle may be a persistence of the infantile type of appearance. The mandibular angle develops gradually in normal individuals¹⁹ and in infants and children there is straightening at the mandibular angle. The fact that there are also infantile vertebral bodies in pycnodysostosis may be the clue to a similar state of affairs.

There appears to be general acceptance that the sclerosis in osteopetrosis obliterates the medullary cavities completely. This series indicates marked encroachment but in some instances the medullary areas are recognisable—certainly to the same extent as in the case of pycnodysostosis.

The irregular metaphyseal margins demonstrated in case 3 could have been due to rickets or some similar condition, but were unfortunately only noted after discharge of the patient and follow-up has been impossible.

Although not demonstrated in the present series of cleidocranial dysostosis, the literature reports hypoplasia

or absent radius, transverse clefts in the terminal phalanges of the hands and feet, and terminal phalangeal hypoplasia. These changes were all present in our cases of familial idiopathic acro-osteolysis and the similarity is therefore obvious.

The progressive dwarfism ascribed to acro-osteolysis is attributed to fractures of vertebral bodies secondary to marked osteoporosis from puberty onwards.

REFERENCES

1. Maroteaux, P. and Lamy, M. (1962): *Presse méd.*, **70**, 999.
2. *Idem* (1965): *J. Amer. Med. Assoc.*, **191**, 111.
3. Sedano, H. D., Gorlin, J. G. and Anderson, V. E. (1968): *Amer. J. Dis. Child.*, **116**, 70.
4. Kozlowski, K. and Yu, J. S. (1972): *Arch. Dis. Childh.*, **47**, 804.
5. Balthazar, E., Smith, E. H. and Moskowitz, H. (1972): *Brit. J. Radiol.*, **45**, 304.
6. Elmore, S. M. (1967): *J. Bone Jt Surg. (Amer. vol.)*, **49A**, 153.
7. Dusenberry, J. F. Jun. and Kane, J. J. (1967): *Amer. J. Roentgenol.*, **99**, 717.
8. Albers-Schönberg, H. (1904): *Münch. med. Wschr.*, **51**, 365.
9. Janecki, C. J. and Nelson, C. L. (1971): *Cleveland Clin. Quart.*, **38**, 169.
10. Seigman, E. L. and Kilby, W. L. (1950): *Amer. J. Roentgenol.*, **63**, 865.
11. Moss, A. A. and Mainzer, F. (1970): *Radiology*, **97**, 631.
12. Hajdu, N. and Kauntze, R. (1948): *Brit. J. Radiol.*, **21**, 42.
13. Harnasch, H. (1950): *Fortschr. Röntgenstr.*, **72**, 352.
14. Greenberg, B. E. and Street, D. M. (1957): *Radiology*, **69**, 259.
15. Papavasiliou, C. G., Gargano, F. P. and Walls, W. L. (1960): *Amer. J. Roentgenol.*, **83**, 687.
16. Chawla, S. (1964): *Brit. J. Radiol.*, **37**, 702.
17. Cheney, W. D. (1965): *Amer. J. Roentgenol.*, **94**, 595.
18. Köhler, A. and Zimmer, E. A. (1968): *Borderlands of the Normal and Early Pathologic in Skeletal Roentgenology*, 3rd American Ed. New York and London: Grune & Stratton.
19. Williams, P. L. and Wendell-Smith, C. P. (1966): *Basic Human Embryology*. London and Edinburgh: Thomas Nelson.