

# Measles and its Complications

## A RADIOLOGICAL SURVEY

ANNE G. WESLEY, J. B. SUTTON

### SUMMARY

The radiological features that accompany measles are reviewed. Changes due to viral infection may be complicated by those secondary to bacterial superinfection.

The syndrome of relapsing pulmonary infection after measles is discussed, and studies on the pathogenesis are presented.

*S. Afr. Med. J.*, 48, 1001 (1974).

A variety of radiological features related to measles have been described. These are reviewed and investigations into one complication are presented.

The material for this study was obtained from patients treated in the infectious fevers unit, Clairwood Hospital, Durban, where over 1 200 Black children with complicated measles are admitted annually.

### REVIEW OF THE RADIOLOGICAL FEATURES OF MEASLES

Abnormal intensity of lung markings (Fig. 1) is a classical feature of even the mildest case. These coarse linear striations, which have been described in other viral diseases,<sup>1</sup> radiate from the hilar regions and are due to interstitial reaction consequent upon airway involvement by the measles process.

Prominent hilar shadows are frequent, and result from a combination of hilar adenopathy and blood-vessel congestion, and pleural reaction is often seen in interlobar fissures and peripherally. Both can persist for months.

Radiographic changes may progress to patchy or, less commonly, lobar pneumonia. In local patients giant cell pneumonia is the pathological basis for these radiographic features in about one-third of cases,<sup>2</sup> while secondary bacterial infection is the underlying factor in the rest. The bacterial invaders were studied by means of lung puncture.<sup>3</sup> Coagulase-positive staphylococci were found in two-thirds of the children, and in one-third Gram-negative organisms were also cultured. It is therefore not surprising that many of the complications of measles result from staphylococcal superinfection. Severe bronchopneumonia

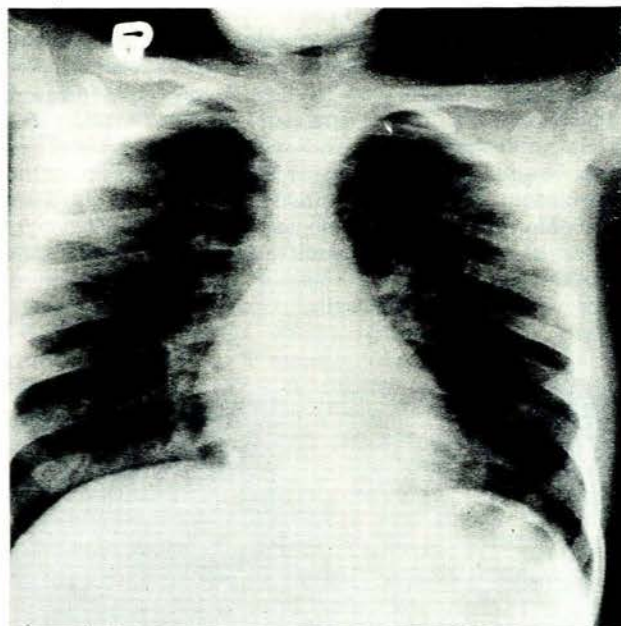


Fig. 1. Hilar lymphadenopathy, increased lung markings and pleural reaction (thickening of horizontal fissure).

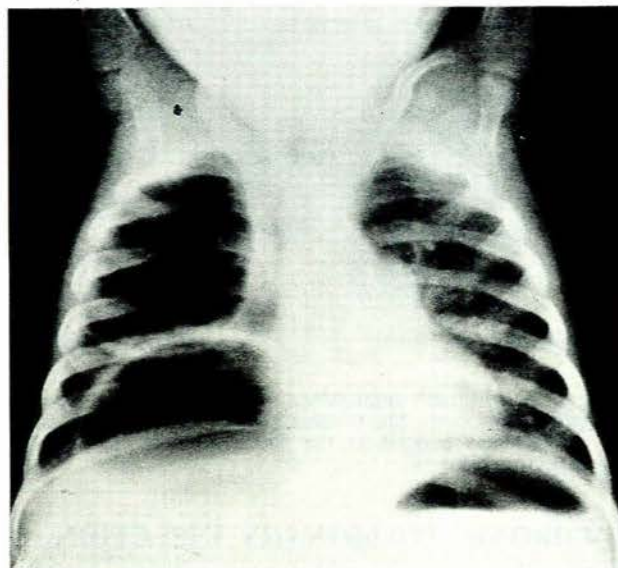


Fig. 2. Large right upper and lower lobe staphylococcal cysts causing some mediastinal displacement to the left.

Department of Paediatrics and Child Health, University of Natal, Durban

ANNE G. WESLEY, M.B. CH.B., M.R.C.P.

Department of Radiology, University of Natal, Durban

J. B. SUTTON, M.B. B.CH., M.MED. (RAD.D.)

Paper presented at the South African Radiological Congress held in Durban on 1-4 September 1972.

and pneumatoceles (Fig. 2) are not infrequent, and lung abscesses also occur.

Effusions of serous fluid have been ascribed to measles and exacerbation of pulmonary tuberculosis is well recognised.

Cardiac failure, secondary to pneumonia or to myocarditis, is sometimes accompanied by an enlarged heart shadow on radiography, with or without pulmonary congestion.

Spontaneous mediastinal emphysema is a rarely recorded complication of measles (Fig. 3). A recent review of the literature revealed only 19 cases.<sup>4</sup> Among our patients 6 cases have been seen over the past 3 years. The accepted pathogenesis is rupture of the alveoli due to a pressure gradient between air sacs and perivascular sheaths, which permits an air leak into the interstitial tissue with dissection along blood-vessels to the mediastinum and thence to subcutaneous tissues. Pneumothorax is frequently associated. The factors present in measles are constant coughing, which lowers intrathoracic venous pressure and increases intrapulmonary pressure, and inflammation, which weakens alveolar walls.

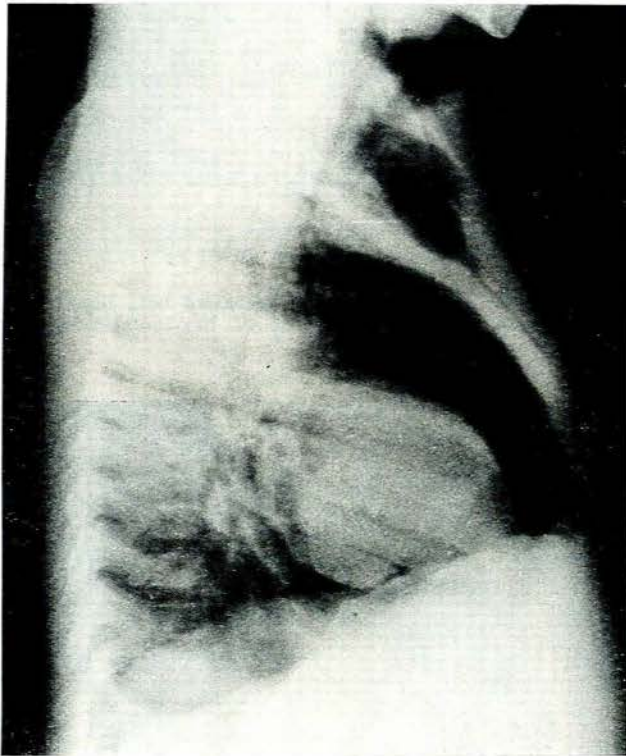


Fig. 3. Mediastinal emphysema well seen in the retro-sternal region (note the thymus gland). Large collections of air are also present in the soft tissues of the upper chest cavity and neck.

### CHRONIC PULMONARY INFECTION

The complication of measles which probably gives rise to the most concern is a stubborn relapsing pulmonary

infection. Clinical signs of chest infection may recur for many months, accompanied on radiography by flitting pulmonary shadows and fluctuating hilar adenopathy (Figs 4 and 5). Eventually most patients recover, but some develop bronchiectasis.

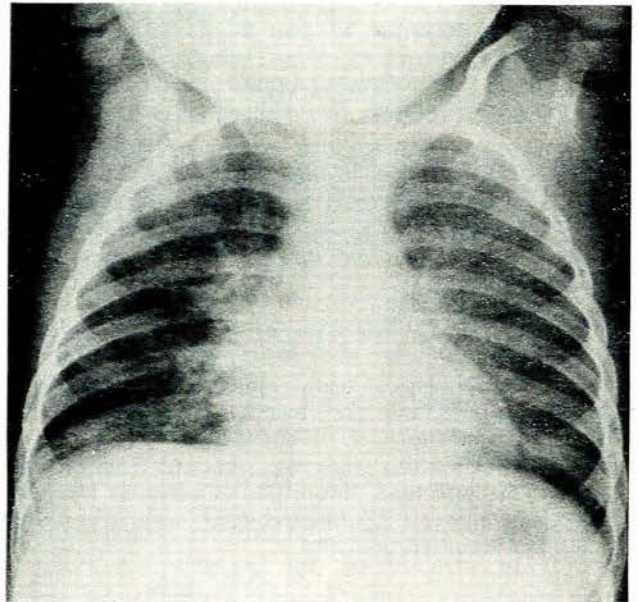


Fig. 4. Bilateral perihilar, some right middle lobe and left lower lobe consolidation.

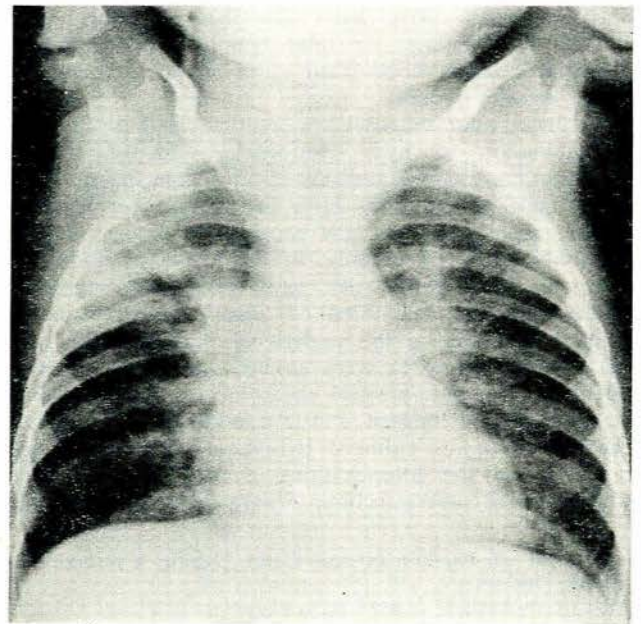


Fig. 5. Generalised bilateral consolidation. Hilar enlarged, probably due to lymphadenopathy and surrounding lung infection.

## Pathology

The evolution of this chronic pulmonary syndrome is not well documented, for these patients seldom come to necropsy. In our cases histological examination demonstrated features of established bronchiectasis (sacculated airways with hypertrophic epithelium) and, in addition, concurrent acute bronchitis (destruction of the epithelium and muscle coat of the small airways, with accumulation of polymorphonuclear leucocytes). This indicates that fresh infective damage occurs months later.

## STUDIES IN PATHOGENESIS

### Stagnation of Bronchial Secretions

The persistence of bacteria in the bronchi for long periods after measles has not been adequately explained. A necrotising bronchitis is typical of the acute disease with destruction of ciliated epithelium, obstructive oedema and exudation.<sup>5</sup> Re-epithelisation is usually normal, but may result in abnormal non-ciliated cells.<sup>6</sup> Inefficient removal of bronchial secretions conducive to secondary bacterial growth could result, which in turn may cause epithelial damage, the accumulation of secretions and further persistence of bacteria.

**Method.** A radio-opaque non-absorbable contrast medium was used as a marker to follow the removal of secretions from the respiratory tree, 2-4 ml being instilled into the trachea via an endotracheal tube. X-ray films were taken immediately and 2 hours after instillation, and then daily, to estimate the time taken for elimination of the contrast by natural processes.

**Results.** Thirteen children, all with chronic chest infection 2-12 months after measles, were studied in this manner. The opaque media entered the bronchi as far as the fourth generation, and all were coughed up within 24 hours, except in 2 patients where the remnants remained for 48 hours.

**Discussion.** Ideally the contrast medium should be of similar consistency to respiratory mucus. Although viscous Lipiodol (6 patients), Ultrafluid Lipiodol (2 patients), Myodil (3 patients) and Dionosil (2 patients) were all used, the time taken for the removal of the various media was comparable. With the least viscid media some alveoli also filled, in which event the contrast persisted at this level for several days (maximum 2 weeks). Transport from alveoli is known to be extremely slow.

The marker was efficiently removed from the bronchi in all children with no pocketing of contrast, as might be expected if there was significant disorganisation of the mucociliary apparatus. Although normal controls were not available for comparison, stagnation of mucus is unlikely to initiate the persistent bacterial colonisation following measles.

### Prolonged Immunological Defect

The state of immune mechanisms in these patients might contribute to continuing acute bacterial damage, as cell-mediated immunity is depressed by the measles virus. This usually lasts a few weeks,<sup>7</sup> but occasionally may persist for periods of up to a year, as shown by anergy to the tuberculin test.<sup>8</sup> The children with long-standing infective pulmonary sequelae may be among these.

**Method.** The competence of cell-mediated immunity in patients with the chronic chest syndrome was tested by the capacity to react to dinitrochlorobenzene (DNCB) sensitisation of the skin.

**Results.** The results obtained in 5 patients studied demonstrated that 3-8 months after measles 4 patients failed to react to DNCB sensitisation and 1 patient converted to positive in the fifth month, after which his symptoms improved and his chest radiograph cleared.

These preliminary results suggest that children with chronic chest infection are among those whose measles-induced immunological defect persists for prolonged periods. Work on this aspect is continuing.

In summary, the possible pathogenesis of the chronic pulmonary syndrome begins with acute necrotising bronchitis becoming secondarily infected. Because of prolonged depression of cell-mediated immune mechanisms the bacteria persist and cause continuing bronchial wall destruction, recurrent symptoms and persistent radiological abnormalities.

We should like to thank Dr M. Schonland for her interpretation of histological specimens, and Dr M. Parent, for assisting in the immunological studies.

#### REFERENCES

1. Becroft, D. M. O. (1967): *J. Clin. Path.*, **20**, 561.
2. Schonland, M. (1972): M.D. thesis submitted to the University of the Witwatersrand.
3. Wesley, A. G., Sutton, J. B. and Widrich, A. J. (1971): *S. Afr. Med. J.*, **45**, 1402.
4. Bloch, A. and Vardy, P. (1968): *Clin. Pediat. (Phila.)*, **7**, 7.
5. Robbins, F. C. (1962): *Amer. J. Dis. Child.*, **103**, 266.
6. Field, C. E. (1949): *Pediatrics*, **4**, 231.
7. Sellmeyer, E., Bhattay, E., Truswell, A. S., Meyers, O. L. and Hansen, J. D. L. (1972): *Arch. Dis Childh.*, **47**, 429.
8. Kipps, A. (1966): *S. Afr. Med. J.*, **40**, 104.