

# Fat Embolus—The Post-Traumatic Syndrome

N. M. GOODWIN

## SUMMARY

Attention is drawn to the frequent occurrence of respiratory distress in patients with non-thoracic trauma. The relation of these findings to the 'fat embolus syndrome' or 'post-traumatic syndrome' (PTS) is considered. The typical findings in PTS are described and consideration is given to prophylaxis and treatment. The differential diagnosis is discussed.

*S. Afr. Med. J.*, 48, 995 (1974).

The increasing incidence of road traffic accidents has led to greater numbers of severely injured patients in our hospitals every year. Improvements in transport, resuscitation and operative management now result in the survival of many cases of trauma who would previously have died. Prominent as a late cause of mortality after trauma is a syndrome which has been attributed to fat embolism. It is the purpose of this article to focus attention upon this condition.

Clinical presentation generally follows a set pattern. Most patients have a history of trauma within the previous 24-48 hours which has involved the fracture of long bones. The classical features first described by Van Bergman in 1873 and Christian Finger in 1879, are petechiae, cyanosis, tachypnoea, pulmonary râles and deterioration in the level of consciousness.

The precise aetiology of the condition is as yet undetermined, although the experience of many workers, in particular the American army medical units in the Korean and Vietnam wars,<sup>1</sup> has done much to increase awareness of this complication and to suggest possible aetiological factors. As a result of these investigations, it is probably advisable to speak of the post-traumatic syndrome (PTS) rather than fat embolism.

Although mortality from fully developed PTS approaches 85%,<sup>2</sup> there is substantial evidence that it can be reduced by early recognition and intensive treatment. The diagnosis of PTS should be considered in any patient who, after trauma, develops pyrexia, tachycardia, sensorium deficit, petechiae or tachypnoea. The diagnosis is confirmed by finding a reduced oxygen tension in arterial blood,<sup>3</sup> and a fall in haematocrit. Abnormality of chest X-ray film, consisting of fluffy infiltrates and loss of definition of pulmonary vascular markings, are a common but not invariable feature of PTS.

Department of Anaesthetics, University of Natal, Durban  
N. M. GOODWIN, M.B. B.S., D.A., F.F.A. R.C.S., Principal  
Anaesthetist in charge of Addington Hospital Intensive Care Unit

Paper presented at the South African Radiological Congress held in Durban on 1-4 September 1972.

In view of the high mortality attendant upon failure of early recognition of PTS, it is imperative that this complication be constantly kept in mind by those in charge of trauma victims. Regular estimates of lung function, including, if possible, blood gas analysis of arterial blood, can do much to provide early warning, since the lung is a primary target organ in this condition.<sup>4</sup>

## LOCAL CLINICAL EXPERIENCES

Over the past two years particular attention has been given to the problem of the post-traumatic lung at Addington Hospital, Durban. During the 12 months from October 1970 to September 1971, 17 patients (aged 16-76 years) with fully developed PTS were seen, two of whom died. From October 1971 to September 1972 only two classical cases were seen, but early cases are detected almost weekly in the intensive care unit or orthopaedic wards, the patients suffering from mild respiratory distress with blood gas analysis showing moderate falls in oxygen tension (60-80 mmHg). Therapy with oxygen, blood transfusion, and infusion of low molecular weight dextrans seem to arrest and reverse the changes that lead to PTS. The exact reason for the efficacy of this form of treatment is not fully understood, but it is suggested that the increase in available oxygen breaks the vicious circle shown in Fig. 1.

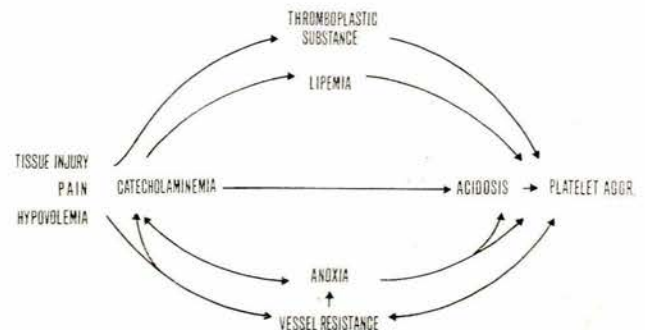


Fig. 1. Vicious circles which may explain the syndrome ascribed conventionally to fat embolism (after Grüner<sup>5</sup>).

## TYPICAL CASE HISTORY

A young man aged 19 years sustained a closed fracture of the femur and a compound fractured tibia in a motorcycle accident. After initial resuscitation he was well for 24 hours, but then complained of increasing shortness of breath. On examination he was slightly disorientated, had a respiration rate of 40/min, was cyanosed, and petechial haemorrhages were visible on both flanks. The pulse rate was 140 beats/min, blood pressure 130/80 and crepitations



were audible all over the lungs. Relevant laboratory investigations showed: haemoglobin 9.6 g/100 ml; platelets 40 000/mm<sup>3</sup> and fat in the sputum and urine. Arterial blood gas analysis revealed considerable reduction in oxygen tension despite the hyperventilation. The chest X-ray film showed small fluffy opacities throughout both lung fields, suggestive of pulmonary oedema, but without the typical 'bats-wing' appearance (Fig. 2). Vigorous therapy, including controlled ventilation incorporating expiratory pressure (PEEP), and massive doses of steroids for 5 days, resulted in gradual regression of the signs and symptoms (Figs 3 and 4).

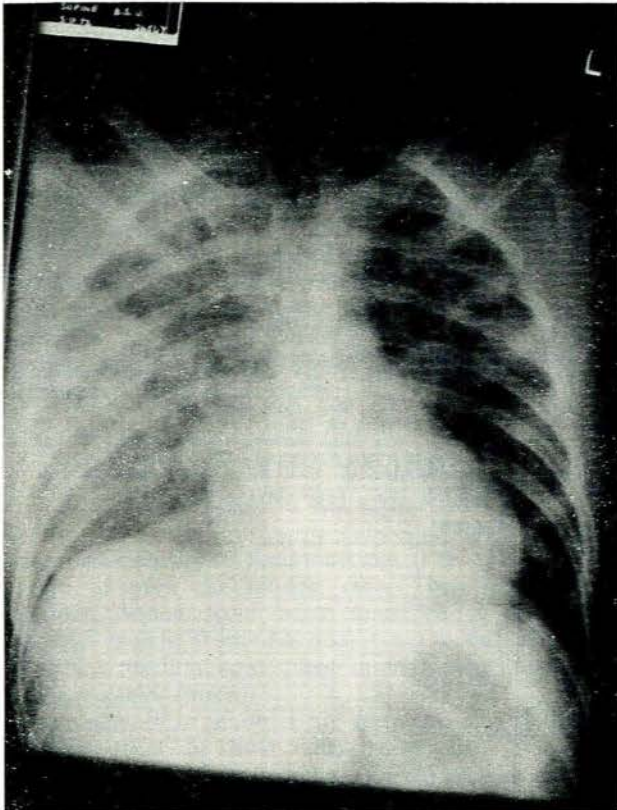


Fig. 2. Twenty-four hours after trauma.

### Differential Diagnosis

Naturally not all cases of breathlessness or other pulmonary signs and symptoms after injury are due to PTS, and the following conditions should also be considered.

**Pneumothorax** is usually associated with rib injuries and is frequently present when the patient is first seen, but may also occur as a late complication. The classical signs are hyper-resonance, absence of breath sounds and the pathognomonic X-ray film appearance. Bilateral pneumothorax may, however, cause confusion.

**Lung contusion** is much more common than previously thought, and is the main cause of hypoxia following crush injury to the chest. Contusions of the lung can occur without fractures of the rib cage, especially in

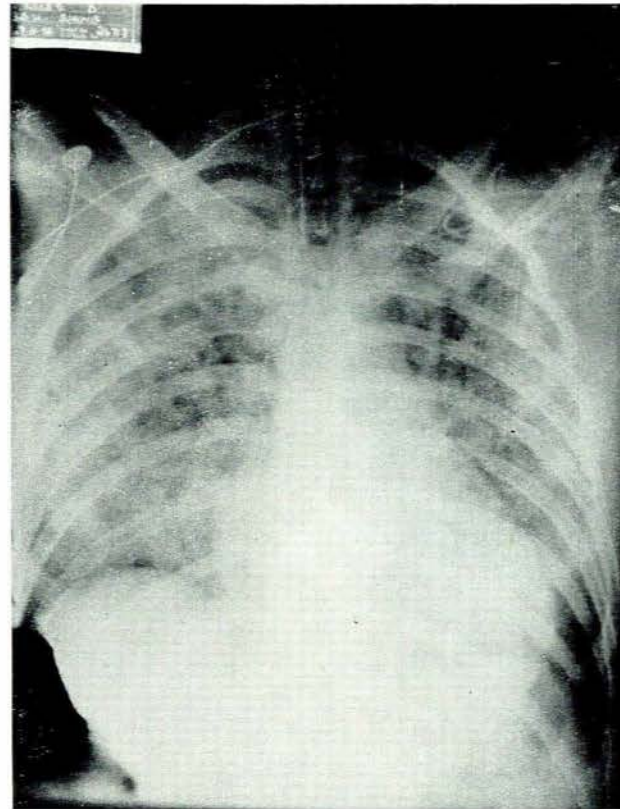


Fig. 3. Two days later.

young persons. The differentiation from PTS can usually be made on the presence of thoracic cage trauma and the frequently unilateral X-ray film findings.

**Over-transfusion** leading to cardiac failure and pulmonary oedema produces a clinical picture similar to PTS.

Diuretic therapy in the former almost always produces immediate and lasting improvement, whereas the latter is not improved—the signs and symptoms persist for several days.

**Aspiration pneumonia** may be suspected, particularly if the patient has been unconscious. The findings are usually unilateral and confined to the classical aspiration segments.

**Diffuse bronchopneumonia** produces a clinical and roentgenological picture which may be very difficult to distinguish from PTS. The patient with infection will, however, show more signs of toxicity and a leucocytosis, and culture of the sputum may reveal the causative organism.

**Atelectasis** and sputum retention are common in elderly injured people and in those suffering from head injuries; they often progress to infection and must be vigorously treated with physiotherapy.

**Obesity** in its grossest forms may be a cause of respiratory failure. One 20-year-old patient was so fat that he was unable to breathe or cough adequately when lying flat in bed with his femur in traction. He developed sputum

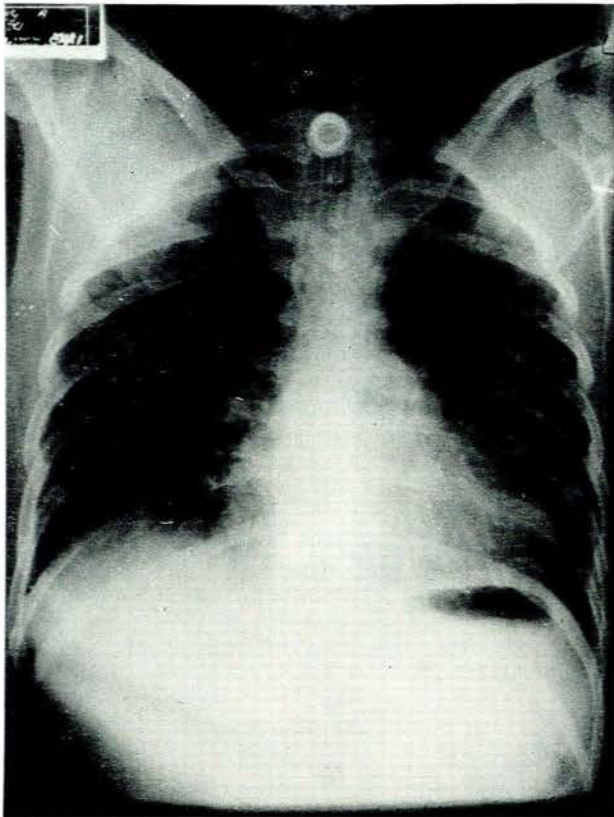


Fig. 4. After 9 days' treatment.

retention and infection and required artificial ventilation for nearly 2 weeks.

### Treatment

The main cause of death in most cases of PTS appears to be hypoxia and thus oxygen therapy is of paramount importance. Initially it may be sufficient to give O<sub>2</sub> by mask or nasal catheter, but in severe cases intubation and high oxygen concentrations, together with artificial ventilation (employing positive end expiratory pressure), may be necessary.

Many authorities consider that disseminated intravascular coagulation may be of significance in this syndrome<sup>5,6</sup> and advocate heparinisation of the patient. This identical therapy has also been suggested in order to mobilise the fat emboli.<sup>7</sup>

The use of steroids in pharmacological doses,<sup>7,2</sup> and of Trasylol,<sup>8</sup> has been recommended. Low molecular weight dextran<sup>9</sup> is frequently used both for the prophylaxis and treatment of PTS.

However, of all these forms of therapy only direct measures to improve oxygen delivery are of indisputable value.

### REFERENCES

1. Collins, S. A. (1971): *Ann. Surg.*, **171**, 595.
2. Ashbaugh, O. C. and Petty, T. L. (1966): *Surg. Gynec. Obstet.*, **123**, 493.
3. Ross, A. P. J. (1970): *Ann. Roy. Coll. Surg. Engl.*, **46**, 159.
4. Pettier, L. F. (1967): *Surgery*, **62**, 756.
5. Hallenker, B. (1970): *Acta path. microbiol. scand.*, **78A**, 432.
6. Grüner, O. P. N. (1971): *Acta chir. scand.*, **137**, 739.
7. Liljedahl, S. and Westermark, L. (1967): *Acta anaesth. scand.*, **11**, 177.
8. Gurd, A. R. (1972): *New Aspects of Trasylol Therapy*, vol. 5, p. 137. Stuttgart: Schattauer.
9. Grüner, O. P. N. (1971): *J. Oslo Cy Hosp.*, **21**, 81.