

# Transkei Foot

P. A. SCHWARTZ, D. SHLUGMAN, G. DAYNES, P. BEIGHTON

## SUMMARY

An epidemiological investigation of bone and joint abnormalities in a Xhosa population revealed 6 females with a condition characterised by marked lateral deviation of the fifth toes. This disorder does not seem to have been previously described, and we therefore propose that it should be named 'Transkei foot'. The pathogenesis of the condition is obscure, but it is possible that it has a genetic basis.

*S. Afr. Med. J.*, 48, 961 (1974).

During the course of an epidemiological investigation of bone and joint disorders in a Xhosa community in the Transkei, several individuals with a peculiar deformity of the feet were observed.

This condition, which may be familial, does not seem to have been previously described and we have therefore documented it in this article. A suitable name for the condition would be 'Transkei foot'.

## METHOD

The feet of 1 085 individuals, inhabitants of two villages near Tsolo in the Transkei, were examined. The respondents were members of the Mpondomise tribe, of the Xhosa ethnic group. Full details of demography and methodology will be published elsewhere.<sup>1</sup> Six female respondents were found to have bizarre abnormalities of their feet. They were investigated in detail, and radiographic and family studies were undertaken.

## FEATURES OF 'TRANSKEI FOOT'

The affected females, whose ages ranged from 42 to 69 years, had marked bilateral displacement of the fifth toes, the angle of deviation from the midline varying from 60° to 80° (Fig. 1). There were no changes in the skin, and, apart from the deformity, the toes were normal. In particular, there was neither a neurological nor a vascular deficit. The disorder was painless and caused no disability. All respondents were adamant that the condition had been present in childhood and none claimed that it had progressed. None of them had ever worn boots or shoes.

Comprehensive clinical examination failed to reveal any

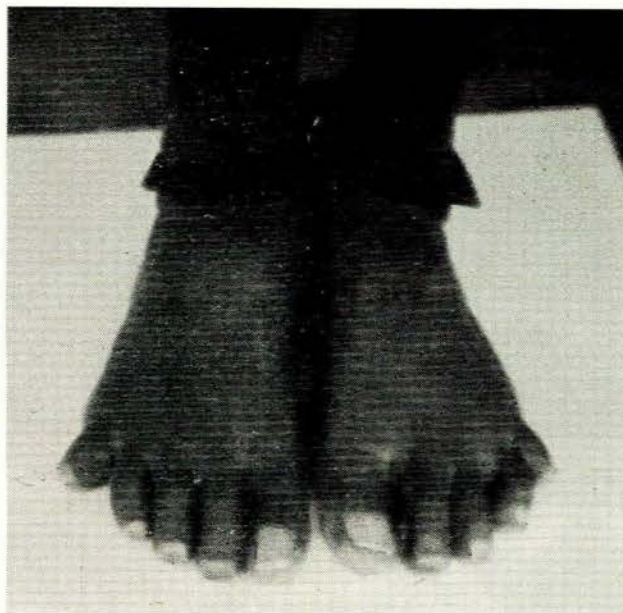

Fig. 1. Lateral deviation of the fifth toe of an affected female.

other abnormality. There was no evidence of rheumatoid arthritis, leprosy, ainhum, or other degenerative or inflammatory conditions.

Radiographic studies demonstrated that the maximum deviation of the joint occurred at the proximal interphalangeal joint (Fig. 2). The bony structure of the feet was otherwise normal and there were no radiographic changes in the hands, pelvis or lumbar spine.

The condition is well known in the community, but attracts little attention and has no social implications. The deformity is not regarded as an 'ill omen', the individual's standing in the community is not jeopardised, and chances of marrying are not affected.

## FAMILY STUDIES

Two patients were mother and daughter, and two other deceased females in this kindred were also said to have been affected. In a second kindred, a history was obtained of the disorder occurring in 3 deceased individuals (see pedigrees, Fig. 3). The other 4 patients were all certain that one of their parents had been affected, and family studies produced evidence to support these contentions. However, due to death or emigration, neither the progenitors nor the offspring of the respondents could be examined.

Five of the 6 respondents were not directly related to one another. However, as there was little marriage outside

Department of Human Genetics, University of Cape Town

P. A. SCHWARTZ, *Medical Student*

D. SHLUGMAN, *Medical Student*

P. BEIGHTON, *Professor*

St Lucy's Hospital, Tsolo, Transkei

G. DAYNES, *Chief Medical Officer*

Date received: 19 December 1973.

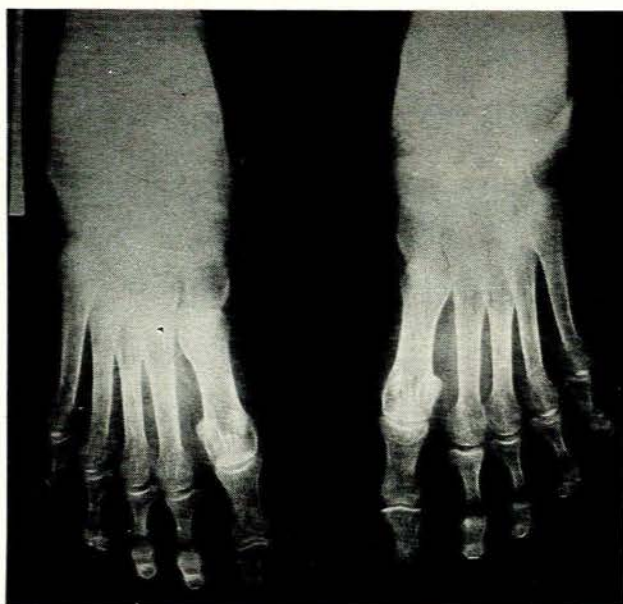


Fig. 2. Radiograph of the feet of an affected female. The maximum deviation occurs at the proximal interphalangeal joint.

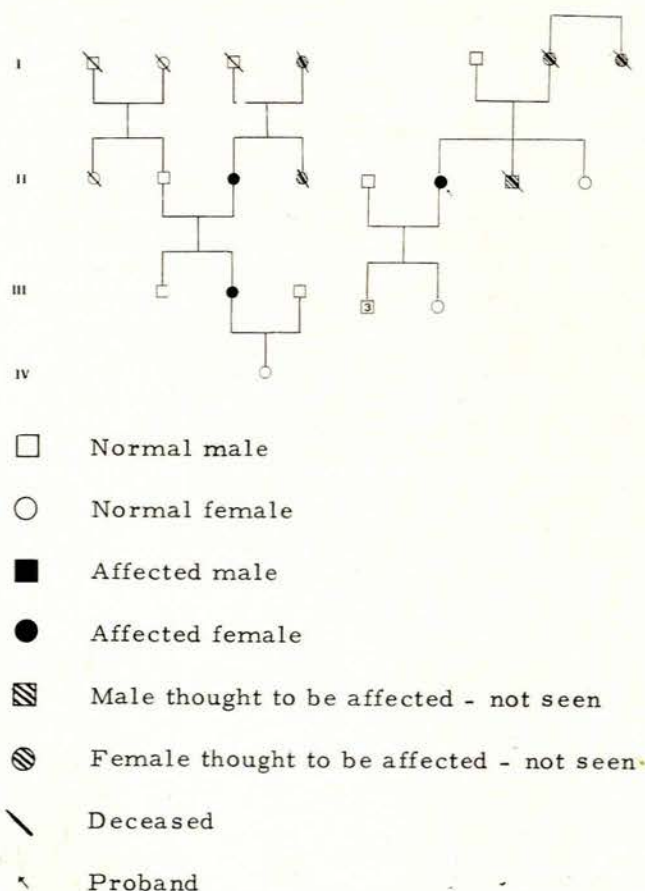


Fig. 3. Pedigrees. Two familial aggregations of Transkei foot.

the community, it is quite possible that all the affected individuals had shared common ancestors.

## DISCUSSION

A large number of genetically determined disorders are expressed as minor malformations of the extremities,<sup>2</sup> and there is no reason to suppose that, even now, they have all been delineated. Epidemiological investigations of populations living in remote places or in areas without doctors, will probably permit recognition of similar new disorders.<sup>3</sup> The 'ostrich-footed men' of the Wadoma people of the Zambesi valley, and the Mseleni joint disease of Northern Zululand, represent situations of this type.<sup>4</sup>

Although ainhum is relatively common in the Transkei,<sup>5</sup> and other foot abnormalities such as Apert's syndrome and phocomelia were encountered during the course of the survey, the clinical features of Transkei foot were sufficiently clearcut to permit differentiation from these conditions. On this basis, we have no hesitation in suggesting that it is a separate entity.

The pathogenesis of Transkei foot is obscure, but in view of the proved occurrence in a mother and daughter, and the positive family histories in all affected individuals, it is possible that it is the result of a single dominant gene. However, the family aggregation could also be explained on a basis of exposure to a common environmental agent rather than to genetic factors.

There are many explanations for the fact that the condition was observed exclusively in females. These include chance, deficiency of males in the population due to labour migration, selective exposure of females to some unknown environmental determinant, and the presence of an anomalous genetic situation. However, until further family studies are undertaken, further speculation is fruitless.

Transkei foot is a harmless deviation from the normal, but, as the Xhosa people become increasingly sophisticated and the wearing of shoes becomes an accepted convention, orthopaedic problems may be anticipated. An isolated individual with Transkei foot would present a diagnostic problem, but awareness of the existence of the disorder and of the characteristic manifestations facilitates recognition. Assessment of the 6 affected individuals permitted appreciation of the range of severity of the condition.

The delineation and documentation of a new disorder represents the first step in the elucidation of its pathogenesis. It is for this reason that we have recorded our observations on this unusual condition, for which we suggest the term 'Transkei foot'.

The survey was supported by a grant from the South African Medical Research Council.

## REFERENCES

- Daynes, G. (1973): *S. Afr. Med. J.*, **47**, 320.
- McKusick, V. A. (1971): *Mendelian Inheritance in Man*, 3rd ed. Baltimore: Johns Hopkins Press.
- Beighton, P., Solomon, L., Soskolne, C. L. and Sweet, B. (1973): *Ann. Rheum. Dis.*, **32**, 346.
- Fellingham, S. A., Elphinstone, C. D. and Wittman, W. (1973): *S. Afr. Med. J.*, **47**, 2173.
- Daynes, G. (1974): *Ann. Rheum. Dis.* (in press).