

Gastric Mucormycosis in a Diabetic Patient

I. P. L. DANNHEIMER, W. FOUCHE, C. NEL

SUMMARY

A fatal case of gastric mucormycosis in a 46-year-old diabetic is described. The pathological findings at laparotomy and postmortem examination are discussed.

An interesting feature was a massive splenic infarction.

S. Afr. Med. J., 48, 838 (1974).

The *Mucoraceae*, especially *Rhizopus*, members of the class *Phycomycetes*, are ubiquitous soil saprophytes which complicate malignancy, diabetic acidosis, prolonged steroid and antibiotic therapy and leukaemia. These opportunistic fungal infections are frequently fatal and often only diagnosed at necropsy.

In 1943 Gregory *et al.* described the first case of mucormycosis, and in over 200 cases⁷ described in the literature, death was related to the infection in about half of these. Cranial, digestive, pulmonary and systemic involvement has been reported due to *Rhizopus*, *Absidia* and *Mucor*.²⁻⁵ Other members are solely subcutaneous phycomycoses.

CASE REPORT

A 46-year-old Black diabetic was hospitalised because of increasing peri-umbilical pain, a dry mouth and malaise. Diabetes mellitus and liver cirrhosis had been discovered one month earlier, and the patient had been given 70 units of lente insulin and Insoral TD daily.

On admission he was severely ill, dehydrated and slightly confused (keto-acidotic with blood sugar 562 mg/100 ml). The liver was 3 fingers palpable, with a fine nodular surface. On therapy the confused state continued and a paralytic ileus set in. On day 8 a laparotomy was performed. The whole abdomen was filled with a thick, dark, pus-like fluid, but no visceral perforation was found. Two big, roundish, black areas (Fig. 1) could be seen on the stomach surface. He died on the fourth post-operative day.

NECROPSY FINDINGS

The stomach showed black discoloration of the mucosa as well as numerous fairly well-circumscribed necrotic areas of varying size, which, microscopically, were large areas of infarction involving mainly the mucosa and submucosa.

H. F. Verwoerd Hospital, Pretoria

I. P. L. DANNHEIMER, M.MED. (INT.)

W. FOUCHE, D.C.P.

C. NEL, M.B. CH.B.

Date received: 11 October 1973.

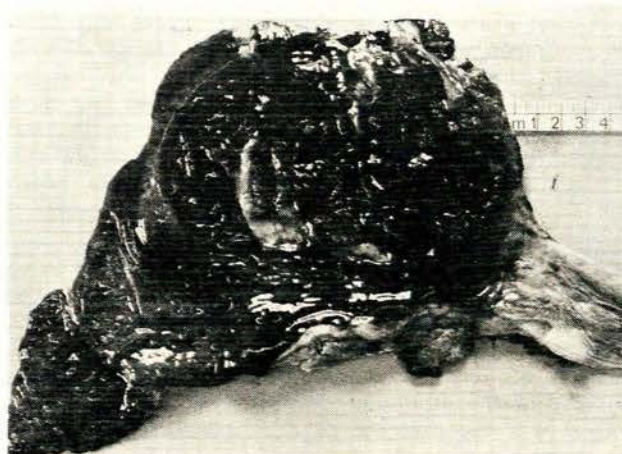


Fig. 1. Stomach showing large necrotic areas.

Numerous fungal elements with non-septate hyphae and branching at obtuse angles were present in the necrotic tissue and in the lumina and walls of submucosal arteries and veins (Fig. 2). Septic thrombi were present in submucosal arteries.

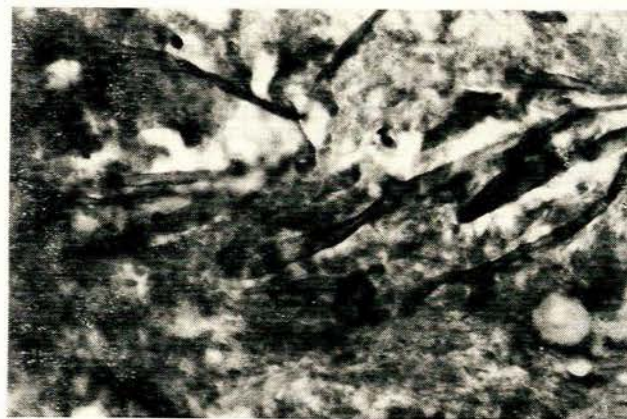

Fig. 2. Fungal elements with non-septate hyphae and branching at obtuse angles present in the necrotic tissue.

The liver (mass 2 500 g) appeared rusty-brown in colour and was finely nodular. Massive haemosiderin deposits were present in the Kupffer cells and portal tracts. The features were those of siderosis and micronodular cirrhosis complicated by oesophageal varices. Small infarcts were present, and septic thrombi containing fungal elements could be demonstrated in the portal veins.

The spleen (mass 670 g) was brown in colour due to siderosis, and showed massive infarction due to a recent thrombus in the splenic artery. Fungal elements were present in the infarcted tissue and in the splenic sinusoids adjacent to the infarction. Incidental findings were cerebral cysticercosis and a haemorrhagic bilharzial cystitis. No diabetic nephropathy could be demonstrated.

DISCUSSION

This rare and mostly fatal infection by an opportunistic fungus is seen in patients with severe diabetes, acidosis, leukaemia, renal disease, septicaemia, burns, malnutrition, lymphoma and after long-term treatment with steroids and antibiotics.

The host response to this generally non-pathogenic fungus is poorly understood.¹ Possible aetiological factors are a decrease in the mucor-inhibiting ability of normal serum; a depressed polymorph leucocyte migration secondary to a decrease in mast-cell degranulation, and abnormalities in leucocyte mobilisation or phagocytosis.

Pulmonary infection results from the inhalation of spores produced under aerobic conditions in the nose or

nasopharynx. Devitalised tissue and local acidosis produced by bacterial infection enhance the growth and invasiveness of the fungus.

Thrombosis with infarction involving stomach, spleen and liver was seen in this case. The predilection for invading blood vessels, lymphatics and nerves with thrombosis and infarction seems a unique feature of this organism. The majority of cases are diagnosed at necropsy when the typical non-septate hyphae are seen. Only in 50% of cases was infected material isolated. The difficulty in treating mucormycosis is due to the debilitated state of the patient or the failure of the drug to reach the fungus because of the tissue infarction, rather than resistance to amphotericin-B. Subcutaneous forms have been treated with trimethoprim sulphamethoxazole.

REFERENCES

1. Palmer, D. L., Weitzner and Simpson, J. C. F. (1970): *Diabetes*, **19**, 881.
2. Hal, L. M. (1971): *Arch. Ophthalmol.*, **86**, 39.
3. Reich, J. and Renzetti, A. (1970): *Amer. Rev. Resp. Dis.*, **102**, 959.
4. Satir, A. A., Mahgoub, M. D. A. S. and Mousa, A. R. (1971): *Brit. Med. J.*, **1**, 440.
5. Medoff, G and Kobayashi, G. (1972): *New Engl. J. Med.*, **286**, 86.