

# Breast Augmentation

## RESULTS IN A SERIES OF 150 CASES

B. M. DE SAXE

### SUMMARY

Complications encountered after breast augmentation are dealt with in some detail, with reference to their frequency, causes, prevention and treatment. A comparison between complications of a temporary, correctible nature and those classified as 'permanent', and between minor complications, not affecting the over-all result, and those causing major concern, is made. The criteria on which results are based are detailed, with ratings given to determine excellent, good or poor results.

*S. Afr. Med. J.*, 48, 737 (1974).

Breast augmentation operations have, in recent years, become increasingly popular. This can be attributed to the natural desire of a woman to have normal proportions, and to the fact that modern society places great store on this. It can also be attributed to the fact that today excellent artificial prostheses are available, and that an operative technique has been perfected which has not only stood the test of time, but has produced very good results.

Previous articles<sup>1-3</sup> detailed the technique and the indications for breast augmentation. This article deals specifically with the results of a series of 150 cases performed during the years 1969-1973. Only operations performed

for absent, small or unequal breasts are included, and cases of augmentation carried out following a classical or subcutaneous mastectomy are excluded.

In this series, a Dow-Corning, Dacron-backed, prefilled variety of prosthesis was used in each instance. No inflatable type of prosthesis was used. The particular size chosen was decided on after discussion with the patient, careful consideration of her dimensions, and by the trial use during operation of a varying size range of prostheses.

The results were judged by consideration of the various complications and by grading each result as either excellent, good, or poor, according to specific criteria.

Table I details the complications, and give their frequency. It shows that only a few of these complications prove to be serious or permanent, the great majority being of a temporary nature and easily dealt with. Many of those that do persist cause only minor inconvenience to the patient, and detract only slightly from the general satisfaction with which the result is accepted.

It is of interest that complications recorded in the second 75 cases done are fewer in number and of lesser severity than those in the first 75 cases. This is attributed partly to the improvement in design and quality of the prostheses now available, and partly to the improvement in technique.

Eleven cases are labelled as having permanent complications. Of these, 5 were of major concern to the patient, and consisted of undue firmness of the breast in 4 cases, and the palpability of the prosthesis in 1 case. Of the 6 cases causing minor concern, 5 were due to either a palpable edge of the prosthesis or wrinkling on the

Johannesburg

B. M. DE SAXE, F.R.C.S.

Date received: 13 November 1973.

TABLE I. COMPLICATIONS

	No. of cases			No. corrected, i.e. temporary only			No. permanent to date but possibly correctable		
	1st 75	2nd 75	Total	1st 75	2nd 75	Total	1st 75	2nd 75	Total
Accumulation of fluid	2	1	3	2	1	3	0	0	0
Haemorrhage with haematoma formation	1	1	2	1	1	2	0	0	0
Infection	1	0	1	1	0	1	0	0	0
Firmness	3	2	5	1	0	1	2	2	4
Exposure of implant	2	0	2	2	0	2	0	0	0
Palpability of underlying prosthesis	6	2	8	2	0	2	4	2	6
Pain, discomfort or sensory change	2	1	3	1	1	2	1	0	1
Total	17	7	24	10	3	13	7	4	11
Percentage	23%	9%	16%	13%	4%	9%	9%	5%	7%

surface of the prosthesis, and 1 to some persistent discomfort. Of this total of 11 complications only 4 occurred in the second 75 cases, compared with 7 in the first 75, and of these 4, 2 were due to firmness.

The word 'permanent' to describe certain of these complications is not quite accurate, because many could be corrected by further surgery.

## COMPLICATIONS

### Accumulation of Fluid

Drainage was not employed in any of the cases in this series. Accumulation of serous fluid occasionally occurs, but is not serious and with the newer model implants it occurs far less frequently. It should be looked for postoperatively, and dealt with by aspiration carried out under strictly sterile conditions by inserting a needle below the prosthesis, but not through the operative wound. Repeat aspirations may be necessary.

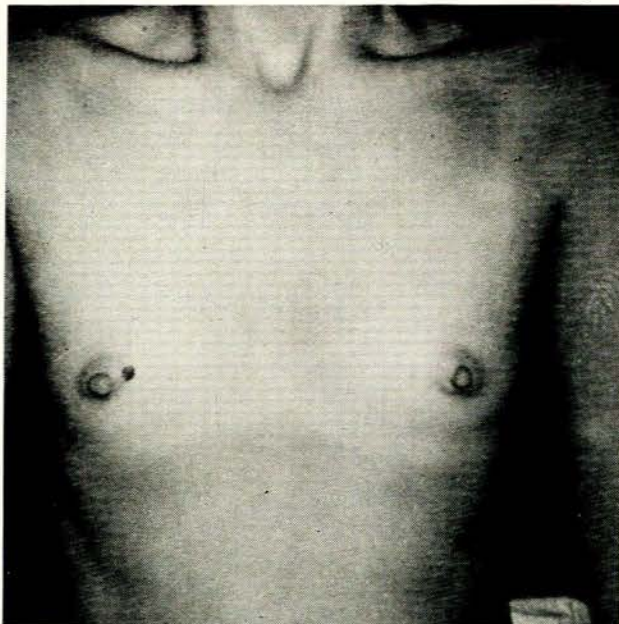


Fig. 1. A patient with virtually absent breasts.

### Haemorrhage with Haematoma Formation

This occurred only twice and necessitated an immediate return to theatre, where the wound was reopened, the prosthesis removed, the haematoma evacuated, the bleeding points sealed, the cavity irrigated with warm saline, antibiotic solution instilled, the prosthesis replaced and the wound reclosed in layers, without the use of drainage. No subsequent trouble occurred and both cases had an excellent result. One of the patients had a tendency to bleed.

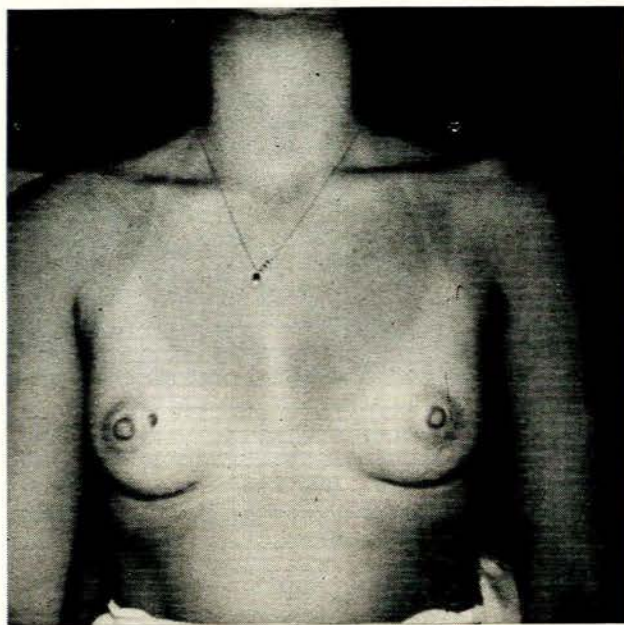


Fig. 2. The same patient as in Fig. 1 after augmentation.

At the initial operation haemostasis must be meticulous. There is minimal bleeding if dissection takes place in the correct plane, but if it strays too deeply, the pectoral muscle fibres are entered and this may cause troublesome bleeding. To ensure efficient haemostasis, good retraction and efficient lighting are important. The use of a specially designed mammary retractor with a cold-light illuminator attachment is recommended. Alternatively, a separate, flexible cold-light terminal, covered with a sterile sheath, enabling it to be inserted into the wound cavity, may be used.

To further help prevent possible bleeding in the early postoperative period, it is very important to restrict shoulder movement, which will reduce mobility of the pectoral muscles. Similarly, the patient should always be helped up in bed, and discouraged from using her elbows to lift herself. It is important, too, to ensure that an unwitting nurse does not pull on the patient's arm, when transfer from operating table to trolley to bed takes place.

### Infection

This complication occurred in only one case, and settled with conservative treatment.

Precautions are taken by instructing the patient to bath in Phisohex or other suitable preparation for a few days before surgery, and by ensuring strict sterility during the operation. All unnecessary handling of the sterile prosthesis before its insertion must be avoided, and care taken that no haematoma forms.

I used both local instillation and systemic antibiotics in all cases. However, many surgeons do not use them and report equally good results.

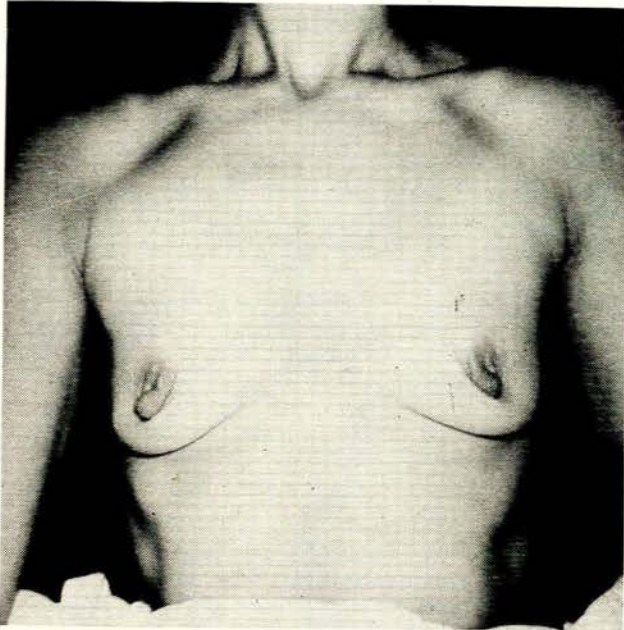


Fig. 3. Patient with considerable loss of breast substance and ptosis, following multiple pregnancies.

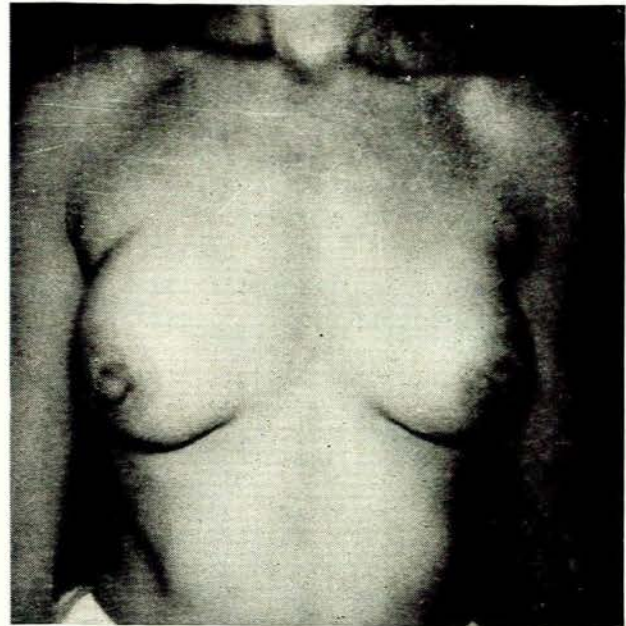


Fig. 4. The same patient as in Fig. 3 after silicone implantation.

### Firmness

Five cases of undue firmness of the breasts occurred in my series. Of these 1 was corrected by a second operation, 1 remained firm after a second operation, and 3 chose not to have further surgery. This complication was the most frequent of those complications listed as 'permanent' and the cause of major concern to the patients, although there were only 4 cases in all. Further surgery would probably have reduced this number.

Minor degrees of firmness sometimes occur because of the insertion of too large a prosthesis into too small a pocket, but in experienced hands this should not happen. Other causative factors may be excessive trauma at operation, excessive movement in the initial postoperative period, and the failure to recognise and treat accumulation of fluid or blood.

In all cases, the prosthesis causes a fibrous tissue capsule to form around it. As in other surgical operations, the degree of scar formation, hypergranulomatous reaction or keloid formation, varies considerably from patient to patient, and major degrees of firmness are due to excessive fibrous tissue reaction.

It has been suggested<sup>4</sup> that a steroid solution be placed into the cavity as a routine at the time of operation, in an attempt to reduce possible excessive reaction. While I have not done this, I certainly recommend it in patients whose history suggests a tendency to a hyper-scar reaction, or in those operated on a second time for correction of this complication.

Re-operation and revision is recommended<sup>5</sup> for all cases of excessive firmness. After re-opening the old wound the capsule is exposed, its base incised circumferentially and the edges spread open. This immediately

creates a larger pocket. Complete excision of the capsule is not recommended, as this leaves a large raw area, likely to heal with an even thicker capsule. At the time of operation, the size of the prosthesis is reviewed, and if it is considered too large, replaced.

### Exposure of the Implant

This occurred in 2 cases, both very early in the series, and both occurred through the inframammary wound. A second operation was performed, and in 1 case the implant replaced by a smaller one, with the opposite side redone to match.

This complication is attributable entirely to inexperience, when too large a prosthesis is used or too small a 'pocket' fashioned. It is more likely to occur after subcutaneous mastectomy, where the skin overlying the inserted implant is often thin, attenuated, and especially weak at the site of pre-existing operative scars.

### Palpability of the Underlying Prosthesis

Occasionally an otherwise excellent result is somewhat marred by palpability of the underlying implant, the border being felt as a firm ridge, or a 'bubble' felt on its surface. With the improved, thin-walled and seamless prosthesis, and elimination of the old, firm circumferential edge around the base, this complication occurs far less frequently. Other factors sometimes responsible are the initial insertion of too large a prosthesis, or buckling of the edge of the prosthesis following the formation of an excessively thick fibrous tissue capsule.

In my series 6 instances of this complication occurred in the earlier cases, compared with only 2 later in the series.

Should this complication cause distress, the patient can undergo a second operation, at which the pocket is enlarged by incision of the base of the capsule, or a slightly smaller prosthesis is inserted, or the old-type prosthesis is replaced by a modern one.

### Symptoms of Pain, Discomfort and Sensory Change of the Nipple

Initial postoperative pain usually results from excessive active or passive mobility, and severe or persistent pain from excessive trauma to the underlying pectoral muscle at the time of operation. However, with adequate precautions and judicious warning, this complication does not readily occur.

Several patients complained of sensory changes in the nipple and areola, which usually take the form of hypersensitivity rather than loss of sensation. These all proved to be temporary, never persisting for longer than 3 months. Worried patients should thus be reassured.

## RESULTS

After a minimum of 6 months postoperatively the patients' breasts were assessed for (i) degree of softness; (ii) quality of outline; (iii) palpability or otherwise of the underlying prosthesis; and (iv) presence of symptoms such as pain, discomfort or sensory change in the nipple or areola area. The rating was based on the criteria:

**Excellent**—natural breast softness; good breast contour; underlying prosthesis not palpable; symptom-free.

**Good** (any one of the following present)—breasts not perfectly soft or natural to the touch; breast contour not perfect; prosthesis palpable to a minimal degree; slight symptoms of discomfort, pain or sensory change in the nipple/areola area.

**Poor** (any one of the following present)—firmness of the breast; poor breast contour; prosthesis frankly palpable; symptoms troublesome.

The results according to this rating are shown in Table II.

The results of breast augmentation operations are generally very satisfactory. In experienced hands excellent results can be expected in 84% of cases, good results in 13%, and poor results in less than 3%.

TABLE II. RESULTS IN 150 CASES

	No. of cases		
	1st 75	2nd 75	Total 150
Excellent	55	63	118
Good	17	10	27
Poor	3	2	5

The new, light, seamless prosthesis has contributed a great deal to these good results, and complications such as the accumulation of fluid, and especially palpability of the underlying prosthesis, now seldom occur. However, the presence of other complications such as haematoma formation, firmness of the breast, or exposure of the implant, still depends largely on meticulous attention to detail, as well as to experience on the part of the surgeon.

On analysis of the results, it is seen that firmness of the breast is the most important complication and the one most likely to prove permanent. This is largely owing to an inherent tendency on the part of some patients to develop an excessive thickening of the fibrous capsule which forms around the implant, comparable to a similar tendency of certain patients to develop hypergranulomatous or keloid-type scars. In such patients or in those re-operated for firmness due to excessive fibrous tissue reaction in the capsule, local steroids should be used at the time of operation.

While the operative technique for breast augmentation is not considered a major procedure, or in any way difficult to perform, judgement is all-important, and comes only with experience.

The results of my series, appraised after a minimum postoperative interval of 6 months, are sufficiently good to warrant recommendation of the operation when requested.

It is of interest that the follow-up of cases done in the years prior to this series, dating back as much as 9 years, in all of whom silicone implants were used, show good long-term results.

## REFERENCES

1. De Saxe, B. M. (1964): *S. Afr. Med. J.*, **38**, 953.
2. *Idem* (1967): *Ibid.*, **41**, 842.
3. *Idem* (1970): *Ibid.*, **44**, 939.
4. Williams, J. E. (1972): *Plast. Reconstr. Surg.*, **49**, 253.
5. Freeman, B. S. (1972): *Ibid.*, **49**, 107.