

Central Core Disease Associated with Elevated Creatine Phosphokinase Levels

TWO MEMBERS OF A FAMILY KNOWN TO BE SUSCEPTIBLE TO MALIGNANT HYPERPYREXIA

H. ISAACS, M. B. BARLOW

SUMMARY

A further example of central core disease is described in a patient with various musculoskeletal abnormalities, who survived two episodes of malignant hyperpyrexia. Similar pathology, though less severe, was found in his asymptomatic mother.

S. Afr. Med. J., 48, 640 (1974).

Histochemical and electron microscopical examination of voluntary muscle of a patient who had previously recovered from two episodes of malignant hyperpyrexia, showed evidence of central core disease. The abnormality was also present in the muscle of his mother, although few fibres were involved in her case. The details of this family have been described previously.^{1,2}

CASE REPORT

The patient was born with several musculoskeletal abnormalities which included underdevelopment of the patellae, pes cavus with left-sided equinovarus deformity, high-arched palate, ptosis and lumbodorsal scoliosis. The latter abnormality may well have been secondary to the abnormality in the right lower extremity. The patient has a brother who has a mild degree of ptosis, high-arched palate, genu valgum and pes cavus. The mother, apart from a slight kyphoscoliosis which could be considered within normal limits, showed no significant evidence of musculoskeletal abnormality. The patient developed his first bout of malignant hyperpyrexia while undergoing surgery for the correction of the dislocated patellae; it was not recognised as such at the time, and he was subjected to a further operative procedure 2 weeks later and with a severe recurrence of the malignant hyperpyrexial reaction. The patient has recently had a third operative procedure, but on this occasion Althesin was employed and the anaesthesia went off uneventfully.

Department of Physiology, University of the Witwatersrand, Johannesburg

H. ISAACS, DIP. MED., M.D., F.R.C.P.
M. B. BARLOW, F.F.A.

Date received: 14 September 1973.

INVESTIGATIONS

A biopsy specimen was taken from the left deltoid, this being a muscle which appeared to be clinically normal. The muscle was removed under local anaesthesia and separate specimens of muscle were removed for histochemistry, motor nerve terminal and end-plate study, and for electron microscopy. The specimen for histochemistry was frozen in Isopentane after placing on cork discs and was held in position by gum tragacanth. The sections were processed for nicotinamide-adenosine-diaphorase-tetrazolium reductase, myofibrillar ATPase, phosphorylase, mitochondrial ATPase and routine haematoxylin and eosin, trichrome and PAS stains. The second muscle specimen was processed according to a modification of the Ranvier technique for motor nerve terminals and end-plates, and the third for electron microscopy.

RESULTS

The sections stained with haematoxylin and eosin showed considerable variation in fibre size (60-100 μ m). There was evidence of increased centralisation of the fibre nuclei and occasional atrophic fibres were noted. The blood vessels appeared to be perfectly normal, there was no

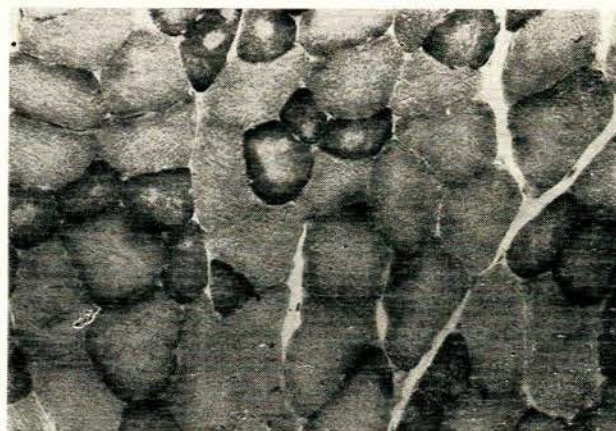


Fig. 1. NAD diaphorase preparation ($\times 100$) showing the central cores in the smaller type I fibres.

evidence of lymphocytic infiltration and the amount of fibrous tissue and fat within the muscle appeared to be normal. The histochemical processing showed that many of the type I fibres contained non-staining areas and these central cores were best seen in the NAD diaphorase preparations (Figs 1 and 2). In certain areas of the muscle examined there was evidence of grouping of individual fibre types.³ Electron microscopy showed areas

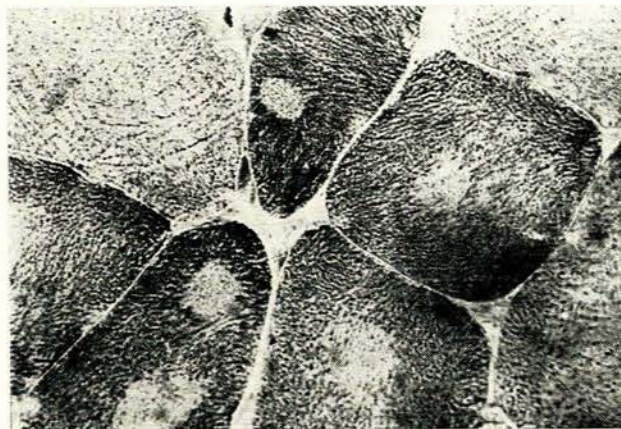

Fig. 2. NAD diaphorase preparation ($\times 400$) showing the central cores in the type I fibres.

of total myofibrillar depletion, where scanty mitochondria and excessive folding of the plasma membrane were seen (Fig. 3). Other areas showed evidence of fibre loss together with aggregations of large mitochondria, many of which were swollen and showed loss of cristae (Fig. 4). In other areas adjacent to the core region the myofibrils were closely packed, with marked zig-zagging and streaming of the Z-lines (Fig. 5). Glycogen granules were present in normal quantity.



Fig. 3. Electron photomicrograph ($\times 10\,000$) showing an area of total fibre depletion with scanty mitochondria and excessive folding of the plasma membrane.



Fig. 4. Electron photomicrograph ($\times 12\,000$) showing evidence of fibre loss and disintegration of mitochondria.

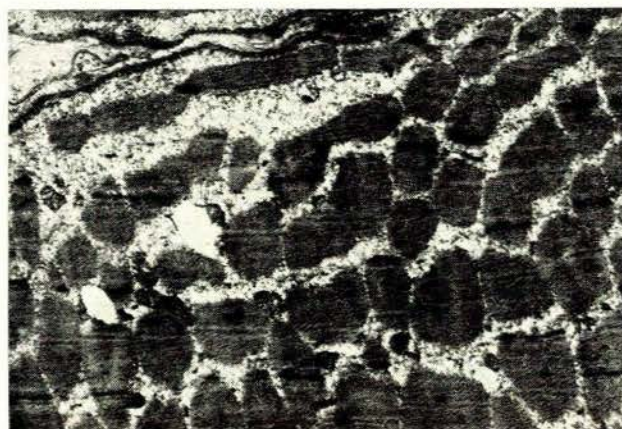


Fig. 5. Electron photomicrograph ($\times 6\,000$) showing early destruction of the Z-lines in a core region.

The motor nerve terminals showed increased terminal branching of the motor nerve terminals with a nerve terminal: muscle fibre ratio of 1:3 (normal 1:1).³

Tissue was removed from the deltoid muscle of the patient's mother and processed in a similar way. The findings on haematoxylin and eosin staining were similar to those of the patient, but on histochemical analysis only 5% of her type I cells showed evidence of central cores. The electron microscopic study revealed similar but less severe changes. The motor nerve terminal end-plate study again revealed excessive branching, with a ratio of 1:3, and histochemical evidence of grouping of individual fibre types.

DISCUSSION

The familial incidence of malignant hyperpyrexia has been known since Denborough and Lovell⁴ described a family in 1960. Though the muscle was known to be the major site of heat production during the malignant hyperpyrexial reaction, the suggestion that the underlying basis

for malignant hyperpyrexia was an inherited form of myopathy was made in 1970.³ This suggestion was prompted by the finding of abnormally high levels of creatine phosphokinase in about half the members of a family in which 3 deaths from malignant hyperpyrexia had occurred.^{6,7}

The abnormality was traced over 5 generations and in that family appeared to be the only phenotypical expression of the disease. Since then creatine phosphokinase estimations have become a useful screening technique, and although normal levels are encountered occasionally, these carriers may be identified by the presence of elevated creatine phosphokinase levels in their offspring, by biopsy or by halothane exposure of muscle.⁸ Histological and histochemical confirmation of a myopathy in these asymptomatic carriers was shown in 2 families.² The myopathy has shown different characteristics in different families. In some families the muscle has been reported as normal⁹ while Ellis *et al.*¹⁰ found myopathic changes in 5 biopsy specimens. Denborough *et al.*¹¹ reported the occurrence of central core disease in a 71-year-old aunt of the propositus in a family in which there had been 3 deaths from malignant hyperpyrexia.

The physical abnormalities of the patient described in this article resemble those of cases of central core disease described by Engel *et al.*¹² and the case of congenital myopathy associated with malignant hyperpyrexia described by King and Denborough.¹³ Pes cavus has been reported in association with central core disease by many authors including Dubowitz,¹⁴ Gonatas *et al.*,¹⁵ Mittelbach and Pongratz¹⁶ and Bethlem *et al.*¹⁷

With the passage of time evidence is accumulating to support the hypothesis that a specific inherited disorder of muscle predisposes towards malignant hyperpyrexia and that this inherited disorder may be associated with different

forms of myopathy. Evidence also suggests that the underlying defect in malignant hyperpyrexia may be primarily neuropathic or both neuropathic and myopathic. Evidence for neuropathic involvement has been presented by La Cour *et al.*¹⁸ by the finding of grouping of individual fibre types, by grouped atrophy of cells and by changes in the motor nerve terminals. The presence of central core disease affecting the group I fibres may be regarded as an example of diseased type I (red or slow) motor units, again suggesting a primary neuropathic aetiology.

This work was supported by grants from the South African Medical Research Council and the Witwatersrand University Senate Research Fund.

REFERENCES

1. Isaacs, H. and Barlow, M. B. (1973): *Brit. J. Anaesth.*, **45**, 906.
2. Isaacs, H., Frere, G. and Mitchell, J. (1973): *Ibid.*, **45**, 860.
3. Coërs, (1955): *Acta clin. belg.*, **10**, 244.
4. Denborough, M. A. and Lovell, R. R. H. (1960): *Lancet*, **2**, 45.
5. Isaacs, H. and Barlow, M. B. (1970): *Brit. Med. J.*, **1**, 275.
6. Barlow, M. B. and Isaacs, H. (1970): *Brit. J. Anaesth.*, **42**, 1072.
7. Isaacs, H. and Barlow, M. B. (1970): *Ibid.*, **42**, 1077.
8. Ellis, F. R., Harriman, D. G. F., Keaney, N. P., Kyei-Mensah, K. and Tyrrell, J. H. (1971): *Ibid.*, **43**, 721.
9. Bradley, W. G., Ward, M., Murchison, D., Hall, L. and Woolf, N. (1973): *Proc. Roy. Soc. Med.*, **66**, 67.
10. Ellis, F. R., Keaney, N. P., Harriman, D. G. F., Sumner, D. W., Kyei-Mensah, K., Tyrrell, J. H., Hargreaves, J. B., Parikin, R. K. and Mulrooney, P. L. (1972): *Brit. Med. J.*, **3**, 559.
11. Denborough, M. A., Dennet, X. and McD. Anderson, R. (1973): *Ibid.*, **1**, 272.
12. Engel, A. G., Gomez, M. R. and Groover, R. V. (1971): *Proc. Mayo Clin.*, **46**, 666.
13. King, J. O. and Denborough, M. A. (1972): *Brit. Med. J.*, **4**, 526.
14. Dubowitz, V. (1969): *Neuropædiatrie*, **1**, 137.
15. Gonatas, N. K., Perez, M. C., Shy, G. M. and Evangelista, I. (1965): *Amer. J. Path.*, **47**, 503.
16. Mittelbach, F. and Pongratz, D. (1968): *Dtsch. Z. Nervenheilk.*, **194**, 232.
17. Bethlem, J., Van Gool, J., Hülsman, W. C. and Meuler, A. E. P. H. (1966): *Brain*, **89**, 569.
18. La Cour, D., Juul-Jensen, P. and Reske-Nielsen, E. in Gordon, R. A., Britt, B. A. and Kalow, V. (1971): *First International Symposium on Malignant Hyperthermia, 1971, Toronto*. Springfield, Ill.: Charles C. Thomas.