

# Percutaneous Transhepatic Cholangiography

A. R. GOLDIN, E. M. BASS

## SUMMARY

Our experience with percutaneous transhepatic cholangiography in 46 cases is presented and compared with other series. The technique is safe, simple and accurate and can play a major role in the early diagnosis of obstructive jaundice.

*S. Afr. Med. J.*, 48, 637 (1974).

Percutaneous transhepatic cholangiography can play a major role in expediting the early diagnosis of surgically correctable jaundice. The need for this is emphasised by the fact that in a group of 46 patients the delay between the onset of jaundice and diagnosis ranged from 20 to 90 days. Transhepatic cholangiography carried out earlier rather than later could have substantially reduced the cost both in terms of valuable time and of repeated expensive biochemical examinations.

The procedure is simple to perform and experience with this technique at Groote Schuur Hospital in the past 3 years has been extremely encouraging. In this article the indications, technique, results and complications are presented.

The indications for performing percutaneous transhepatic cholangiography were: (i) to differentiate obstructive from hepatocellular jaundice where clinical and biochemical examination was inconclusive; (ii) to define the site and probable nature of the lesion in known obstructive jaundice; (iii) to evaluate jaundice occurring after previous biliary surgery.

## METHOD

Prothrombin index (75% minimum) and platelet count (60 000 minimum) were evaluated before puncture. The procedure was followed by laparotomy in every patient and carried out either under routine premedication or after 19 mg diazepam (Valium; Roche) intravenously. All examinations were carried out by using routine fluoroscopy facilities equipped with a tilting table, undercouch tube and television monitor. The lateral approach described by Varela Fuentes *et al.*<sup>1</sup> and Wiechel<sup>2</sup> was used in all cases.

The site of the puncture (usually the tenth right lateral intercostal space) and diaphragmatic excursion were checked by screening a marker. Under local anaesthesia a 20-mm, 20-gauge B.D. Longdwel Teflon cannula was

introduced during quiet respiration and advanced superiorly and medially towards the twelfth dorsal vertebral body along the long axis of the liver. The needle was advanced inch-wise for a distance of approximately 12 cm by holding it near the skin and taking care to avoid bending.

Penetration of a biliary duct was assessed, as advocated by Arner *et al.*,<sup>3</sup> by connecting the needle to a standard drip extension tube and injecting a small volume of sodium diatrizoate 45% (Hypaque; Winthrop) while slowly withdrawing. If no duct was entered the injection was stopped approximately 2 cm from the liver edge to prevent reflux of contrast into the peritoneal cavity. The needle was re-introduced through the same skin puncture and directed in slightly more posteriorly.

On entering the duct system, injection of contrast was continued until the biliary tree was adequately filled. This required up to 80 ml sodium diatrizoate in some cases and was assisted by taping the cannula in position and turning the patient into a steep left oblique position while monitoring the injection. The true site of obstruction was verified by spot films taken in optimum positions which frequently included erect views.

Where the punctures were successful the ducts were invariably entered during the first two attempts out of a maximum of four.

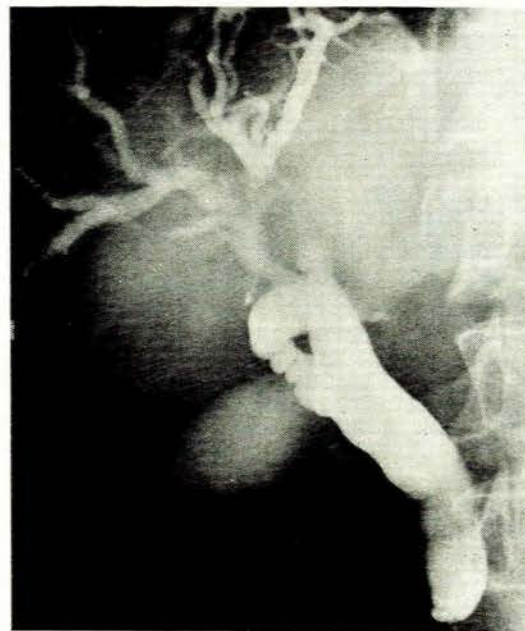


Fig. 1. Carcinoma of the head of the pancreas with occlusion of the distal common and cystic bile ducts and gross dilatation of the intrahepatic biliary tree.

Department of Radiodiagnosis, Groote Schuur Hospital, Cape Town

A. R. GOLDIN, M.B. B.CH. F.C.P. (S.A.), F.F.R.  
E. M. BASS, M.B. CH.B. D.M.R.D.

Date received: 11 October 1973.

## RESULTS

The diagnoses proved at laparotomy in 46 cases are shown in Table I and several examples are demonstrated in Figs 1-5.

TABLE I. DIAGNOSES BY TRANSHEPATIC CHOLANGIOGRAM IN 46 CASES (34 SUCCESSFUL PROCEDURES)

	No.
Carcinoma head of pancreas ... ..	17
Common duct calculi ... ..	6
Previous biliary surgery ... ..	3
Cholangiocarcinoma ... ..	6
Gall bladder carcinoma ... ..	2
Unsuccessful ... ..	12

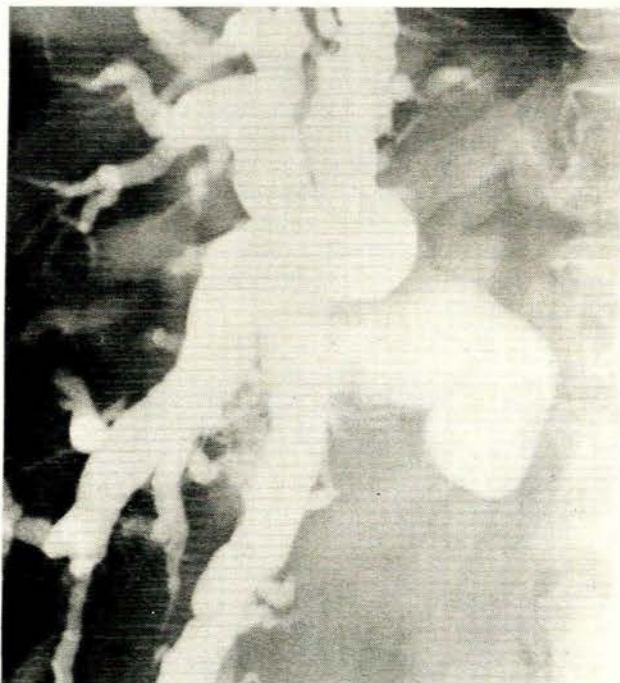

Fig. 2. Carcinoma common hepatic bile duct (low lesion) with gross intra- and extrahepatic biliary dilatation. The lesion is proximal to the cystic duct origin but the site of obstruction has a similar appearance to that in Fig. 1.

Of the 39 cases with surgically correctable jaundice, the dilated biliary tree was successfully punctured in 34 (85%). Of the remaining 5 cases, 3 were true failed punctures while the remaining 2 had small-calibre ducts due to cholangitis with associated calculi. These 2 cases were therefore regarded as false negatives.

The cause of jaundice in the 7 remaining true negative cases with non-surgical jaundice is shown in Table II.

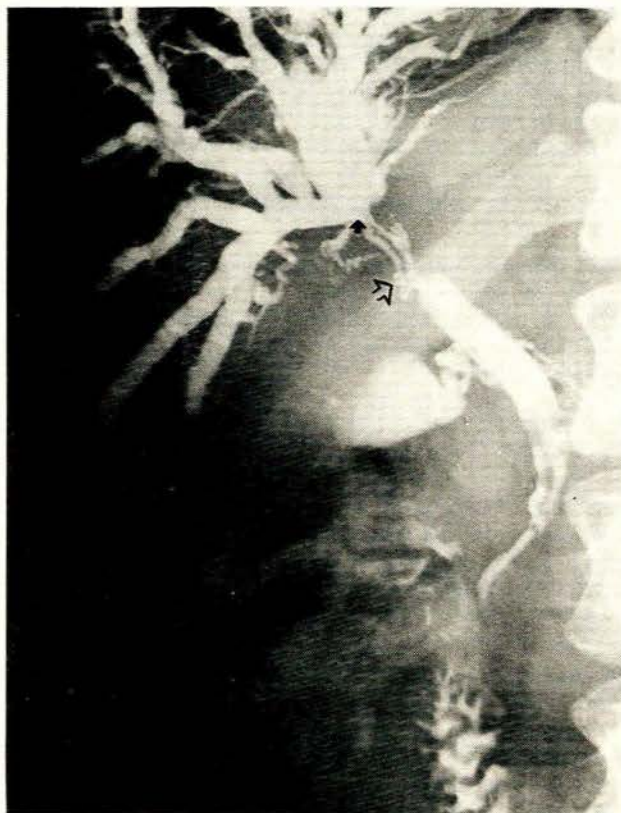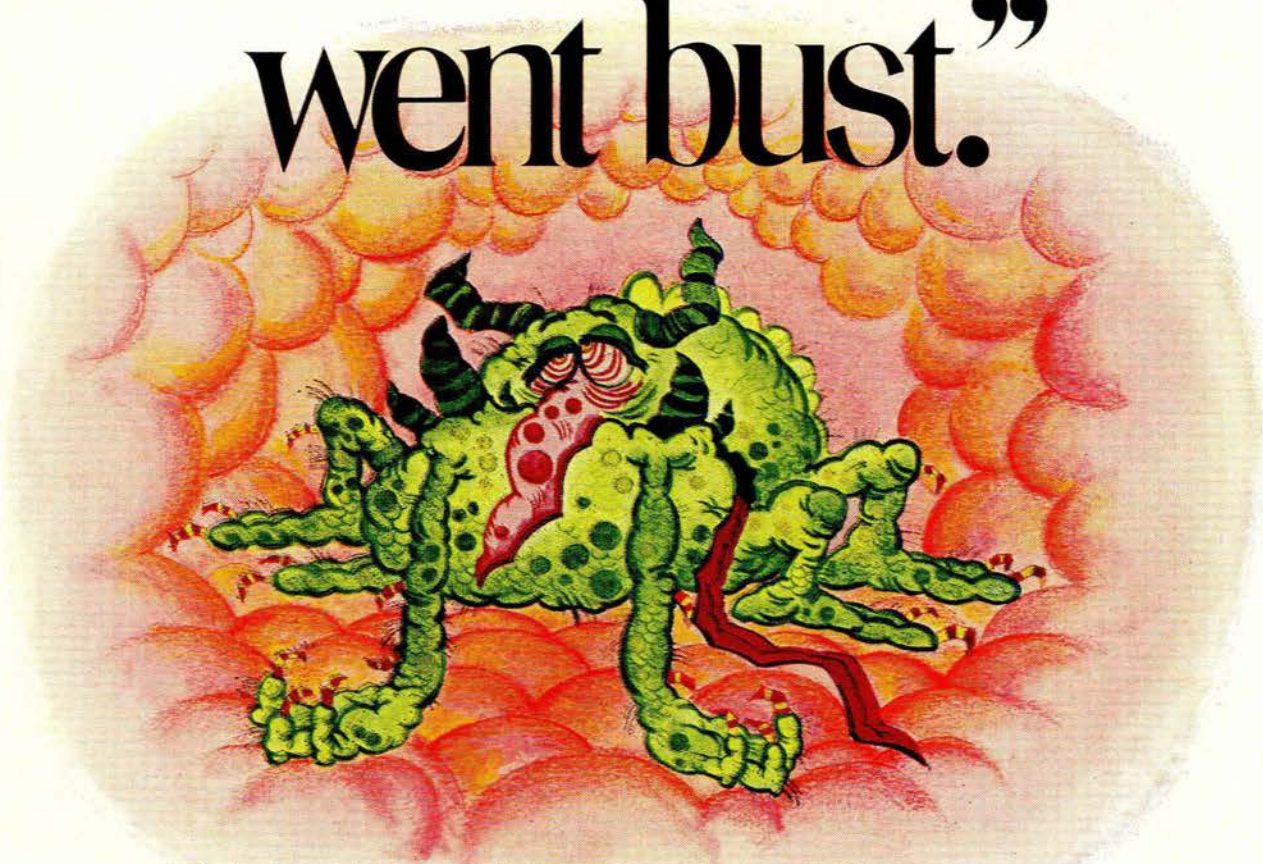


Fig. 3. Cholangiocarcinoma main hepatic ducts (black arrow) with moderate intrahepatic biliary dilatation with incomplete obstruction and filling of the distal common bile duct and gall bladder. The lymphatics draining to glands in the porta hepatis have filled from interstitial injection (white arrow).

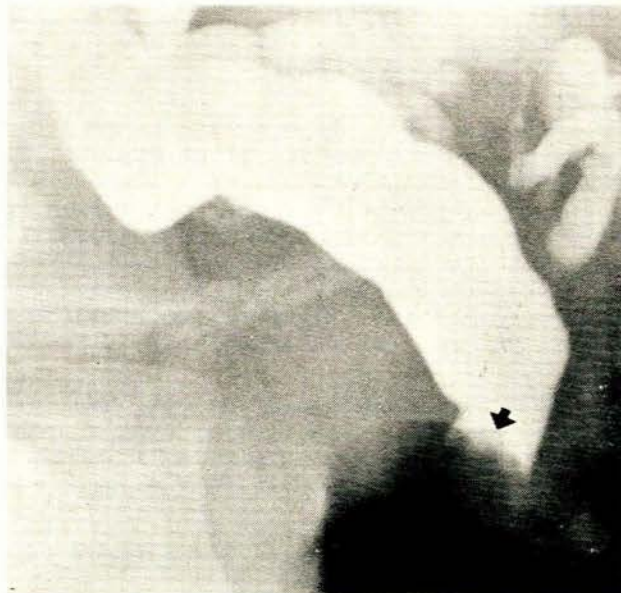

Fig. 4. Common bile duct calculus with a convexity at the site of obstruction (arrow).

# "The day my chest business went bust."



"The bronchitis business had been good to Haemophilus Inc. But soon after I'd infested in a young boy's chest, profits tumbled. Some bright young doctor prescribed 'Eskacef' - 250mg orally every 6 hours - and that was the end of me. That doctor made a real killing..."

S K & F's broad-spectrum 'Eskacef'. The right-first-time cephalosporin anti-

biotic, for potentially dangerous infections. In children and adults.

Respiratory, gastro-intestinal, genito-urinary and skin/soft tissue infections - they all need 'Eskacef'.

The sooner the better antibiotic. With the added plusses of being only 6% protein-bound and no reports of nephro-toxicity.

**Broad Spectrum**  
**eskacef\***

**The sooner the better antibiotic.**  
**For respiratory and other infections.**

Smith Kline & French Laboratories. Division of Smith Kline & French (Pty) Ltd., Isando Road, Isando, Transvaal.

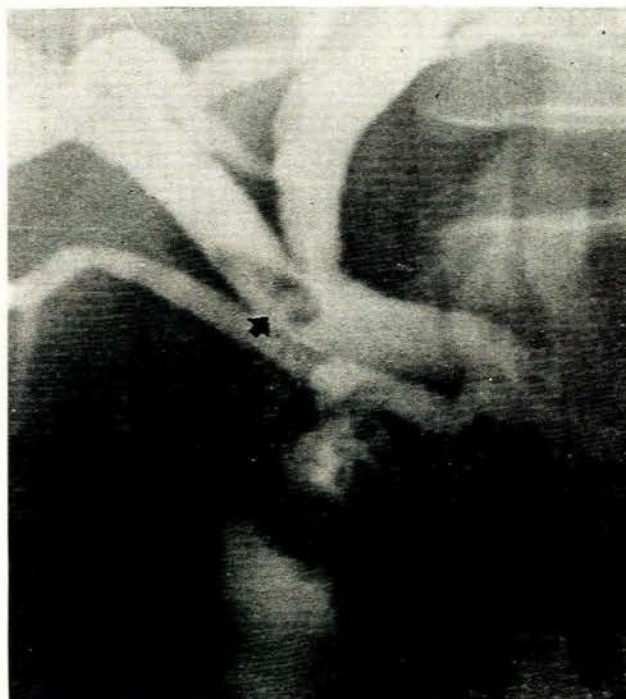


Fig. 5. Cholecystenterostomy with a stone in the right hepatic duct (black arrow) causing recurrent cholangitis. There is drainage into the gall bladder (white arrow).

TABLE II. DIAGNOSES OF 12 NEGATIVE TRANSHEPATIC CHOLANGIOGRAMS IN 46 CASES

False negatives (ducts dilated)	
Carcinoma head of pancreas ... ..	2
Carcinoma gall bladder ... ..	1
True negatives (ducts not dilated)	
Calculi with cholangitis ... ..	2*
Secondary hepatic deposits ... ..	2
Hepatocellular jaundice ... ..	5

\* With the exception of these 2 cases, laparotomy was unnecessary.

## COMPLICATIONS

The complications encountered were divided into major and minor groups and are shown in Table III. Significant bleeding or leakage of bile into the peritoneal cavity was infrequent and in most cases the site of the liver puncture could not even be identified. In one patient with calculi septicaemia occurred owing to the omission of adequate broad-spectrum antibiotic cover.

Minor complications were all of a technical nature and had no untoward sequelae. Transdiaphragmatic puncture occurred with excessive diaphragmatic excursion and inadequate marking of the puncture site. Bending of the needle occurred when the thrust applied at the hub and not near the skin directed it superiorly. Trans-transhepatic puncture through a thin vertical liver occurred with hori-

TABLE III. COMPLICATIONS

Major	No.
Haemorrhage ... ..	2
Septicaemia ... ..	1
Biliary leak ... ..	0
Deaths ... ..	0
Minor	
Transdiaphragmatic puncture ... ..	2
Trans-transhepatic puncture ... ..	2
Perivascular puncture ... ..	1
Gall bladder puncture ... ..	0

zontal introduction of the needle. Perivascular injection, initially mistaken for duct entry on screening, was plainly evident on film. Gall bladder puncture did not occur in this series as the lateral approach was used in all cases rather than the anterior method described by Seldinger.<sup>4</sup>

## DISCUSSION

In a recent review of 1 629 cases from the world literature by Hines *et al.*,<sup>5</sup> 1 204 punctures (74%) were successful and the incidence of major complications was 5%. The results of our series compare favourably with a successful puncture rate in the presence of dilated ducts of 85% and a complication rate of 6%.

Partial obstruction due to stones or high lesions, such as cholangiocarcinoma of the main hepatic duct junction, usually resulted in less dilatation of the intrahepatic radicles than low obstructions of the common bile duct due to carcinoma of the head of the pancreas.

In most of the positive punctures an accurate assessment of the pathological features of the lesion could be made. Exceptions were carcinoma of the gall bladder and carcinoma of the distal common hepatic duct, where the features were characteristic of extrinsic obstruction and frequently indistinguishable from a large carcinoma of the head of the pancreas (Figs 1 and 2). Cholangiocarcinoma of the main hepatic duct junction (Fig. 3) was diagnosed with confidence and provided invaluable assistance to the surgeon, as this lesion was frequently too high to palpate at surgery and could easily have been missed. In cases of previous biliary surgery with fibrosis, accurate indication of the site of the stricture and stone formation (Fig. 5) was useful to the surgeon.

The results of this study indicate that in cases where hepatocellular jaundice is the more likely diagnosis a negative puncture has an 80-90% probability of being correct. In such cases, provided the patient is closely monitored, laparotomy may be deferred.

## REFERENCES

- Varela Fuentes, B., Bertoni, C. and Polero, J. (1957): *Pre. méd. argent.*, **44**, 2873.
- Wiechel, K. L. (1964): *Acta chir. scand.*, suppl. 330.
- Arner, O., Hagberg, S. and Seldinger, S. I. (1962): *Surgery*, **52**, 561.
- Seldinger, S. I. (1966): *Acta radiol. (Stockh.)*, suppl. 253.
- Hines, C., Ferrante, W. A., Davis, W. D. and Tutton, R. A. (1972): *Amer. J. Dig. Dis.*, **17**, 868.