

An Anatomico-physiological Principle Governing the Direction of the Gastro-intestinal Mucosal Folds During Life

A. D. KEET

SUMMARY

The mucosa, being the innermost layer of the gastro-intestinal tract, is intimately concerned with digestion and absorption, and, presumably, also with the transport of intestinal contents. In anatomical, physiological and motility studies, possible movements of the mucosa and its folds are neither considered nor investigated.

Dogmatic statements about the direction of the folds are often made. Radiologists have long been aware of mucosal movements, but after the fundamental work of Forssell, no further views have been put forward.

Radiological procedures have been used to investigate the normal, macroscopic, physiological movements of mucosal folds. A general rule follows. Normally, when the intestine is filled, but inactive, the folds are circular; when the walls contract, the folds change in direction, to become longitudinal. This phenomenon is confirmed by *in vivo* baboon studies and elucidated by wire spirals. It is seen to be an inherent characteristic of 'peristaltic' and 'segmental' contractions. In this manner longitudinal mucosal furrows are formed simultaneously with the contraction wave of the walls, thus facilitating transit. Were this not so, peristalsis would be an ineffective mechanism, with contraction waves acting against the resistance of circular folds.

S. Afr. Med. J., 48, 441 (1974).

Many studies in depth of different aspects of gastro-intestinal motility and motor function have been made in recent years,¹⁻⁸ and comprehensive reviews are available.⁹⁻¹² While movements such as those of Type I, II and III waves, tone, peristalsis, rhythmic segmentation, and pendulum movements are described in detail, there is, surprisingly, no mention of possible mucous membrane movements. Because it is the innermost layer of the digestive tube, and thus in intimate contact with ingested food and the products of digestion, it is conceivable, surely, that the physical properties of the mucosa may have some effect on the transport of intestinal contents.

Questions which come to mind are: What is the position or direction of the mucosal folds in the various divisions of the gastro-intestinal tract? Do the folds, mechanically

speaking, hamper or aid propulsion? Are they fixed or do they change direction? Because these questions are not considered in present-day experimental studies, one turns to modern textbooks for information, which leads to the conclusion that the folds have a characteristic position for each division of the gastro-intestinal tract, and that they are fixed. Thus it is stated¹⁴ that while the mucosal folds vary in their pattern in different parts of the alimentary canal, in the small bowel they are circular. Other views on the anatomy,^{15,16} histology,¹⁷ applied anatomy,¹⁸ radiographic anatomy,¹⁹ and physiology²⁰ are: that the circular folds of the small bowel are permanent; that circular folds are peculiar to the small intestine;²¹ no mention is made of possible movements of these folds visible to the naked eye,²²⁻²⁴ and it has been stated that no regular or consistent activity of the main layer of the muscularis mucosae has been described.²⁵

For the sake of brevity it can be stated that there are similar views about other divisions of the gastro-intestinal tract.

PREVIOUS EXPERIMENTAL STUDIES

The mucous folds were, for many years, thought to be of little significance, and to arise from a passive process, the result of contractions of the muscularis propria. The fundamental work of Forssell²⁶⁻²⁸ has received little attention outside radiology, and it is an enigma of the medical literature that no reference is made to his findings in physiological and gastro-intestinal motility studies.

It is difficult to do justice to Forssell's findings in a short summary, but briefly they may be stated to be as follows: the size of the gastric and intestinal lumen can be modified by reflex movements of the mucosa, the result of contraction of the muscularis mucosae, quite independent of contraction of the tunica muscularis (muscularis propria). The mucous membrane of the whole digestive tract is able to assume different shapes, i.e. it has an inherent contractile mechanism, termed by Forssell as the mucous membrane 'autoplastik'. The coarser breakdown of foodstuffs is effected by contractions of the muscularis propria, but the finer dispersion is by changes in the relief pattern of the mucous membrane, which may enhance or counteract the effects of contraction of the muscular wall. The relief patterns may be classified into 2 main types according to function: resting (or empty) shape, and active shape. Forssell discerned several con-

Department of Radiology, Tygerberg Hospital, Tiervlei, CP
A. D. KEET, M.B., CH.B., M.D.

Date received: 24 July 1973.

tractile shapes: blocking or filtering devices, smooth or corrugated transporting tubes, digestion chambers, and reabsorption reservoirs. In this way, each part best meets the varying demands placed on it from one moment to the next: digestion, absorption, storage, and transport. One moment it may be occupied with one task, and the next, with another.

A certain contraction of the muscular tube (*muscularis propria*) is necessary for the formation of macroscopic folds, but the inherent action of the *muscularis mucosae* determines, to a great extent, the number, position, and form of the folds. Cole²⁹ held that the formation of mucosal folds is for the most part a passive matter, and related to the state of contraction of the *muscularis propria*. The mucosal folds of the stomach were regarded as persistently recurrent and constant for any one person. Progressive gastric peristalsis was thought to be a function of the *muscularis mucosae*, and independent of the *muscularis propria*.

Brooks *et al.*³⁰ confirmed Forssell's findings. Deucher,³¹ during an examination of the small bowel at operation, found that the folds were transverse in the wide, and longitudinal in the contracted, states.

Sloan,³² in a study of anatomical specimens of the small bowel concluded that there is a correlation between the mucosal pattern on the one hand, and the degree of distension or contraction of the walls, on the other. In life he noted longitudinal folds associated with peristaltic activity. This pattern could not be reproduced in anatomical specimens.

PREVIOUS ISOLATED RADIOLOGICAL OBSERVATIONS

In contrast to physiologists, anatomists, and gastro-enterologists, radiologists have long been aware of mucosal-fold movements. Radiologists have recorded changes in the direction of the folds in specific areas under certain conditions. Thus, Golden³³ noted that in some cases the folds in the pyloric 'antrum' run irregularly transverse to the long axis, but when antral systole takes place they change direction and come to lie parallel to the long axis. Golden³⁴ also noted that the folds in the second and third parts of the duodenum and in the jejunum change from their usual transverse to a longitudinal direction in, and just ahead of, the peristaltic waves. He laid more stress on mucosal movements which occur independently of contractions of the *tunica muscularis*.

Templeton,³⁵ referring to Forssell and Golden, noted that contraction of the circular *muscularis propria* in the antrum causes the complex folds to become parallel to the long axis of the lumen. Similarly, he noted different patterns in the duodenal bulb, but with a deep peristaltic wave, all folds became parallel at the centre of the contraction ring. Buckstein³⁶ observed that as a result of peristaltic activity in the small bowel, longitudinal folds may occur in the region of the constriction.

Shanks and Kerley³⁷ noted that the duodenum contains folds of a reticular pattern when it is relaxed, and a

longitudinal pattern when in peristaltic contraction. In the jejunum the normal mucosal pattern is a transverse hatching when it is distended; in segments under peristaltic contraction the folds are often seen to be longitudinal. Similar features are seen in the ileum. In the colon, longitudinal folds tend to take place when the *taeniae* are relaxed. Transverse folds occur when *haustra* are present.

During investigations of prolapse of gastric mucosa into the duodenal bulb, Keet³⁸ found that, when the prepyloric area of the stomach is relaxed normally, it contains transverse and oblique folds. During contraction the folds change direction and come to lie longitudinally.

Schinz *et al.*,³⁹ referring to Forssell, state that Kerckring folds in the small intestine may appear and then disappear. In the ileum, longitudinal folds are seen in the phase of evacuation. In the colon the contracted segments between *haustra* contain longitudinal folds, while in the *haustra* themselves there are delicate transverse crinklings.

Paul and Juhl,⁴⁰ describing the mucosal pattern of the colon, stated that parallel folds are seen momentarily and in short lengths, and that they are due to a mass peristaltic contraction. Harper,⁴¹ confining himself to the duodenum, noted that at the point of narrowing of a peristaltic wave, the complex mucosal folds become arranged longitudinally.

Except for Forssell, none of the above authors made any attempt to formulate general rules for the mucosal movements, the observations being of an isolated nature.

PRESENT RADIOLOGICAL OBSERVATIONS

Material and Methods

Observations of movements of the mucosal folds were made during routine barium studies of the gastro-intestinal tract in several hundred subjects during a period of 4-5 years. The descriptions given apply to all normal cases.

The term inactive is used in its motor and not in its secretory sense. The term peristaltic indicates an annular, constricting wave, progressing in a caudal direction over a shorter or longer distance. Segmental or concentric indicates a rather longer area of contraction, extending over several cm, which does not move caudally.

Prepyloric Area of Stomach

This area has been defined anatomically by Forssell²⁶ and Torgersen,⁴² the name *canalis egestorius* being suggested instead of antrum. Normally, when it is filled but inactive, the folds run transversely across its long axis (Fig. 1). When it contracts, the folds change direction, first becoming oblique, then progressively more longitudinal, until only longitudinal folds are seen when it is maximally contracted (Fig. 2). This feature could invariably be demonstrated in all normal stomachs. The change in direction of the folds in this situation has previously been noted by Forssell,²⁶ Golden,³³ Templeton³⁵ and Keet.³⁸

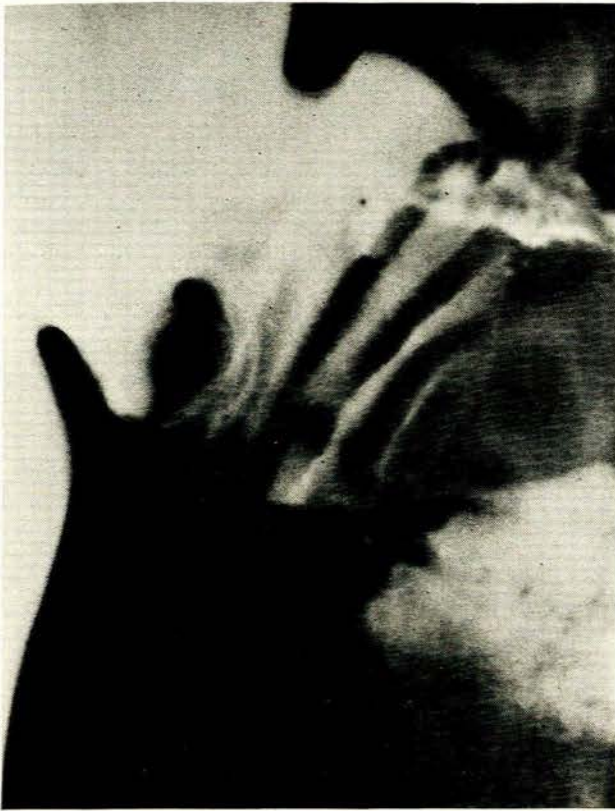

Fig. 1. Prepyloric area of stomach (canalis egestorius) filled but inactive. Mucosal folds are transverse.

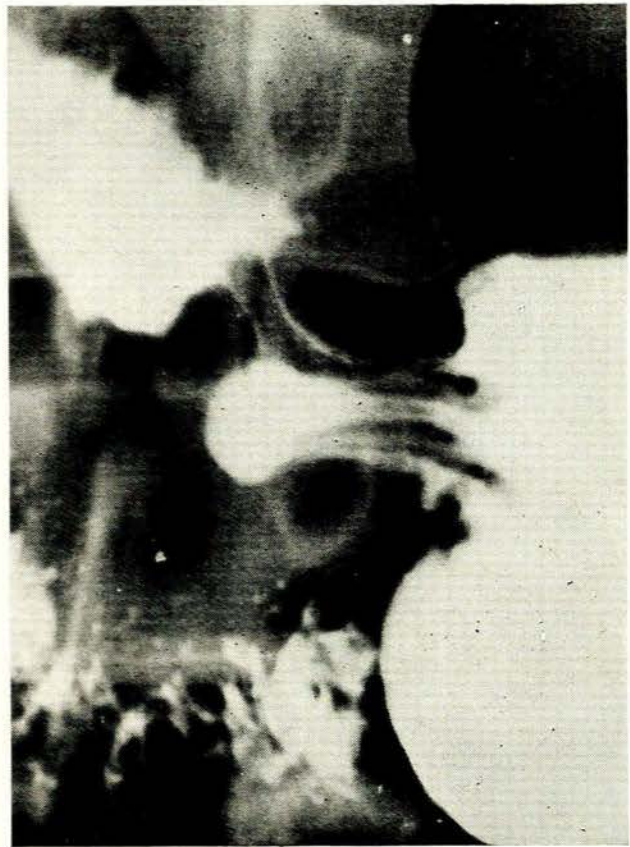

Fig. 2. Prepyloric area contracted. Folds have changed direction and are longitudinal.

Proximal Division of Horizontal Part of Stomach

In the filled but inactive (or aperistaltic) phase, transverse mucosal folds are seen. With the passage of peristaltic wave, the folds change direction, being pinched in by the constriction, thus becoming progressively more oblique (Fig. 3). As the peristaltic contraction increases, the change in direction proceeds, until only longitudinal folds are seen in the confines of the constricting wave.

Duodenal Bulb

In the filled, inactive state, transverse folds can usually be demonstrated. When the bulb contracts, the folds change direction to become longitudinal. This has previously been recorded by Templeton.³⁵

Duodenal Loop

In filled but aperistaltic parts, the mucosal folds lie transversely and obliquely. With the passage of a peristaltic wave, the folds change direction and lie longitudinally, so that in the confines of the peristaltic contraction only longitudinal folds are evident (Fig. 4). The change in

direction in this area has previously been described by Shanks and Kerley,³⁷ Harper⁴¹ and Golden.³⁴

Jejunum

The features are essentially those of the duodenal loop, transverse and oblique folds being present in inactive, filled segments, changing to a longitudinal direction during a contraction (Fig. 5). This phenomenon was regularly seen during peristaltic as well as segmental contractions. The change of direction has previously been described by Buckstein,³⁶ Shanks and Kerley,³⁷ Sloan³² and Golden.³⁴

Ileum

Transverse folds which are present in the filled, inactive state become longitudinal during a contraction (Fig. 6). This is seen in both peristaltic and segmental contractions. This has previously been noted by Shanks and Kerley³⁷ and Schinz *et al.*³⁹

In all the instances described above, the transverse folds are, in reality, circular folds seen sideways. The radiological image is an illusion created by the summation effect and



Fig. 3. Horizontal part of stomach. In filled but inactive area mucosal folds are transverse. Within peristaltic contraction folds have changed direction to become longitudinal.

2-dimensional viewing. At times, with moderate gaseous distension of the intestine, it is possible to demonstrate the circular nature of the folds in the aperistaltic phase (Fig. 7).

Another phenomenon is that the longitudinal folds in contracting areas often appear hazy or indistinct (Fig. 8). This is due to movement of the contraction wave.

Colon

In inactive, haustral sacculations the mucosal folds are circular, and in the contracted segments between haustra, only longitudinal folds are seen (Fig. 9). At the junction of the sacculae and contracted segment, the folds are oblique or spiral (Fig. 10). Where there is an effacement of haustrations, such as in a long area of contraction (peristaltic mass movement), the circular and oblique folds change direction and only longitudinal folds are seen.

Similar observations have previously been made by Shanks and Kerley²⁷ and Schinz *et al.*²⁸

Rectum

With double-contrast techniques, circular and spiral folds (some seen end-on and some sideways) can be demonstrated in the inactive rectum. During a contraction, the folds change direction to lie parallel to the long axis (i.e. longitudinally).

PRESENT EXPERIMENTAL FINDINGS

Animal Observations

Laparotomy was performed under general anaesthesia on 5 normal, adult baboons (*Papio ursinus*). A loop of small bowel was brought to the surface and filled with barium sulphate suspension. Simultaneous radiographs and photographs were taken in the filled, inactive state and after direct electrical stimulation of the serosa by means of a Ruhmkorff induction coil. Stimulation caused a visible, circumferential contraction of the walls, varying in length from 5 mm to 2.5 cm. In all experimental animals the same features were seen, i.e. in the filled, inactive state all mucosal folds were circular (Fig. 11). During a contraction of the walls, the mucosal folds changed

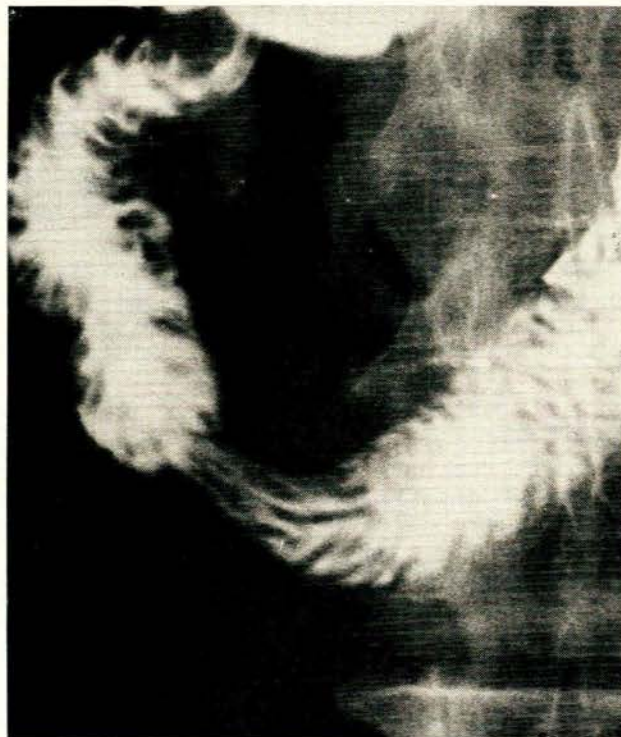


Fig. 4. Duodenal loop. In aperistaltic areas mucosal folds are transverse and oblique. Within peristaltic contraction folds have changed direction and are longitudinal.



Fig. 5. Jejunum. Transverse and oblique mucosal folds in filled, inactive areas. Within a peristaltic contraction, folds change direction to become longitudinal.

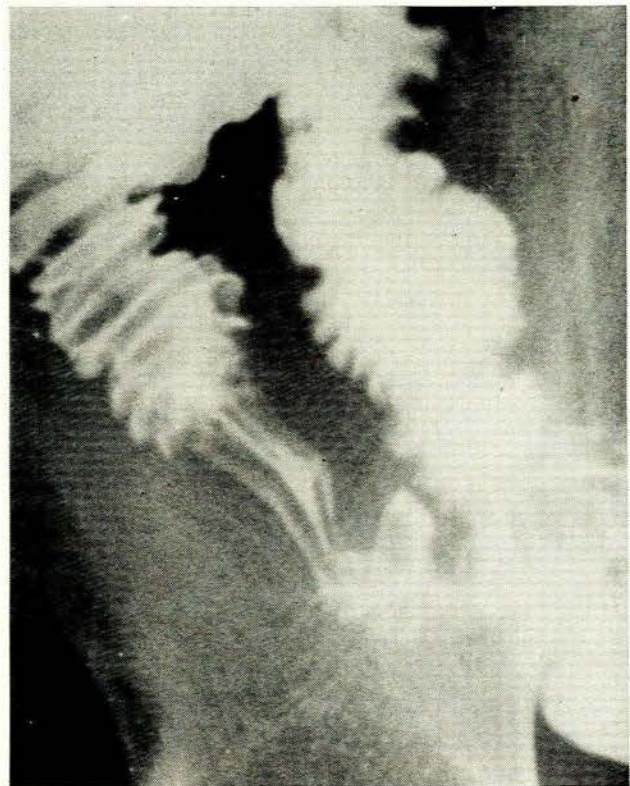


Fig. 6. Terminal ileum. Circular and oblique mucosal folds in inactive area. Within segmental contraction, folds have changed direction to become longitudinal.

direction to become longitudinal. This was seen both in annular and more segmental contractions (Figs 12 and 13).

In one animal the colon was examined in a similar way. After effacing the haustrations by massaging movements, the same features were observed. In one animal a second loop of small bowel was filled with barium and lightly clamped. A radiograph in the filled, inactive state showed only circular mucosal folds. Stretching the loop by moving the clamps in opposite directions caused the folds to change direction and become longitudinal (Fig. 14).

Wire Spirals

From the above it appears that there is a prompt, smooth, and uninterrupted transition of the folds from circular to longitudinal, and vice versa. Naturally, the concomitant furrows share in this change of direction. If a length of wire were used as a model, it would be clear that such a transition could only be achieved by a spiral arrangement (where the turns in the wire represent circular folds) (Fig. 15). Consequently, it could be accepted that, during life, a spiral arrangement of the circular folds is present. The spiral may be of any length, and may consist of as few as 1 or 2 folds.

Interlocking 2 identical wire spirals produces a more complicated pattern (Fig. 16). The majority of the folds

are still circular (or spiral), but a strong element of oblique folds is present as well. Stretching the wire causes the folds to straighten out.

DISCUSSION

Radiology shows that normally when the small bowel is filled but inactive (i.e. aperistaltic), the mucosal folds are circular. When a contraction of the walls occurs, the folds change direction to become longitudinal, and with a maximal contraction, only longitudinal folds are present in the contracted segment. This phenomenon is seen in the remainder of the gastro-intestinal tract as well, from the horizontal part of the stomach to the rectum. It occurs with both peristaltic and more segmental contractions, and can be verified experimentally in baboons. These animal experiments clearly show that the change in direction of the folds is secondary to a directly visible contraction of the muscularis propria. The features indicate a musculomucosal reflex, which, in our view, is part of the peristaltic reflex. The intrinsic intestinal reflexes described by Hukuhara *et al.*^{43,44} are of a different nature.

Stretching the bowel along its long axis also causes the circular folds to become longitudinal. This is probably

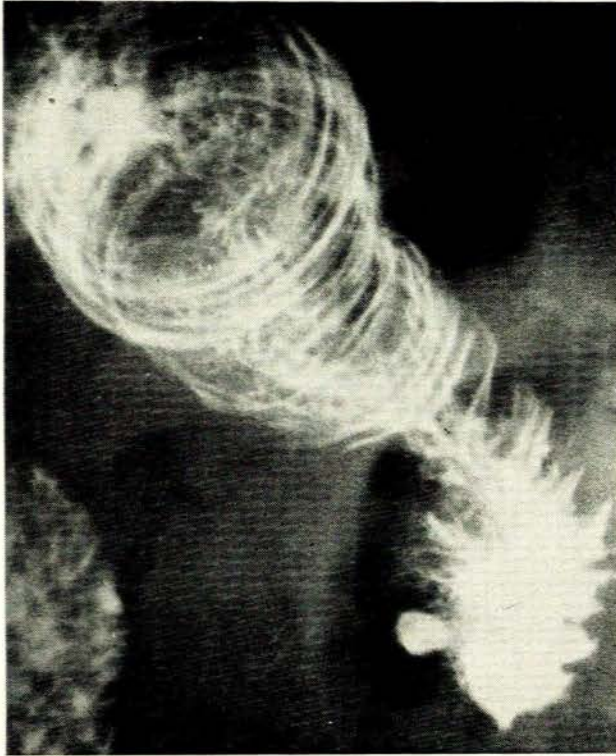


Fig. 7. Jejunum. Moderately distended, inactive loop, showing that transverse mucosal folds are in reality circular.

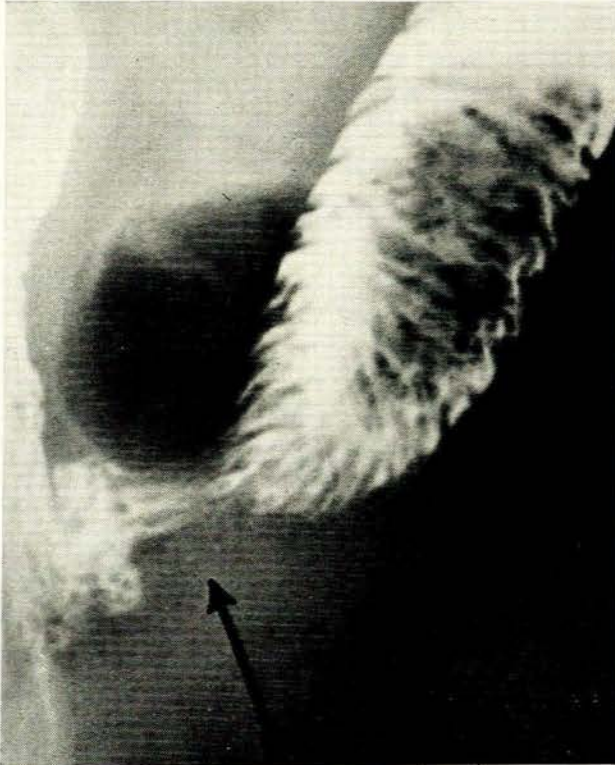


Fig. 8. Jejunum. Transverse and oblique mucosal folds in inactive area. Within peristaltic contraction, folds have become longitudinal. Arrow indicates indistinctness due to movement of contraction wave.

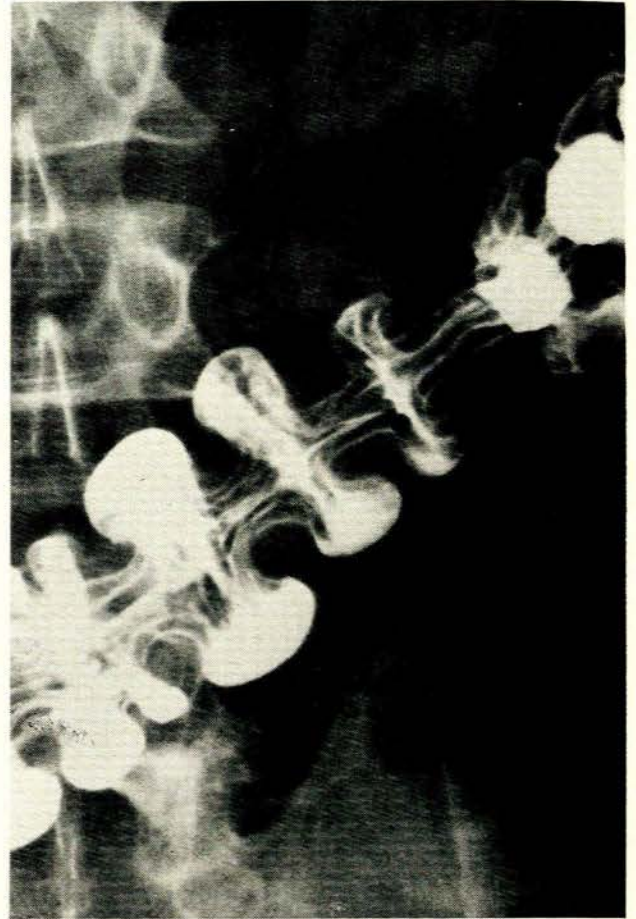


Fig. 9. Transverse colon. In haustra, mucosal folds are circular. In contracted segments between haustra, folds are longitudinal.

the reason for longitudinal folds in the vertical part of the stomach in the erect position.

In all instances there is an uninterrupted, smooth transition of the folds from circular to longitudinal, and vice versa. Simple wire experiments show that this is obtained with a spiral arrangement. Mucosal folds have concomitant furrows. Consequently there is an identical change in the direction of the furrows.

The findings confirm certain previous isolated radiological observations. Forssell's work, in which he described the fundamentals of the mucosal movements in great detail, is often overlooked, and little has been added to his findings. It appears, however, that he did not concern himself in the first place with the effects of peristalsis on the direction of the macroscopic folds. The phenomenon described can be looked upon as a by-product of that work.

Consequently, it is clear that the position or direction of the mucosal folds in the various divisions of the gastrointestinal tract, is not constant during life. Generally speaking, the folds are circular in the filled, aperistaltic state, and become longitudinal during active contractions of the muscular wall.

CONCLUSION

If it were true that circular mucosal folds in the small bowel were permanent, it would follow that progressive, propagating contraction waves (peristaltic waves) of the muscularis propria would need a considerable degree of energy to overcome the resistance offered by the large number of folds projecting diagonally into the lumen. It would be a poor mechanism indeed, and not in keeping with the intricate, dynamic organisation of highly-developed organic life. If, on the other hand, the folds could change direction simultaneously with a contraction wave of the walls, to form longitudinal internal furrows, the mechanism would be as near perfect as possible.

As described above, this appears to be the exact state of affairs during life. During contraction of the muscularis propria, circular mucosal folds become longitudinal, thus forming longitudinal furrows which act as a conduit for intestinal contents. By means of this musculo-mucosal reflex, transit of gastro-intestinal contents is enhanced. During times of digestion and absorption, transit needs to be inhibited. This is achieved by an aperistaltic state of the muscular walls and circular, restraining, internal folds.

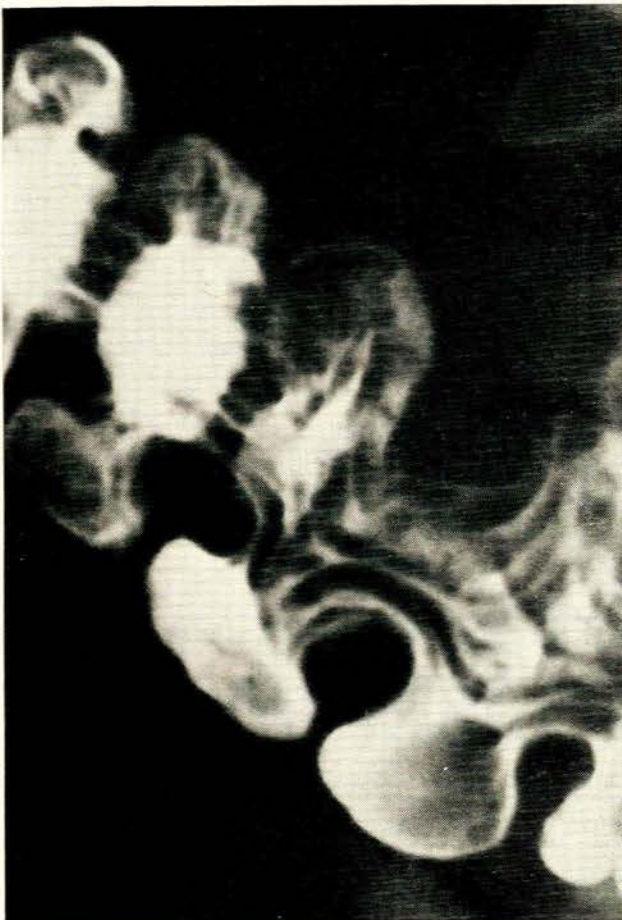

Fig. 10. Colon. At junction of haustra and contracted segment, mucosal folds are oblique or spiral.

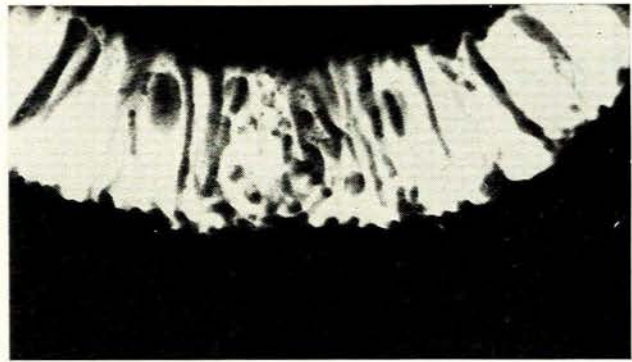


Fig. 11. Radiograph of intact, living, barium-filled baboon jejunum. Filled, inactive state, showing circular mucosal folds (oval radiolucent areas are collections of intestinal gas).

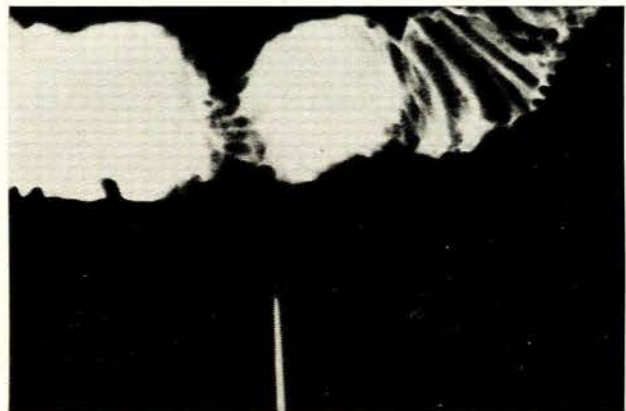


Fig. 12. Same as Fig. 11. Indicator points to visible, circumferential contraction of muscularis propria due to electrical stimulation. Mucosal folds in contracted area have changed direction to become longitudinal.

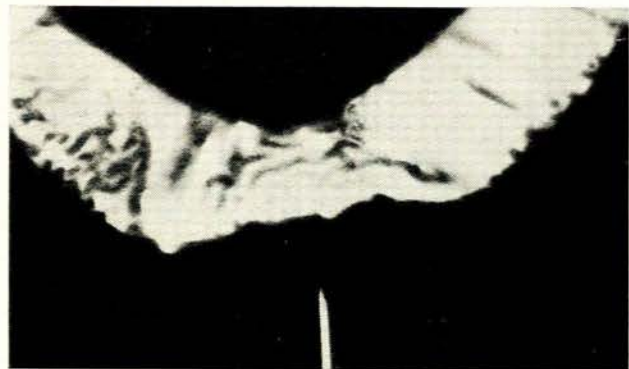


Fig. 13. Same as before. With wider, segmental contraction of muscularis propria, mucosal folds also become longitudinal.

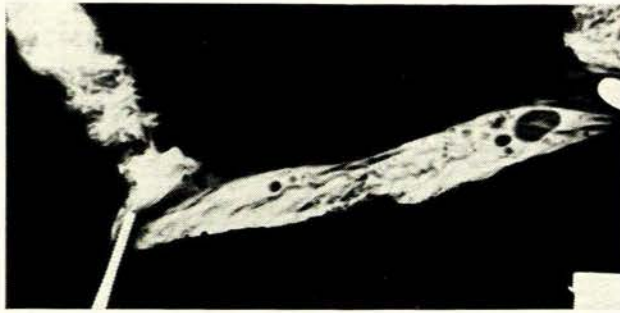


Fig. 14. Same as before. Stretching segment of baboon jejunum *in vivo* between 2 clamps, causes mucosal folds to become longitudinal.




Fig. 15. Radiograph of wire spiral. For an uninterrupted transition from circular to longitudinal, a spiral arrangement is necessary.



Fig. 16. Interlocking of 2 identical wire spirals shows a mixture of transverse and oblique elements due to summation in the 2-dimensional radiological image.

The animal experiments were done with the active assistance of Drs J. J. Heydenrych and J. H. Groenewald of the Department of Surgery, University of Stellenbosch.

REFERENCES

- Code, C. F., Hightower, N. C. and Morlock, C. G. (1952): *Amer. J. Med.*, **13**, 328.
- Fouk, W. T., Code, C. F., Morlock, C. G. and Bargen, J. A. (1954): *Gastroenterology*, **26**, 601.
- Connell, A. M. (1961): *Postgrad. Med. J.*, **37**, 703.
- Texter, E. C. (1963): *J. Amer. Med. Assoc.*, **184**, 640.
- Idem* (1964): *Amer. J. Dig. Dis.*, **9**, 585.
- Ramorino, M. L. and Colagrande, C. (1964): *Ibid.*, **9**, 64.
- Deller, D. J. and Wang, A. G. (1965): *Gastroenterology*, **48**, 45.
- Torsoli, A., Ramorino, M. L. and Crucoli, V. (1968): *Amer. J. Dig. Dis.*, **13**, 462.
- Prosser, C. L. (1965): *Gastroenterology*, **49**, 389.
- Farrar, J. T. and Zfass A. (1967): *Ibid.*, **52**, 1019.
- Code, C. F. (1968): *Handbook of Physiology*, sect. 6, vol. 4. Washington, D.C.: American Physiological Society.
- Brooks, F. P. (1970): *Modern Concepts in Medical Physiology*. London: MacMillan.
- Demling, L. and Ottenjann, R. (1971): *Gastrointestinal Motility*. London: Academic Press.
- Last, R. J. (1963): *Anatomy Regional and Applied*, 3rd ed., p. 412. London: J. & A. Churchill.
- Gray, H. (1956): *Gray's Anatomy*, 31st ed., p. 1402. London: Longmans Green.
- Cunningham, D. J. (1964): *Textbook of Anatomy*, 10th ed., p. 415. London: Oxford University Press.
- Bloom, W. and Fawcett, D. W. (1966): *A Textbook of Histology*, 8th ed., p. 444. London: W. B. Saunders.
- Haubrich, W. S. in Bockus, H. L., ed. (1964): *Gastroenterology*, 2nd ed., vol. 2, p. 6. London: W. B. Saunders.
- Meschan, I. (1968): *Normal Radiographic Anatomy*, 2nd ed., p. 624. London: W. B. Saunders.
- Schofield, G. C. (1968): *Op. cit.*¹¹
- Lockhart, R. D., Hamilton, G. F. and Fyfe, F. W. (1959): *Anatomy of the Human Body*, p. 518. London: Faber & Faber.
- Greisheimer, E. M. (1963): *Physiology and Anatomy*, 8th ed. Philadelphia: J. B. Lippincott.
- Bell, G. H., Davidson, J. N. and Scarborough, H. (1968): *Textbook of Physiology and Biochemistry*, 7th ed. London: E. & S. Livingstone.
- Guyton, A. C. (1971): *Textbook of Medical Physiology*, 4th ed. London: W. B. Saunders.
- Best, C. H. and Taylor, N. B. (1961): *The Physiological Basis of Medical Practice*, 7th ed., p. 711. Baltimore: Williams & Wilkins.
- Forssell, G. (1913): *Fortschr. Röntgenstr.*, suppl. 30.
- Idem* (1923): *Amer. J. Roentgenol.*, **10**, 87.
- Idem* (1939): *Ibid.*, **41**, 145.
- Cole, L. G. (1934): *Radiologic Exploration of the Mucosa of the Gastro-intestinal Tract*. St Paul: Bruce Publishing.
- Brooks, F. P., Stevens, L. W., Pendergrass, E. P. and Bassols, F. (1948): *Amer. J. Roentgenol.*, **59**, 482.
- Deucher, W. (1951): *Schweiz. med. Wschr.*, **49**, 1194.
- Sloan, R. D. (1957): *Amer. J. Roentgenol.*, **77**, 651.
- Golden, R. (1937): *J. Amer. Med. Assoc.*, **109**, 1497.
- Idem* (1969): *Diagnostic Radiology*, sect. 5, p. 5601. Baltimore: Williams & Wilkins.
- Templeton, F. E. ((1947): *X-ray Examination of the Stomach*, p. 135. Chicago: University of Chicago Press.
- Buckstein, J. (1948): *The Digestive Tract in Roentgenology*, p. 414. Philadelphia: J. B. Lippincott.
- Shanks, S. C. and Kerley, P. (1950): *A Textbook of X-ray Diagnosis*, 2nd ed., vol. 3, pp. 167, 290, 343. London: H. K. Lewis.
- Keet, A. D. (1953): *S. Afr. Med. J.*, **27**, 117.
- Schinz, H. R., Baensch, W. E., Friedl, E. and Uehlinger, E. (1954): *Roentgen-Diagnostics*, 1st American ed., vol. 4, p. 3419. New York: Grune & Stratton.
- Paul, L. W. and Juhl, J. H. (1972): *The Essentials of Roentgen Interpretation*, 3rd ed., p. 603. London: Harper & Row.
- Harper, R. A. K. (1967): *Radiology of the Duodenum*, p. 11. London: Lloyd-Luke.
- Torgersen, J. (1942): *Acta radiol. (Stockh.)*, suppl. 45.
- Hukuhara, T., Yamagami, M. and Nakayama, S. (1958): *Jap. J. Physiol.*, **8**, 9.
- Hukuhara, T., Sumi, T. and Kotani, S. (1961): *Ibid.*, **11**, 205.