

# Dyskeratosis Congenita : Two Extremes

J. G. L. MORRISON

## SUMMARY

The first two cases of dyskeratosis congenita recognised in South Africa are described. An iron deficiency as the possible cause of the disease is discussed and rejected. The epithelial changes are regarded as the result of an underlying pathology in the mesoderm.

*S. Afr. Med. J.*, 48, 223 (1974).

Outside the USA, where dyskeratosis congenita was first discovered, surprisingly few examples of this disorder have been identified and described. The first two South African cases to be recognised—a severe instance in a young White schoolboy, and a mild one in a young Black adult—had each been treated hitherto as having an assembly of apparently unrelated troubles.

## CASE REPORTS

The features of dyskeratosis congenita are of such diversity that each tends to be discussed in different articles, the key references to which are placed for convenience against the particular feature of the disease in the ensuing case description.

### Case 1

A 15-year-old White schoolboy was normal except for the following:

**Sun sensitivity:** He had sunburned readily all his life, and developed a permanently thin, seemingly translucent erythematous and telangiectatic skin<sup>1</sup> on the exposed parts, with solar keratoses on the forehead.

**Hands:** From the age of 7 years the tips of his fingers and toes and nail regions developed repeated ulcerative and infected lesions, leading to dystrophy, pterygium formation (Fig. 1), loss of nails<sup>2</sup> (Fig. 2), and a loss of ridge patterns on the fingertips. At times spontaneous bullae<sup>3</sup> occurred, sometimes preceding the infection, and histological examination of a bulla from the dorsum of the foot showed it to be subepidermal. The skin showed a ready tendency to sepsis from minor injuries. There was palmoplantar hyperhidrosis.<sup>2</sup>

**Eyes:** The lacrimal puncta<sup>3</sup> became obliterated and two unsuccessful attempts had been made to open them surgically. Epiphora<sup>3</sup> and repeated blepharitis led to loss

of some lower lid eyelashes, with overriding of squamous epithelium on to the palpebral conjunctiva in this area.

**Mouth:** From 11 years of age the buccal cavity began showing repeated mucosal ulceration (Fig. 3), with restriction of all buccal functions from pain, ulceration, bleeding and fibrosis. Histologically the ulcerated area consisted of granulation tissue with plasma cell and lymphocyte infiltration and underlying fibrosis. There was no evidence of malignant change.<sup>3</sup> An anterior web was present in the hypopharynx at the C4-C5 level, and at C6 there was a stenosis<sup>4,5</sup> (Fig. 4), preventing the passage of an oesophagoscope. The narrow zone tore and bled when dilated to a diameter of about 1 cm, thus accounting for the dysphagia.<sup>5</sup>

**Genitals:** The penis showed a small erosion.

**Poikiloderma-like changes:** Atrophy with a reticulated pigmentation was concentrated on the sides of the neck, axillae, groins, and inner thighs. The pigment was deposited particularly in the small skin creases of the epidermal relief pattern. Histologically there was epidermal atrophy and pigment incontinence.

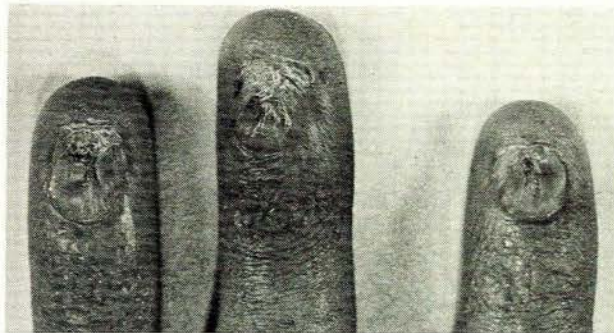


Fig. 1. Dystrophy and pterygium formation of finger-nails in dyskeratosis congenita (case 1).

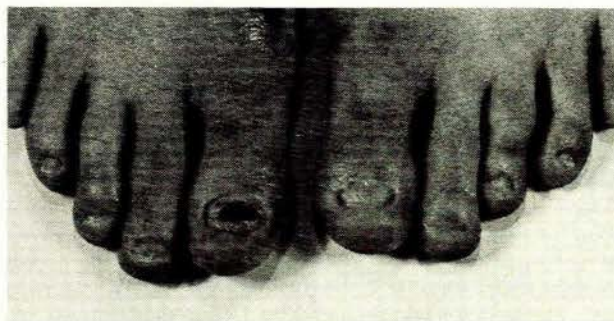


Fig. 2. Dystrophy, pterygium formation and loss of toe-nails in dyskeratosis congenita (case 1).

Department of Dermatology, University of Pretoria  
J. G. L. MORRISON, M.B. CH.B.

Date received: 11 September 1973.

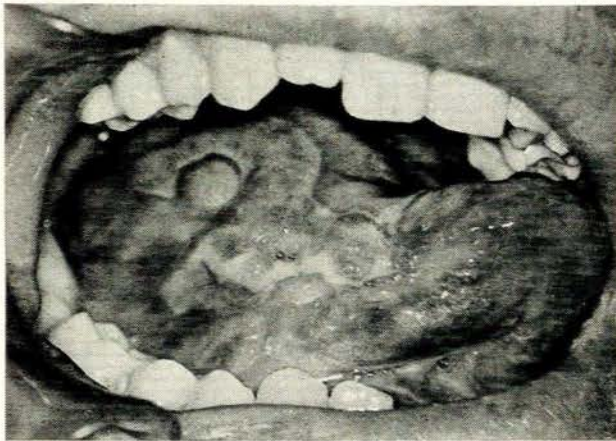


Fig. 3. Dyskeratosis congenita. Mucosal ulceration and fibrosis (case 1).

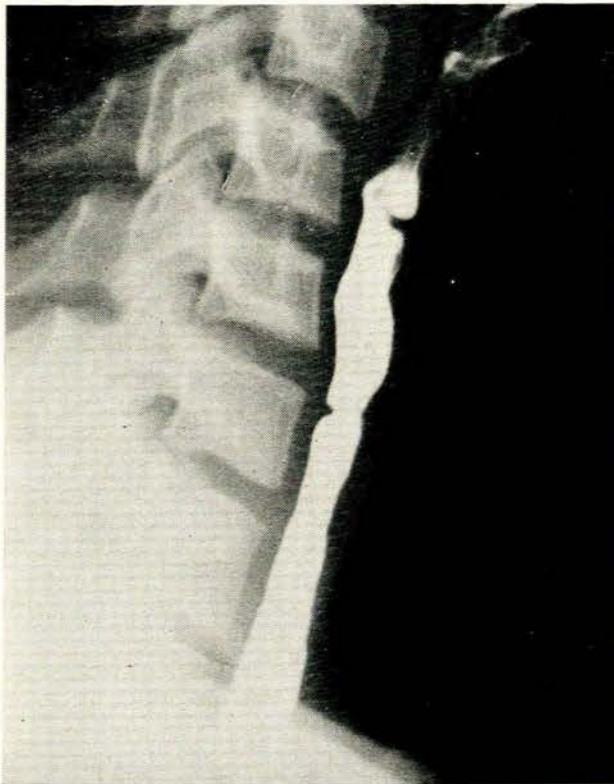

Fig. 4. Dyskeratosis congenita. Web in the hypopharynx and stenosis at C6 in the oesophagus (case 1).

**Genetics:** No other family member<sup>4,6</sup> or sibling was similarly affected. Apart from the ridge pattern absent from the fingertips, the dermatoglyphics were not abnormal. The peripheral leucocyte culture showed a high (at least 20%) incidence of chromosome breaks.<sup>7</sup>

**Blood picture, bone marrow and iron metabolism:** The only abnormal finding was a persistently low platelet count<sup>8</sup> (about 80 000/mm<sup>3</sup>).

**Proteins, immune systems, amino acids:** There were trivial deviations in the serum protein values. No abnormal amino-acidurias, abnormal immuno-electrophoreses, or thyroid auto-antibodies were found. Plasma cells were seen in the bone marrow, and in abundance in the inflammatory infiltrate round the tongue ulcers.

## Case 2

A 20-year-old Black male of small stature showed the following:

**Skin:** Partial loss of finger- and toe-nails, with pterygium formation following sepsis from 8 years of age. There was absence of fingerprint patterns on the distal parts of the finger pads. The texture of the facial skin was delicate. Reticulated pigmentation was distributed as in case 1. Histologically these areas showed epidermal atrophy, incontinence of pigment over the dark areas and some subepidermal fibrosis.

**Buccal cavity:** At the age of 15 years, ulcers of the tongue and cheeks appeared and healed with scarring, but did not recur. Histologically the overlying tongue and cheek epithelia were smooth, with submucous fibrosis in the scarred sites. There was some lymphocytic infiltration.

**Eyes:** Since the age of 12 the eyes had watered persistently. The lacrimal puncta were destroyed.

**Genetics:** The family history seemed negative. Breaks were present in at least 10% of chromosomes in leucocyte culture.

**Blood count, marrow and iron studies:** No abnormality was detected except for a low serum iron and raised iron binding capacity (41,8 and 411,9  $\mu\text{g}/100\text{ ml}$  respectively).

## DISCUSSION

In dyskeratosis congenita a remarkable combination of lesions is to be found. The mouth, throat, finger- and toe-nails and haemopoietic system are affected. To interpret this association of lesions one may think of parallel conditions, for instance Plummer-Vinson syndrome, sideropenic dysphagia, iron deficiency anaemia and chronic mucocutaneous moniliasis in which similar areas are affected.

An association with iron metabolism seems possible as a means of unifying these features. Thus it has been suggested that a lack of tissue iron contributes to the development of symptoms in all the disorders mentioned (chronic mucocutaneous moniliasis,<sup>9</sup> Plummer-Vinson syndrome,<sup>10</sup> sideropenic dysphagia).<sup>11</sup> However, in each the relationship with iron deficiency was found to be variable and uncertain, to the point of eliminating it altogether as the common factor. One has to explain why an iron deficiency, which is so common, so rarely gives rise to special changes in the mucosae and nails. Although a lack of iron is suspected as being the common factor, the lesions differ greatly among themselves in this diversity of diseases. Difficulties in food intake may result in an iron deficiency, aggravated by blood loss from ulceration. An iron deficiency would therefore seem to be the result rather than the cause of the mucosal changes.

Shrinkage and stenosis of tubular or cavitory structures are not a result of purely epithelial pathology but require the involvement of subepithelial and submucosal tissue. There is nothing to suggest that the changes in this disease are primarily epithelial. Epithelial atrophy may as well be the consequence of disturbed or fibrotic subepithelial tissue.

There is a strong possibility that epithelial changes in dyskeratosis congenita are secondary to mesodermal pathology underlying the surface, similar to bone marrow aplasia, which is a mesodermal lesion.

I should like to thank Professor I. W. Simson, Professor L. M. Jonck, Dr C. S. Kingsley, Dr C. Brits, Dr I van der

Werke and Dr R. C. P. M. Mekel, for assistance with the special investigations.

## REFERENCES

1. Costello, M. J. and Buncke, C. M. (1956): *Arch. Derm.*, **73**, 123.
2. Cole, H. N., Rauschkolb, J. E. and Toomey, J. (1930): *Arch. Derm. Syph.*, **21**, 71.
3. Sorrow, J. M. jun. and Hitch, J. M. (1963): *Arch. Derm.*, **88**, 340.
4. Garb, J. and Rubin, G. (1944): *Arch. Derm. Syph.*, **50**, 191.
5. Schamberg, I. L. (1960): *Arch. Derm.*, **81**, 266.
6. Jansen, L. H. (1951): *Dermatologica*, **103**, 167.
7. Bloom, G. E., Warner, S., Gerald, P. S. and Diamond, L. K. (1966): *New Engl. J. Med.*, **274**, 8.
8. Steier, W., Van Voolen, G. A. and Selmanowitz, V. J. (1972): *Blood*, **39**, 510.
9. Higgs, J. M. and Wells, R. S. (1972): *Brit. J. Derm.*, **86**, suppl. 8, p. 88.
10. Waldenström, J. (1938): *Acta med. scand.*, suppl. 90, p. 380.
11. Dagg, J. H., Jackson, J. M., Curry, B. and Goldberg, A. (1966): *Brit. J. Haemat.*, **12**, 331.