

Turner Phenotype with Normal Sex Chromosomal Pattern and Congenital Heart Disease (Noonan's Syndrome)

R. L. VAN DER HORST

SUMMARY

Five patients with cardiovascular anomalies and Noonan's syndrome are described. In each instance, pulmonary stenosis with or without an atrial septal defect was present. Noonan's syndrome is similar to Turner's syndrome, but in the former both males and females are affected and the chromosomal pattern is normal. Webbing of the neck, shortness of stature, hypertelorism and other features are common to both syndromes.

S. Afr. Med. J., 48, 219 (1974).

The purpose of this article is to briefly describe 5 patients with cardiovascular malformations who have Noonan's syndrome.¹⁻¹⁸ In this syndrome patients have many features

of Turner's syndrome. The distinguishing features between Noonan's and Turner's syndrome are that in the former, both males and females are affected and have normal chromosomal patterns, in contrast to those with Turner's syndrome, the majority of whom are phenotypic females, 90% of whom have sex chromosomal monosomy (45: XO), or rarely, chromosomal mosaicism. The nature of the cardiac lesion is usually distinctive and different in these two similar syndromes.

CASE REPORTS

Case 1 (Fig. 1)

A Black male was referred for evaluation of a cardiac murmur at 13 years of age. Striking features on examination were an odd facies, hypertelorism, micrognathia, low-set ears, protruding eyes, ptosis and marked webbing of the neck. His skin was coarse and mild cubitus valgus was present. Other features were antimongoloid slanting

Cardiac Unit, Wentworth Hospital and University of Natal, Durban

R. L. VAN DER HORST, M.B. CH.B., M.MED. (PAED.), Part-time Senior Paediatrician and Senior Paediatric Cardiologist

Date received: 29 August 1973.

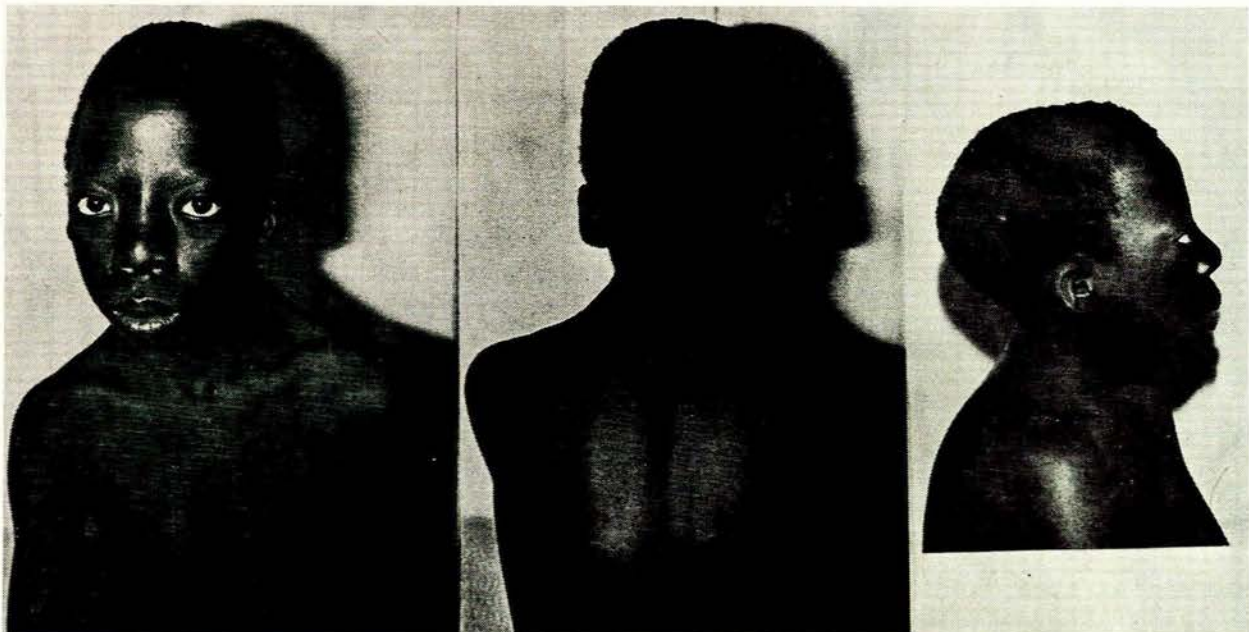

Fig. 1. Black youth aged 13 years.

of his eyes, short stature, pectus carinatum, wide nipples, an arched palate, a small right testis in the right groin with an impalpable left testis, an underdeveloped scrotum and a large phallus. Chromosomal analysis showed a normal male karyotype with 46 XY pattern. His height was 135 cm.

Right and left cardiac catheterisation with selective angiography confirmed a small gradient across the pulmonary valve, which was thickened, indicating mild valvular pulmonary stenosis. The right pulmonary artery was slightly stenosed. No treatment was offered and the patient was discharged.

Case 2 (Fig. 2)

An Indian female was submitted to cardiac catheterisation and angiography at 6½ years of age because of a heart murmur detected by her doctor when she entered

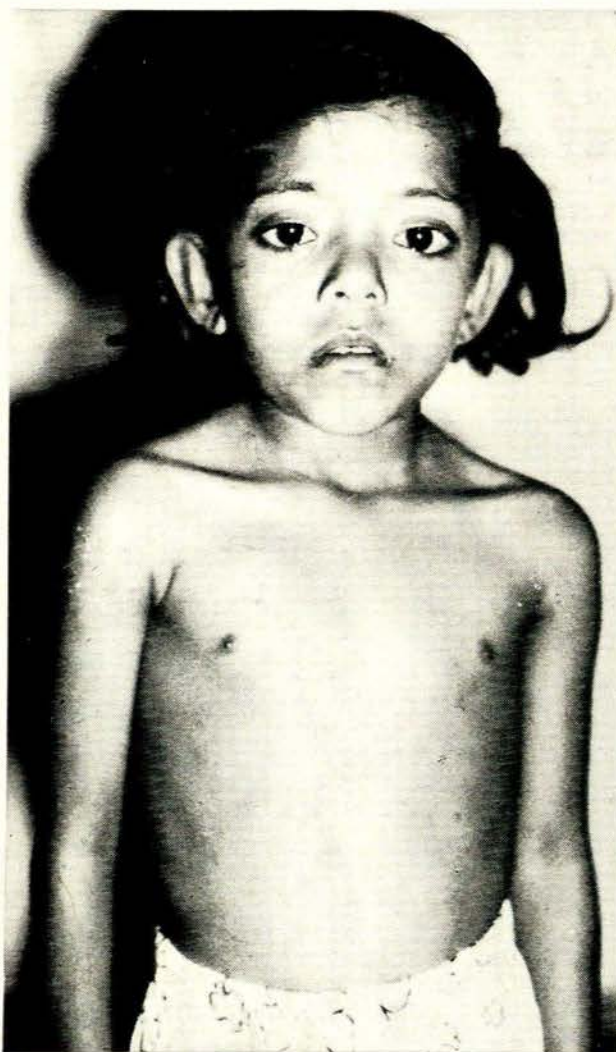

Fig. 2. Indian female aged 6½ years.

school. Two older sisters, a younger brother and her parents are normally developed. Striking features on examination were an odd facies with hypertelorism, slight webbing of the neck, cubitus valgus and short stature (height 101 cm).

Chromosomal analysis revealed a normal 46 XX pattern. In view of the electrocardiogram which showed a QRS axis of -150° , she was considered to have an endocardial cushion type of atrial septal defect. Left and right cardiac catheterisation showed a peak systolic gradient of 14 mm across the pulmonary valve, and an atrial septal defect with a 27% left-to-right shunt and 33% right-to-left shunt, which was confirmed on indicator dilution studies. The left-to-right shunt was greater from the left than from the right lung. The right-to-left shunt was shown to be only from the inferior vena cava. Selective angiography excluded the presence of the swan-neck outflow tract deformity of the left ventricle—characteristic of endocardial cushion defect. A fossa ovalis atrial septal defect was confirmed on selective left atrial angiography as also the right-to-left shunting from the inferior vena cava. Surgery was not considered necessary and the patient was discharged.

Case 3 (Fig. 3)

This White female was referred for evaluation of a cardiac murmur at 4 years of age. On examination she had hypertelorism, a short webbed neck, broad nipples and cubitus valgus. Her height was 94 cm. Examination of the heart, electrocardiogram and chest X-ray film suggested the presence of severe valvular pulmonary stenosis. At cardiac catheterisation the right ventricular systolic pressure measured 80 mmHg with a 60 mmHg peak systolic gradient across the pulmonary valve which was narrowed and thickened. An atrial septal defect was also present. At operation, the pulmonary valve stenosis was relieved and a large atrial septal defect closed. Chromosomal analysis showed a normal female (XX) karyotype.

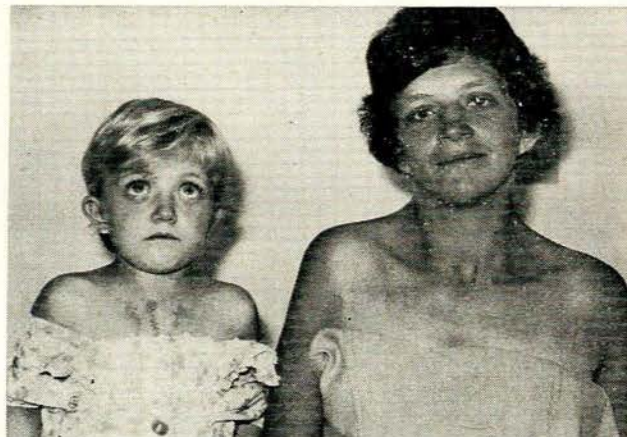

Fig. 3. Daughter (case 3) on left, and mother (case 4) on right.

Case 4 (Fig. 3)

The mother of patient 3 is of short stature, has cubitus valgus and a webbed neck. Cardiac examination suggests the presence of mild pulmonary stenosis and chromosomal analysis shows a normal female (XX) karyotype.

Case 5 (Fig. 4)

This patient initially underwent cardiac investigation at the age of 2 years and the findings have been reported elsewhere.²⁰ The cardiovascular abnormalities present were: a thickened pulmonary valve due to pulmonary stenosis with a peak systolic gradient of 40 mmHg across the pulmonary valve; a sinus venosus atrial septal defect with a left-to-right shunt of 11,0 L/min/m², normal drainage of the pulmonary veins; normal drainage of the right superior vena cava; a left superior vena cava draining the left subclavian and left jugular veins and entering the right atrium via the coronary sinus; normal drainage of the right hepatic vein into the inferior vena cava and anomalous drainage of the left hepatic vein into the coronary sinus. Extracardiac features of importance were sternal depression, widely-spaced nipples, short stature, webbing of the neck and bilateral epicanthus, and also a small nasal bridge. Chromosomal studies showed a normal male (XY) karyotype.

Surgical closure of the atrial septal defect was performed

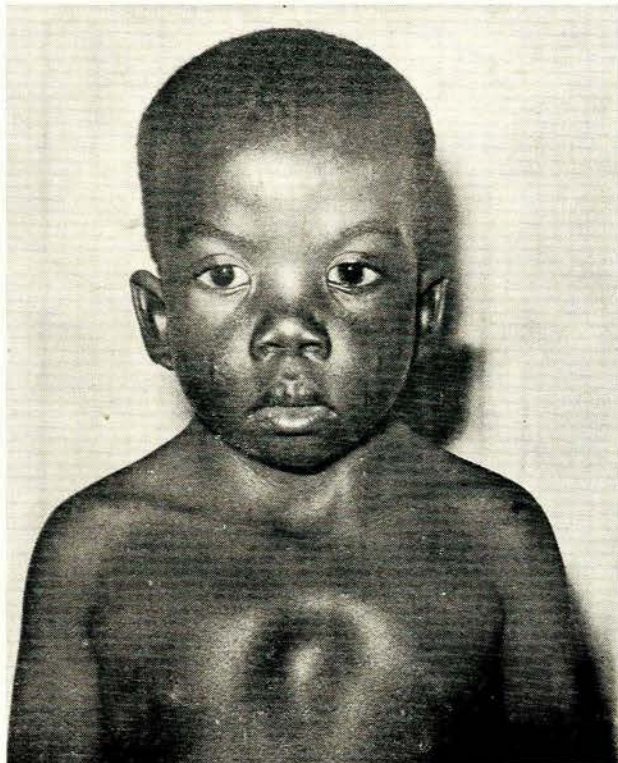


Fig. 4. Black male child aged 5 years.

at 5 years of age and the postoperative course was uneventful. His height at this time was 80 cm.

DISCUSSION

In 1938 Turner described a syndrome of short stature, webbing of the neck, cubitus valgus and sexual and skeletal infantilism.²⁰ It was later shown that most of these patients had ovarian agenesis. In 1930 Ullrich²¹ had described similar features in an 8-year-old girl who also had lymphoedema, and he collected additional children with this syndrome. Since Ullrich's patients were young, he did not recognise the presence of sexual infantilism. In 1934, Bonnevie's experimental work clarified the gonadal dysplasia,²² and sometimes the double eponym 'Bonnevie-Ullrich's syndrome' has been used to describe these patients, while other workers have called this condition 'Bonnevie-Ullrich-Turner syndrome'—and others the 'Ullrich-Turner syndrome'.²³ Polani²⁴ has used the name 'Ullrich's syndrome' for those patients with normal chromosomes and the Turner phenotype—others have used the term 'Turner phenotype and related syndromes'. The term 'pseudo-Turner's syndrome' has also been used, while the majority of cardiologists have preferred to call it 'Noonan's syndrome',¹⁻³⁸ emanating from Noonan and Ehmke's description of a number of patients with similar facies and certain features of Turner's syndrome.¹ In 1968 Noonan reported a larger series² and subsequently additional reports have been published in paediatric and cardiology journals under the eponym 'Noonan's syndrome'.³⁻³⁸ These selected reports cite many other references on the subject in addition to discussions of nomenclature, for example, Summitt³⁸ is of the opinion that patients with Noonan's syndrome do not have Turner's phenotype—even though many reports appear under this name. He is of the opinion that the only valid examples of the male Turner's syndrome are those with abnormal karyotypes. Other workers, however, feel that Noonan's syndrome is specific, but that it is related to the Turner phenotype.

In South Africa, few cases of Turner's syndrome have been reported. In 1953 Mibashan and Jackson described 3 phenotypic females with Turner's syndrome, and one male.²⁴⁻²⁵ This was followed by the report of MacKenzie describing the first case in a Zulu, a male youth aged 19 years.²⁶ Two further cases were reported by Jackson and Hoffenberg in 1957²⁷ and an additional 3 cases by Hoffenberg, Jackson and Muller.²⁸ In none of these reports was there any comment in respect of the cardiovascular system and the study of chromosomes had, at this time, not been developed. In 1964 Klempman,²⁹ and in 1969 Witton,³⁰ reviewed their respective experiences with cytogenetic studies at the South African Institute for Medical Research. Again, cardiac lesions were not described. The patients were phenotypic females—all with chromosomal aberrations. In 1971, Grace²¹ reported 8 phenotypic Zulu females, 5 of whom had chromosomal abnormalities. It is possible that his cases 6 and 7 (mother and infant), and his case 8, (all of whom had an XX sex chromosomal pattern) were in fact patients with Noonan's syndrome. In none is there mention of a cardiac disorder. In 1971 Levin briefly described 2

Black children with probable Noonan's syndrome.³² A ventricular septal defect was present in one, and in the other an endocardial cushion defect with pulmonary stenosis. Three other patients were mentioned—one with probable pulmonary stenosis. While Levin was the first to draw attention to Noonan's syndrome in this country, chromosomal studies were not performed on these patients.³³ It would thus appear that Noonan's syndrome has probably been recognised as an entity in South Africa, but there has been lack of confirmation of a normal chromosomal pattern in some, while in others, no cardiac lesions were described. Other cases may have been seen and were either not recognised or not reported.

Cardiovascular Anomalies

Cardiovascular anomalies are an important feature of Noonan's syndrome and also of Turner's syndrome. In the latter, coarctation of the aorta is the most frequently occurring defect, although other malformations such as aortic stenosis, sub-aortic stenosis and lesions with left-to-right shunts have been found.

In contrast, in Noonan's syndrome, pulmonary valvular stenosis with or without an atrial septal defect has been the most frequently reported anomaly, while aortic stenosis, coarctation of the aorta, pulmonary arterial branch stenosis, ventricular septal defect, patent ductus arteriosus, eccentric ventricular hypertrophy and hypertrophic obstructive cardiomyopathy, have been less frequently described.

Non-Cardiovascular Anomalies

Table I lists the major non-cardiac features present in most patients with Noonan's syndrome. The limitations of this table must be emphasised, and while numerous features may be present in a specific patient, another patient may not have so many. Less frequent abnormalities present include clinodactyly, hernias, vertebral abnormalities (as in the Klippel-Feil syndrome) and lymphoedema. The latter is usually present in about 25% of infants with Noonan's syndrome and disappears in the majority of patients as they grow older. Mental retardation is often present, but not always. The spectrum of gonadal

defects is wide, varying from severe deficiency to apparently normal sexual development. The reader is referred to the references cited for further details in regard to the non-cardiac aspects of this syndrome.

Familial Noonan's Syndrome

While Noonan's syndrome most often occurs sporadically, it is well documented that this disorder can be familial, occurring in 2 and 3 siblings, usually by transmission from an affected mother to her offspring, and rarely from an affected father to his offspring. Our cases 3 and 4 represent an example of transmission from mother to daughter. The disorder is occasionally transmitted as an autosomal dominant disorder, while a few cases have been transmitted by an X-linked inheritance. There are isolated examples in the literature of autosomal recessive transmission³⁴ as well as examples of autosomal structural anomalies.³⁵ The suggestion has been made that new 'point' mutations may result from undetectable chromosomal mutations as well as polygenetic mechanisms in the transmission of the disorder.³⁵

REFERENCES

- Noonan, J. A. and Ehmke, D. A. (1963): *J. Pediat.*, **63**, 468.
- Noonan, J. A. (1968): *Amer. J. Dis. Child.*, **116**, 373.
- Nora, J. J. and Sinha, A. K. (1968): *Ibid.*, **116**, 343.
- Wright, N. L., Summitt, R. L. and Ainger, L. E. (1968): *Ibid.*, **116**, 367.
- Celermajer, J. M., Bowdler, J. D. and Cohen, D. H. (1968): *Ibid.*, **116**, 351.
- Kaplan, M. S., Opitz, J. M. and Gossett, F. R. (1968): *Ibid.*, **116**, 359.
- Levy, E. P., Pashayan, H., Frazer, F. C. and Pinsky, L. (1970): *Char. F.* (1971): *J. Amer. Med. Assoc.*, **216**, 680.
- Ferrier, P. E. and Ferrier, S. A. (1967): *Pediatrics*, **40**, 575.
- Summitt, R. L. (1970): *J. Pediat.*, **75**, 730.
- Miller, A. P., Stonecipher, H. K. and Boyd, B. (1970): *J. Amer. Med. Assoc.*, **214**, 2337.
- Nora, J. J., Torries, F. G., Sinha, A. K. and McNamara, D. G. (1970): *Ibid.*, **214**, 2337.
- Chaves-Caraballo, E. and Hayles, A. B. (1966): *Proc. Mayo Clin.*, **41**, 843.
- Ehlers, K. H., Engle, M. A., Levin, A. R. and Deely, W. J. (1972): *Circulation*, **44**, 639.
- Siggers, D. C. and Polani, P. E. (1972): *Brit. Heart J.*, **34**, 41.
- Baird, P. A. and De Jong, B. P. (1972): *J. Pediat.*, **80**, 110.
- Phornphutkul, C., Rosenthal, A. and Nadas, S. A. (1973): *Brit. Heart J.*, **35**, 99.
- Summitt, R. L. (1969): *J. Pediat.*, **75**, 730.
- Van der Horst, R. L. and Gotsman, M. S. (1971): *Brit. Heart J.*, **33**, 164.
- Turner, H. H. (1938): *Endocrinology*, **23**, 566.
- Ullrich, O. (1930): *Z. Kinderheilk.*, **49**, 271.
- Bonnevie, K. (1934): *J. Exp. Zool.*, **67**, 443.
- Polani, P. G. (1961): *Brit. Med. Bull.*, **17**, 200.
- Mibashan, R. S. and Jackson, W. P. U. (1953): *Brit. Med. J.*, **2**, 371.
- Jackson, W. P. U. and Mibashan, R. S. (1953): *Ibid.*, **2**, 368.
- MacKenzie, D. F. (1953): *Ibid.*, **2**, 1273.
- Jackson, W. P. U. and Hoffenberg, R. (1957): *S. Afr. Med. J.*, **31**, 226.
- Hoffenberg, R., Jackson, W. P. U. and Muller, W. H. (1957): *J. Clin. Endocr.*, **17**, 902.
- Klempman, S. (1964): *Ibid.*, **38**, 234.
- Witton, E. (1969): *S. Afr. J. Surg.*, **7**, 45.
- Grace, J. (1971): *S. Afr. Med. J.*, **45**, 28.
- Levin, S. (1971): *Ibid.*, **45**, 216.
- Idem* (1971): Personal communication.
- Opitz, J. M., Sarto, G. E. and Summitt, R. L. (1966): *Lancet*, **2**, 282.
- Polani, P. E., Angell, R. and Polani, N. (1967): *Ibid.*, **2**, 421.

TABLE I. NON-CARDIAC FEATURES OF NOONAN'S SYNDROME*

Frequent	Less frequent
Webbing of the neck	Mental retardation
Short stature	Ptois
Usually specific cardiac malformations	Clinodactyly
Hypertelorism	Lymphoedema
Epicanthus	Vertebral anomalies
Antimongoloid slanting of the eyes	Gonadal defects
Micrognathia	
Chest deformities	
Widely spaced nipples	
Cubitus valgus	

*Listed only as a guide.