

THE DELAYED FILM IN HIRSCHSPRUNG'S DISEASE*

B. J. CREMIN, M.C.R.A., F.F.R., *Principal Specialist in Radiology, University of Cape Town, and Head of the Department of Paediatric Radiology, Red Cross War Memorial Children's Hospital, Cape Town*

The value of a film taken 24-48 hours after an examination for aganglionosis of the colon is of known value.¹ In the newborn, Berdon and Baker² found stasis the most definitive sign, but surgical intervention may prevent the taking of a delayed film.^{3,4}

In the 3-year period 1967-1969, 64 cases of Hirschsprung's disease were seen at this department, and 30 of these cases were in neonates. In the majority of these cases it was possible to obtain at least a 12-hour delayed film before surgery. The delayed films proved to be the most useful of the series, particularly when there was doubt regarding the diagnosis on the initial films. Routine anteroposterior and lateral delayed films are taken, and the lateral film has been particularly informative. At fluoroscopy, the aganglionic segment and the transition zone may be dilated by faeces so that the narrowed zone may not be obvious. During the delay period, the aganglionic segment moulds itself around the barium due to the arrhythmic writhings of the affected segment. The delayed films, especially the delayed lateral exposure, will show the narrowed zone to better advantage. It may be possible to actually visualize the arrhythmic contraction in some cases.

The following 4 cases illustrate these points. In all cases 50% barium was the contrast medium used.

ILLUSTRATIVE CASES

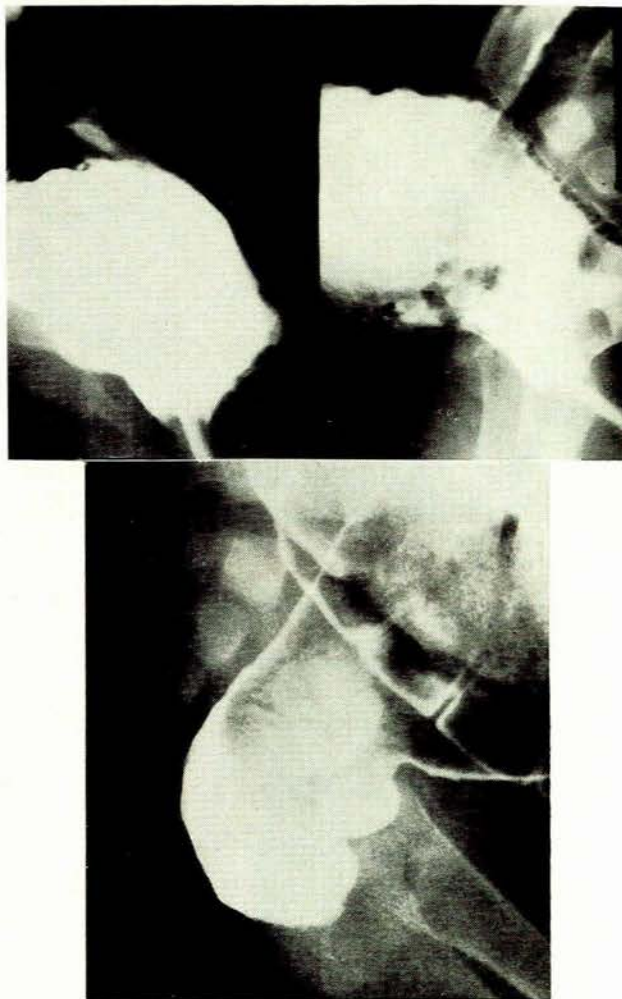
Lateral Delayed Film

A 1-year-old male child was admitted with abdominal distension, constipation and possible Hirschsprung's disease. The barium-enema appearance was equivocal and the narrowed area was not obvious on anteroposterior (Fig. 1(a)) or lateral (Fig. 1(b)) projections. The 24-hour lateral view (Fig. 1(c)) clearly showed the narrowed aganglionic zone and this diagnosis was confirmed at surgery.

The pathognomonic narrowed area was not seen clearly until the evenly mixed, retained barium was visualized in the lateral view.

Irregular Contractions

A 4-week-old female child was examined following a history of abdominal distension and vomiting with alternating constipation and diarrhoea. At fluoroscopy a narrowed rectum and sigmoid colon were noted, and barium



Above: Figs. 1(a) and 1(b)
Below: Fig. 1(c)

Figs. 1(c) and 1(b). Barium enema. The aganglionic segment is not obvious in the anteroposterior view; in the lateral view the narrow segment is dilated by retained faeces. Fig. 1(c). A 24-hour lateral film shows the mixed retained barium in the clearly delineated narrow aganglionic segment.

*Date received: 14 October 1970.

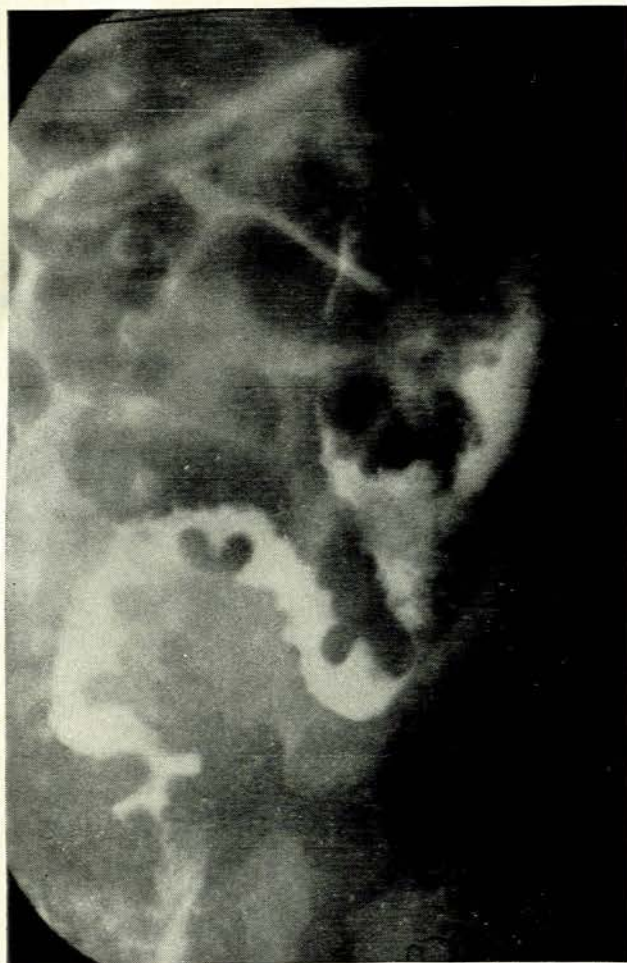


Fig. 2. Saw-tooth irregularity of the retained barium in the aganglionic segment.

introduced as an enema did not penetrate further than the transition zone.

A 12-hour film showed the retained barium uniformly mixed and static in the irregularly contracted segment (Fig. 2).

This striking saw-tooth irregularity was noted as a diagnostic sign by Hope *et al.* in 1965.⁵ The appearance was attributed to bizarre contractions from a dysrhythmia in the aganglionic segment. At surgery it is not uncommon to note that the aganglionic segment appears comparatively narrow.⁶

In the next case the actual writhings were noted in the narrowed segment. A male child aged 3 years was examined for suspected Hirschsprung's disease. At fluoroscopy a narrowed rectosigmoid colon was noted. The 24-hour film showed slight irregularity of contour but on repeat fluoroscopy a purposeless snake-like writhing in the sigmoid and rectum was noted. The writhings in these areas occurred independently of each other and there were no peristalses. The dilation and contraction of rectum were recorded on a 70-mm camera study taken at one frame/second (Fig. 3).

This appears to be the first photographic record of these movements. This method of examination is not suggested as a routine, but may be of help in doubtful cases. The movements are best seen in the delayed films.⁵

Total Colonic Aganglionosis

A 3-week-old infant with possible Hirschsprung's disease was admitted from an outside hospital. A barium enema had been performed 5 days previously, with an inconclusive result. Abdominal tract film taken on admission (Fig. 4) showed fluid levels in the small bowel and a complete retention of barium in the colon. It was noted that the colon had an over-all shortened appearance.⁷ Long segment Hirschsprung's disease involving the whole colon was confirmed at surgery.

The lack of the normal redundant loop of sigmoid

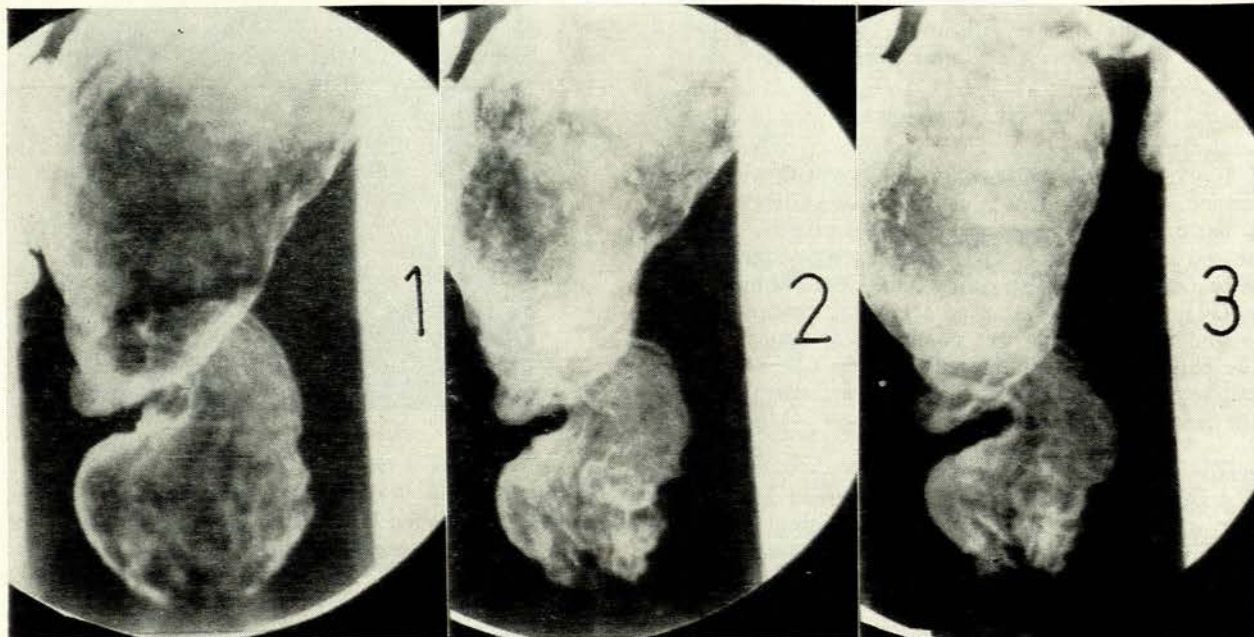


Fig. 3. A 70-mm camera study at one frame/second (5-in field) showing purposeless contraction and dilation of the rectum.

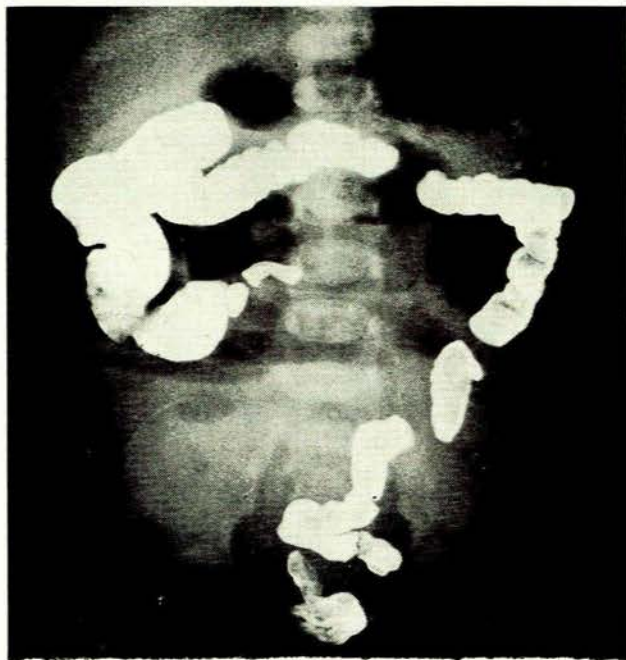


Fig. 4. Total retention of barium 5 days after obstructed small bowel loops are seen and the colon is foreshortened in length. In particular the normal redundant sigmoid loop is absent.

colon has been noted by us as a feature in the over-all shortened appearance which may occur with colonic aganglionosis.

These cases are particularly liable to have wash-outs after the barium enema so that it may be difficult to obtain a delayed film of value. Two out of 7 cases of colonic aganglionosis described by French⁸ had complete evacuation in 24 hours following contrast enema. However, it was not stated if barium was used or wash-outs withheld in these cases.

SUMMARY

The delayed lateral film after barium enema proved to be the most useful film in a series of 64 cases of Hirschsprung's disease, of which 30 cases were neonates. The spastic state of the aganglionic colon was noted and writhing snake-like movements have been recorded.

REFERENCES

1. McDonald, R. G. and Evans, W. A. (1954): *Amer. J. Dis. Child.*, **87**, 575.
2. Berdon, W. E. and Baker, D. H. (1965): *Amer. J. Roentgenol.*, **93**, 432.
3. Hiller, H. G. and McDonald, P. (1969): *Progress in Pediatric Radiology*, vol. 2. Basle: Karger.
4. Lilly, G. (1970): Paper read at the 7th Meeting of the European Society of Paediatric Radiologists, Rome.
5. Hope, J. W., Borns, P. F. and Berg, P. K. (1965): *Amer. J. Roentgenol.*, **95**, 217.
6. Cywes, S. (1970): Personal communication.
7. Berdon, W. E., Koontz, P. and Baker, D. H. (1964): *Amer. J. Roentgenol.*, **91**, 680.
8. French, R. S. (1968): *Radiology*, **90**, 249.