

MITRAL VALVE PROSTHESIS AND PREGNANCY WITHOUT ANTICOAGULATION THERAPY*

PIETER M. BARNARD, M.B., CH.B., F.A.C.S., M.D. AND J. J. HEYDENRYCH, M.B., CH.B., M.Sc., M.MED. (CHIR.), *Department of Cardiothoracic Surgery, Karl Bremer Hospital and the University of Stellenbosch*, AND B. G. LOMBAARD, M.B., CH.B., B.Sc., *General Practitioner, Barkly East, CP*

Patients with mitral valve prostheses are usually advised against becoming pregnant. These patients are usually maintained on long-term anticoagulation therapy which, should pregnancy occur, may pose difficult problems for the patient, the foetus and the physician.

VillaSanta¹ and Beller² outlined the dangers to the pregnant patient who is maintained on anticoagulant therapy. Bennett and Oakley³ reported the death after caesarean section of the mother in whom a Hammersmith-Alvarez mitral prosthesis had been inserted before pregnancy, and advised sterilization in such instances.

We report here a successful pregnancy with delivery of a normal child in a primigravida, with a University of Stellenbosch mitral valve prosthesis, in whom anticoagulation therapy was not used.

We believe that in selected cases where the pregnancy is highly desirable these patients should be granted the opportunity to continue with the pregnancy in the light of the improved results now being obtained with the newer design of prosthetic heart valves.

CASE REPORT

The patient was a 17-year-old Bantu woman who had had rheumatic fever at the age of 14 years. At the age of 16 years she developed severe heart failure and pulmonary oedema due to mitral incompetence that was confirmed by cardiac catheterization studies. These studies also showed the presence of minimal aortic incompetence.

She initially responded well to medical therapy but 12 months later deteriorated and was thought to have subacute bacterial endocarditis. Although repeated blood cultures were negative, the sedimentation rate remained elevated, and she was treated for bacterial endocarditis. Congestive heart failure persisted and her mitral valve

was replaced with a 20-mm. University of Stellenbosch mitral valve prosthesis (Fig. 1), at Karl Bremer Hospital on 6 December 1967.

She made a remarkable recovery and was discharged 4 weeks after the operation. Anticoagulation with warfarin sodium had been started on the third postoperative day, and it was decided to continue the oral anticoagulation for a period of 3 months. Her medications at the time of discharge included digitoxin, 0.1 mg. *b.d.*, and warfarin sodium, 2.5 mg. daily.

However, she discontinued all medications of her own accord one month after discharge and failed to report to her local physician at Barkly East. She was married within a year after her operation and first consulted her physician at 24 weeks' gestation. The pregnancy was normal in all respects, without any signs of cardiac failure, and it was decided not to use anticoagulation therapy at that stage. Urinalysis revealed the presence of a urinary tract infection which responded well to antibiotic therapy.

The progress of the pregnancy was uncomplicated, and she was hospitalized at the Cloete-Joubert Hospital in Barkly East on 25 May 1969. On 26 May she was delivered of a normal 7-lb. baby at term without any complications. She breast fed the child, and they were discharged on the fifth day after delivery. Mother and child continue to do well more than 3 months after delivery.

DISCUSSION

This is the seventh report of pregnancy in a patient who had undergone prosthetic mitral valve replacement before pregnancy. Although the first report by Johnson *et al.*⁴ was encouraging, DiSaia⁵ and Kerber *et al.*⁶ reported congenital malformation of the infants in the form of saddle-nose deformity, bilateral optic atrophy and mental retardation that was attributed to the use of warfarin sodium during pregnancy. Bennett and Oakley³ reported multiple

*Date received: 9 September 1969.

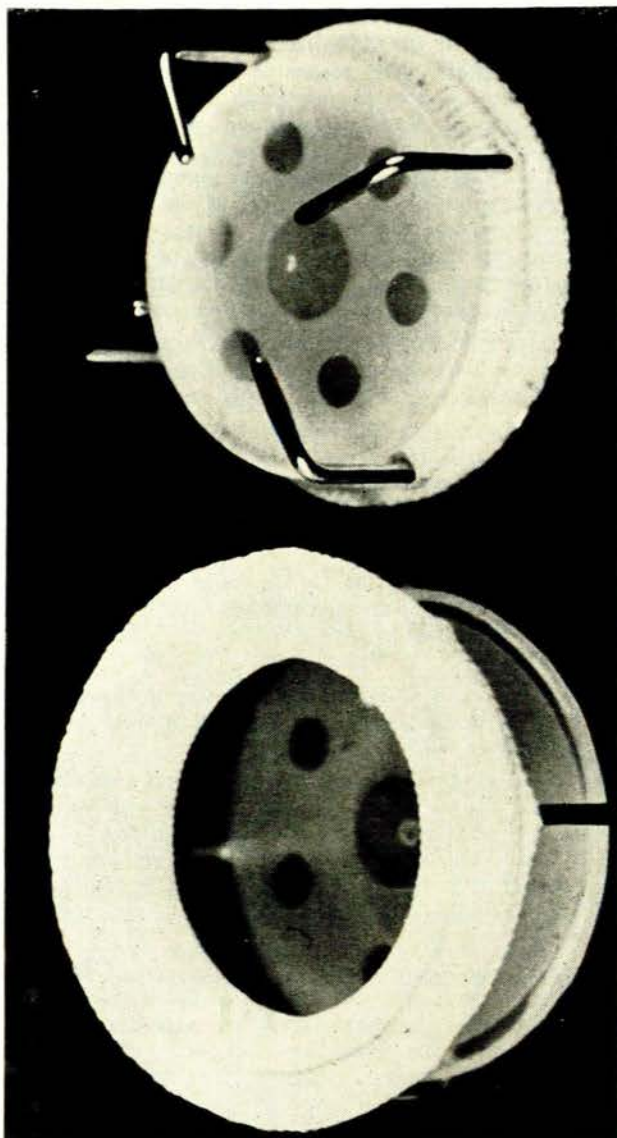


Fig. 1. The University of Stellenbosch cloth-covered, disc mitral valve prosthesis.

systemic emboli and the death of the mother in the postpartum period due to thrombus formation on the prosthesis.

These reports gave cause for concern and resulted in a policy of advising patients with prosthetic mitral valves to avoid pregnancy or to undergo sterilization.³

More recently Bloomfield and Rubinstein⁷ reported a successful pregnancy and delivery of a normal infant in a patient with a Starr-Edwards mitral valve prosthesis. The patient took warfarin sodium for 36 weeks and was given heparin parenterally for 18 days before delivery. They believe successful pregnancy and delivery in patients with mitral valve prostheses is possible when careful control of anticoagulation is maintained.

Finnerty and MacKay⁸ and Aaro *et al.*⁹ also reported that, when properly used, oral anticoagulation therapy was both safe and effective during pregnancy.

The use of anticoagulation during pregnancy can nevertheless be potentially hazardous, as oral anticoagulants cross the placental barrier with depression of the prothrombin content of the foetal blood.¹⁰ Besides malformation of the foetus, fatal haemorrhage of the hypothyroid foetus or newborn occurred when the limits of the therapeutic range were exceeded or when the oral anticoagulant was not discontinued long enough before labour.^{7,11}

VillaSanta¹ reviewed 92 cases of pregnant patients reported in the literature, who were treated with oral anticoagulants alone or in conjunction with heparin. In these patients, there were 14 stillborn infants and 3 neonatal deaths, representing a perinatal mortality of 18.4% or almost 1 in 5 cases. Furthermore, there were 2 other infants with congenital anomalies related to defect of coagulation, who lived, but with residua.

Ideally, pregnant patients with prosthetic valves should not receive anticoagulant therapy. This, however, should be weighed against the potential danger of systemic embolism or thrombotic obstruction of the prosthetic valve.

The use of the newer types of prosthetic mitral valves, with cloth covering and subsequent tissue ingrowth into the prosthesis,¹²⁻¹⁴ has markedly lowered the incidence of thrombo-embolism. Following our previously reported experimental studies in subhuman primates and initial clinical experience,¹⁵ we now use warfarin sodium only during the first 3-6 postoperative months. We have detected no late systemic emboli or cases of thrombosis with the University of Stellenbosch mitral valve prosthesis for periods of 3 months to 2 years after valve insertion where anticoagulant therapy has been discontinued. We therefore feel justified to continue this policy also during pregnancy, so as to avoid the potential hazards of oral or parenteral anticoagulation therapy.

SUMMARY

An uncomplicated pregnancy is reported in a 17-year-old female with a University of Stellenbosch mitral valve prosthesis following rheumatic heart disease and subacute bacterial endocarditis. The patient received no anticoagulant therapy during pregnancy and delivered a normal, healthy 7-lb. baby. Successful pregnancy and delivery in patients with a University of Stellenbosch mitral valve prosthesis is possible without the use of anticoagulation. This is believed to be the first reported case of a normal pregnancy and delivery of a normal infant following mitral valve replacement and discontinuation of anticoagulation therapy.

REFERENCES

- VillaSanta, U. (1965): *Amer. J. Obstet. Gynec.*, **93**, 142.
- Beller, F. K. (1968): *Clin. Obstet. Gynec.*, **11**, 290.
- Bennett, G. G. and Oakley, C. M. (1968): *Lancet*, **1**, 616.
- Johnson, A. S., Meyers, M. P., Eckhouse, A. S., Bacher, B. and Limia, A. (1966): *Mich. Med.*, **65**, 718.
- DiSaia, P. J. (1966): *Obstet. and Gynec.*, **28**, 469.
- Kerber, I. J., Warr, O. S. and Richardson, C. (1968): *J. Amer. Med. Assoc.*, **203**, 223.
- Bloomfield, D. K. and Rubinstein, L. I. (1969): *Lancet*, **2**, 290.
- Finnerty, J. J. and MacKay, B. R. (1962): *Obstet. and Gynec.*, **19**, 405.
- Aaro, L. A., Johnson, T. R. and Juergens, J. L. (1967): *Amer. J. Obstet. Gynec.*, **97**, 514.
- Quick, A. J. (1946): *J. Biol. Chem.*, **164**, 371.
- Gordon, R. R. and Dean, T. (1955): *Brit. Med. J.*, **2**, 719.
- Davila, J. C., Amongero, F., Sethi, R. S., Rincon, N. L., Palmer, T. E. and Lautsch, E. V. (1966): *Ann. Thorac. Surg.*, **2**, 714.
- Braunwald, N. S. and Bonchek, L. I. (1967): *J. Thorac. Cardiovasc. Surg.*, **54**, 630.
- Barnard, P. M. and Heydenrych, J. J. (1969): *Thorax*, **24**, 18.