

# FUNCTIONAL LEVELS OF AMPUTATION OF FINGERS\*

ISIDORE KAPLAN, F.R.C.S., F.R.C.S. (EDIN.), *Plastic Surgeon, Johannesburg*

Amputation of an entire finger or part of it, a commonly performed operation, is often regarded as a minor surgical procedure and usually delegated to the most inexperienced to perform. However, the decision to salvage or ablate may require considerable thought and judgement, the level of amputation of the affected digit requires understanding of the dynamic function of the hand, and the technique may demand advanced surgical skill. Not only may the patient lose a digit unnecessarily, but incorrectly performed amputation may result in a galaxy of complications, rendering the amputated finger functionless and impairing the over-all function of the hand.

It is of paramount importance to realize that the anatomical level of amputation does not necessarily correspond to the functional level. The surgeon proposing amputation must appreciate the full function of the hand as a working unit, and accept responsibility for maintaining as much function as possible or improving function if necessary.

## SURGICAL PRINCIPLES OF AMPUTATION IN INITIAL INJURY

In a digit which has sustained traumatic amputation, it is the duty of the surgeon to salvage all viable tissues. Dogmatism cannot be the rule, for each case must be tailored to the individual needs of the patient. The dominance of the hand, the level of amputation, the occupation and age of the patient, and the particular digit which has sustained the injury must all be considered. Nevertheless, well-established criteria do exist in the technique of amputation.

### *Skin*

At the time of injury, all viable skin is conserved, and all available flaps—volar, dorsal or lateral—must be utilized to cover the stump. Length may not be sacrificed merely because there is insufficient skin, though a bulky stump

with excess skin coverage is preferable to a stump tensely enclosed.

### *Tendon Ends*

Suturing the tendon ends over the stump adds nothing to the amputation stump. The profundus tendons of all fingers are interrelated and hence such suturing may result in checkreining of the other profundus tendons, with diminished functional excursion. Tendon ends should be cut short and allowed to retract.

### *Nerve Ends*

Neurovascular bundles should be carefully isolated, and the nerve ends should be dissected from the accompanying artery, resected and allowed to retract proximally, leaving the end neuroma to be placed away from the stump scar.

### *Bone Ends*

The bone ends should be trimmed and shaped to achieve a smoothly-contoured, cosmetically acceptable tip. Preservation of the phalangeal heads creates bulbous tips which, apart from being cosmetically unattractive, are functionally inefficient.

## AMPUTATION OF INDIVIDUAL FINGERS

### *Index Finger*

The index finger is the most important of all the fingers. It participates not only in grasping, but also in pinching function, with accurate pad-to-pad opposition of the thumb. It is considered to represent 20% of the function of the hand, and maintenance of length is of great importance. It is the only finger where the application of a cross-finger or palmar flap may be justified to maintain length. The critical level of amputation is the proximal interphalangeal joint. At, or proximal to, this level pinch function is lost, the thumb utilizing the middle finger as its oppositional member.

Though the amputation stump at the proximal phalangeal level will still contribute to gross grasp, this short

\*Date received: 24 January 1969.



stump acts as an impediment to function between the thumb and the middle finger, being held in the hyper-extended position (Fig. 1).

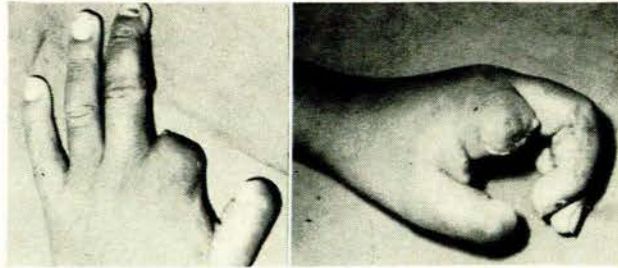


Fig. 1(a)

Fig. 1(b)

Fig. 1. Amputation of index finger at proximal phalangeal level, besides producing an unsightly stump (a), impedes thumb-middle finger oppositional function (b).

If an improvement in pinch function is to be obtained, and provided there are no other associated injuries or amputations to the other fingers, amputation of the index finger at the metacarpal base, with transfer of the first dorsal interosseus muscle to the lateral band of the middle finger, may provide the middle finger with increased abduction in its increased oppositional functional role relating to the thumb. Though this procedure will narrow the span of the hand, it will create a smooth, widened web space, allowing the thumb to move freely against its new opposing digit, the middle finger (Fig. 2).

*Middle Finger*

The middle finger is considered to contribute 20% of the function of the hand because of its strong grasp and pinch-hook action. This finger may substitute completely for the index finger. The middle and ring fingers constitute the central rays or digits of the hand and are responsible for maintaining the 'cup' effect of the hand.

As an isolated injury, amputation of the middle finger does not constitute as severe a disability as that of the index finger. At the time of injury, traumatic amputation can be treated by removal of sufficient bone to obtain sufficient skin for closure. Every effort should be made, however, to preserve the proximal phalanx of the middle finger in order to preserve the 'cup' effect of the hand (Fig. 3). If the amputation has proceeded to the metacarpophalangeal joint region, a gap is created through which small objects will escape, while the adjacent index and ring finger may deviate towards each other, producing a 'scissoring' effect.

In patients in whom preservation of the 'cup' effect of the hand is important, transfer of the adjacent index finger (metacarpal transfer) should be carried out. In this procedure, the index finger, together with its functioning muscles and metacarpal, is transferred to the middle finger position. Though the hand is narrowed, restoration of the palmar 'cup' effect is achieved by eliminating the gap, improving function, adding dexterity and producing a cos-

metically more acceptable hand (Fig. 4).

Narrowing of the palm may make the hand less effective for gross grasp. The importance of tailoring the amputation and reconstruction of the hand to the

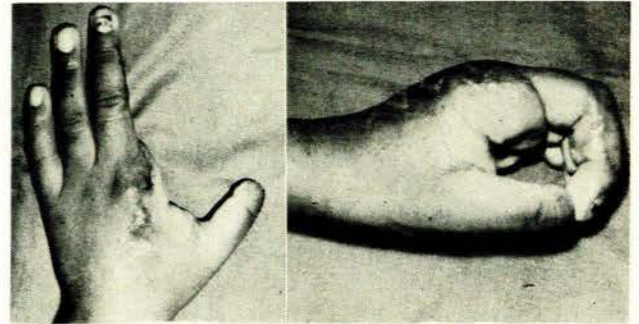


Fig. 2(a)

Fig. 2(b)

Fig. 2. Revision of amputation of index finger at metacarpal base level creates smooth widened web space (a) and allows unimpeded thumb-middle finger opposition, the middle finger substituting for the index finger (b).

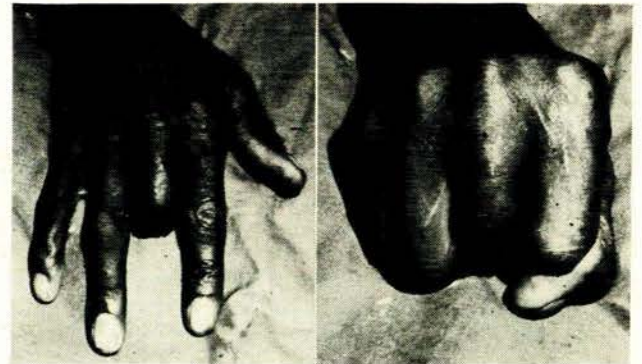


Fig. 3(a)

Fig. 3(b)

Fig. 3(a) and 3(b). Importance of preservation of proximal phalanx in middle finger amputations. The palmar 'cup' effect of the hand is maintained, preventing small objects from escaping and preventing scissoring of the adjacent fingers.

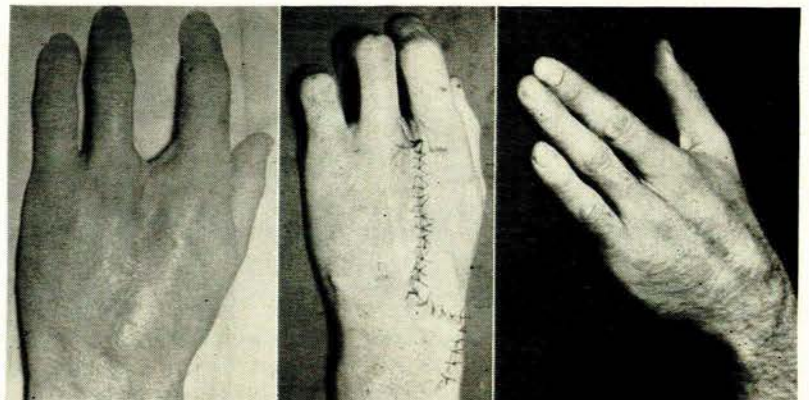


Fig. 4(a)

Fig. 4(b)

Fig. 4(c)

Fig. 4(a). Amputation of middle finger at MP joint level creates central gap in the hand and small objects cannot be held in the hand, while adjacent fingers may deviate. 4(b) and 4(c). Index finger transfer to amputated middle finger position eliminates the central gap, restores palmar 'cupping' effect, prevents adjacent fingers scissoring and produces a more cosmetically acceptable hand.



patient's individual needs is the only indication for carrying out this procedure.

#### Ring Finger

The ring finger is considered to contribute 10% of the function of the hand and, together with the middle finger, constitutes the central digits responsible for the 'cup' effect of the hand.

As in the case of the middle finger, this finger may be shortened at the time of the traumatic amputation in order to obtain adequate closure. It is also essential to attempt preservation of the proximal phalanx of the finger in order to maintain the 'cup' effect of the hand. Loss of the ring finger at, or proximal to, the metacarpal level will create a gap in the hand and possibly result in deviation of the adjacent middle and little fingers towards each other and inability to prevent objects from falling through the gap. The hand, as such, may be clumsy and inefficient.

Here, again, it may be necessary to carry out a metacarpal transfer. In this case, the little finger is transferred to the ring finger position. The transfer, as in the case of the middle finger, will obviate the gap in the hand, preserving the palmar 'cupping' function, and may well result in a more dextrously functioning hand with an improved cosmetic result (Fig. 5). It is not suggested that metacarpal transfer is indicated in every case in which proximal phalanges of the central digits—the middle and ring fingers—have been lost. The importance is the realization that in patients sustaining this injury the metacarpal transfer may well result in improvement in function and appearance.

#### Little Finger

The little finger is considered the least important digit functionally, contributing about 10% of the function of the hand. It adds width and strength of grasp. However, if multiple injuries have occurred, the little finger becomes increasingly important because of its polar position in the hand.

As in the case of the index finger, if isolated amputa-

tion has proceeded to the proximal phalangeal level, the hand may well be more dextrous and cosmetically acceptable with amputation at the metacarpal base (Fig. 6).

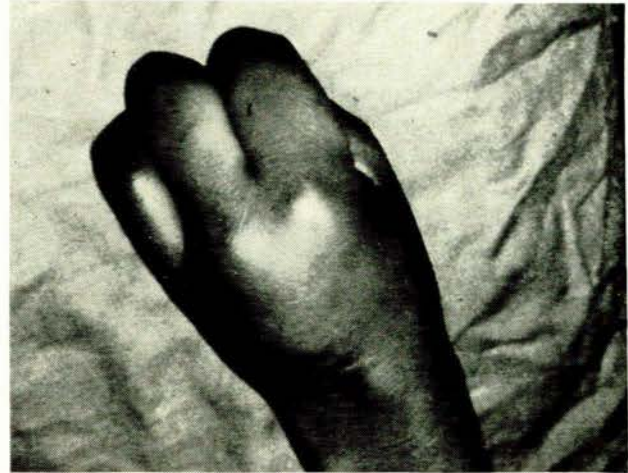

Fig. 5. Metacarpal transfer of little finger to amputated ring finger position, eliminating central gap.

#### SUMMARY

Dogmatic principles cannot be laid down for the functional levels of amputations of solitary digits. Certain well-established criteria do, however, exist to guide the surgeon in giving the patient the best possible function following amputation.

At the time of injury, attention to conservation of all available tissue, resecting the tendons and nerve ends and also shaping bone will contribute largely to avoidance of unnecessary complications. Anatomical sites of amputation may not correspond to functional levels, and, depending on the individual needs of the patient, improvement in the function and the appearance of the hand can be achieved by appropriate functional levels of amputation.

In amputation of the central digits—the middle and ring fingers—if indicated, the procedure of metacarpal transfer may provide the patient with functional and cosmetic advantages of a symmetrical 3-fingered hand, outweighing the frequently over-emphasized loss of the small amount of power from narrowing the transverse metacarpal arch.

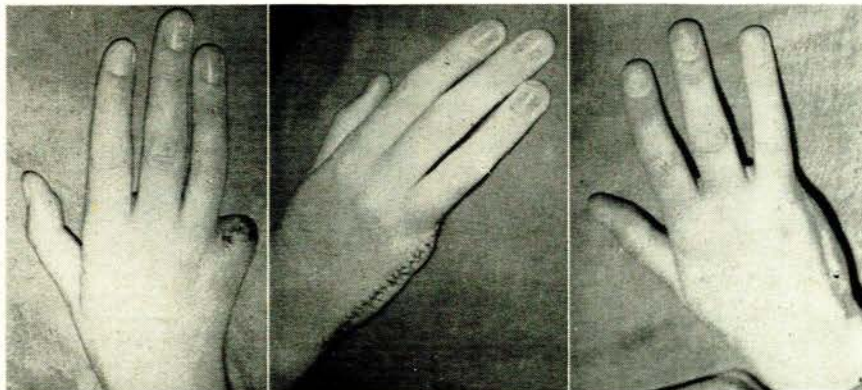


Fig. 6(a)

Fig. 6(b)

Fig. 6(c)

Fig. 6(a). Amputation of little finger at proximal phalangeal level results in an unattractive stump and often adds little to function. 6(b) and 6(c). Revision amputation of little finger at metacarpal base results in a symmetrical, dextrous, 3-fingered hand, outweighing the often over-emphasized loss of a small amount of power from narrowing of transverse metacarpal arch.