

GASTROSCOPY: TWENTY-MONTH CLINICAL EXPERIENCE WITH A NEW FIBRE-OPTIC GASTROSCOPE WITH GASTROCAMERA*

H. KAVIN, M.B., CH.B., DIP. MED. (RAND), J. T. VAN SCHOOR, M.B., CH.B. (RAND) AND S. R. LYNCH, M.B., CH.B. (RAND), F.C.P. (S.A.), *Gastro-enterology Clinic, Johannesburg Hospital and Department of Medicine, University of the Witwatersrand, Johannesburg*

Rapid advances have been made in the technique of gastroscopy and gastrophotography since the introduction of instruments based on the principle of fibre-optics a decade ago.^{1,2} Colcher³ has recently reviewed the available equipment. It is the purpose of this paper to report the experience obtained during the use of a fibre-optic gastroscope with an incorporated intragastric camera (Olympus Model GTF-A) in 295 gastroscopic examinations.

MATERIALS AND METHOD

The Gastroscope (Fig. 1)

The gastroscope is 88 cm. long. The proximal portion comprises an eyepiece together with remote controls for manipulating the position of the end of the gastroscope, advancing the photographic film in the camera and controlling the lighting both for viewing and for photography. This is connected to a flexible tube 10.2 mm. in diameter which contains the fibreglass bundles used to transmit the image. The flexible portion of the gastroscope is continuous with a terminal rigid tube which is 5.6 cm. long and 12.7 mm. in diameter. The distal rigid tube contains a fixed-focus observation lens system with a field of vision of 55°, a camera with an 80° field of vision and two lighting systems, one for viewing and one for photography. The terminal 10 cm. of the gastroscope can be flexed through 70° upwards and 50° in a downward direction by a remote-control device. Kodak High-Speed Ektachrome colour reversal film of 4-mm. width was used for gastric photography and gave satisfactory results.

Clinical Material

The gastroscopic examinations were performed as part of the routine service offered by the Gastro-enterology Clinic of Johannesburg Hospital. Although the majority of the subjects were inpatients referred from the medical and surgical wards, 17% were outpatients. The patients can be subdivided into 5 main groups, depending upon the indication for gastroscopy (Table I). The X-ray-positive

other patients a definite radiological diagnosis had been made but the clinician had one or other reason for referring the patient for gastroscopic evaluation in addition. Patients in the X-ray-negative group complained of

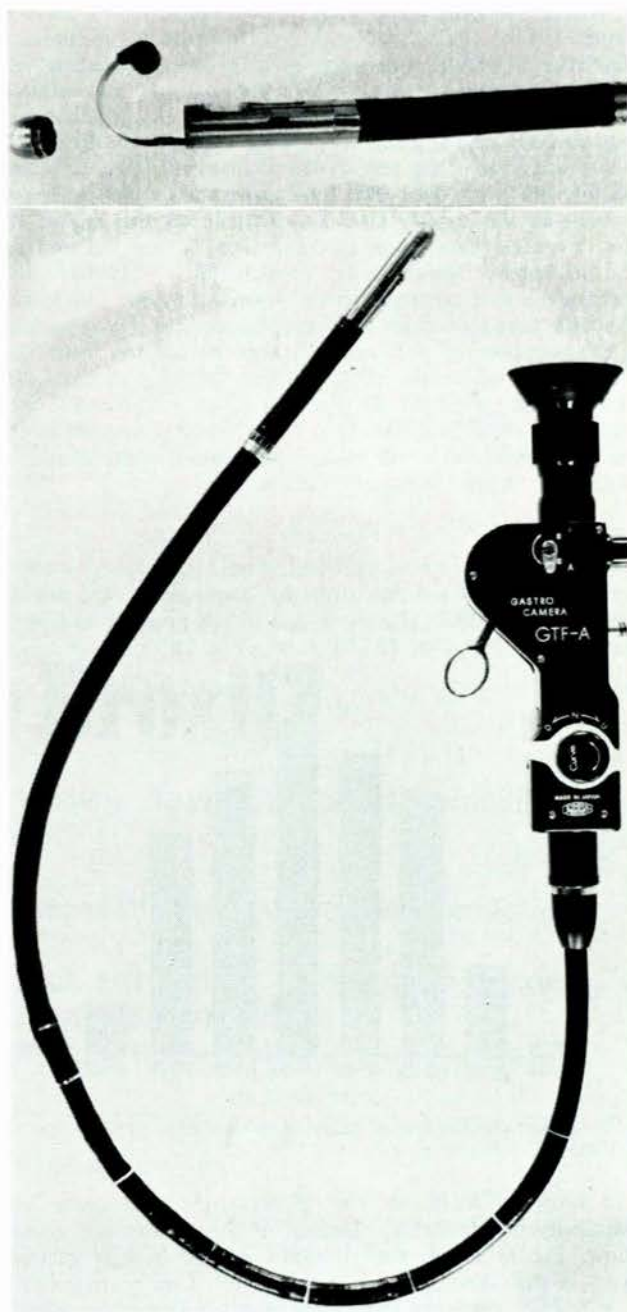


Fig. 1. The Olympus GTF-A fibre-optic gastroscope with intragastric camera.

TABLE I. INDICATIONS FOR GASTROSCOPY

Indication	No. of patients
X-ray-positive group	92
X-ray-negative dyspepsia	35
Postoperative stomach	57
Upper gastro-intestinal bleeding	54
Miscellaneous	6
Total	244

group includes those patients in whom radiological studies were inconclusive. For example, gastroscopy was performed when a doubtful niche or an inconstant area of rigidity of the stomach wall was noted radiologically. In

*This paper was presented in part at the 1st South African Radiological Congress, Johannesburg, September 1968.

symptoms suggestive of upper gastro-intestinal pathology, but the stomach was normal on barium-meal examination. Common indications for gastroscopy in this series were the investigation of upper gastro-intestinal bleeding and the recurrence of symptoms after surgery on the stomach. Finally, there was a small group of patients who were gastroscopied for various other reasons: 2 had hereditary telangiectasia, and in 4 patients with long-standing pernicious anaemia gastroscopy was performed in a search for early gastric carcinoma.

Techniques of Gastroscopy

Where possible the patient was fasted for at least 8 hours before the examination. A dose of 5-20 mg. of diazepam (Valium) was given by intravenous injection immediately preceding gastroscopy. The pharynx was sprayed with 0.5-1.0 ml. of 2% Xylocaine. The viewing and lighting windows of the gastroscope were coated with dimethyl-polysiloxane and the rest of the instrument with a water-soluble lubricant jelly. The fibroscope was passed with the patient in the supine position. Passage to the region of the cricopharyngeus was facilitated by flexing the end of the instrument downwards through 70°. Thereafter the instrument was returned to its normal contour and carefully advanced through the oesophagus into the stomach.

Examination of the stomach was performed with the patient supine, in the left and right lateral positions and in the sitting position. In each position an extensive examination of all visible areas was made by manipulating the position of the whole instrument and by controlling the deflection of the terminal portion.

RESULTS

Two hundred and ninety-five endoscopic examinations were performed in 244 patients over the 20-month period beginning 1 March 1967. The mean age of the patients was 50.5 years with a range of 19-91 years (Fig. 2).

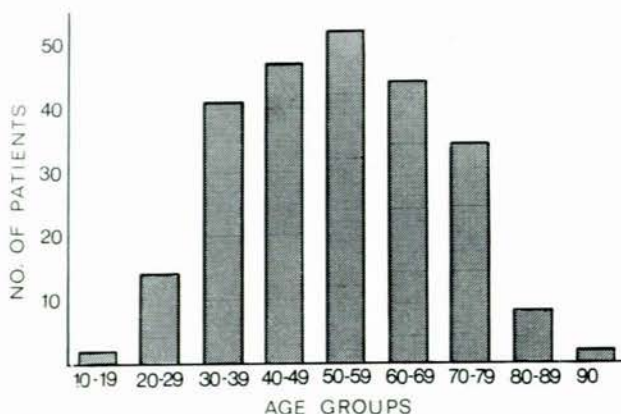


Fig. 2. Age distribution of patients submitted to gastroscopy (years).

In only 10 instances was gastroscopy inadequate or technically unsatisfactory. Details of these cases are given below. Fig. 3 shows the situation of the benign gastric ulcers, gastric carcinomas and polypi noted on gastroscopy. It is readily apparent that there was no consistent blind area.

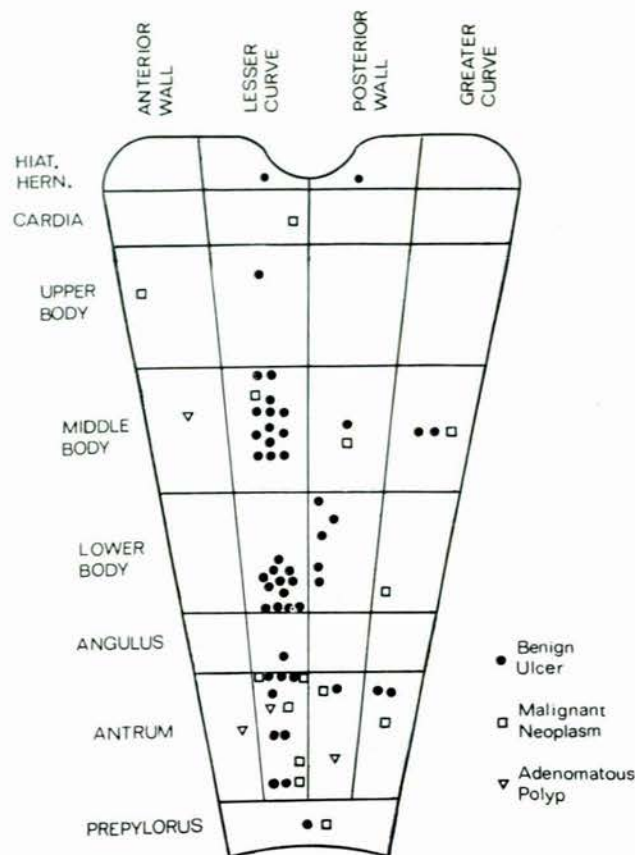


Fig. 3. Site of benign gastric ulcers, malignant neoplasms and polypi noted gastroscopically.

In order to assess the value of the procedure in our hands, every patient was closely followed up after gastroscopy, if possible until the present time. The final diagnosis was based on an evaluation of all the available information. In various subjects it was reached by laparotomy, biopsy, necropsy examination or prolonged clinical observation.

X-ray-Positive Group (Table II)

Ninety-two patients were referred for gastroscopy because of inconclusive findings on barium-meal examination or because despite a positive X-ray the diagnosis remained uncertain on clinical grounds. In 21 patients, 10 of whom had doubtful radiological evidence of gastric pathology, the mucosa of the stomach was normal. Gastric pathology was present in 71 patients. Fifty-nine had benign gastric ulcers. Of the patients with benign gastric ulcers, 13 had radiological features suggesting malignancy and 3 were thought to be unequivocally carcinomatous on X-ray. In all these subjects gastroscopy revealed the true nature of the lesion. However, an incorrect endoscopic diagnosis was made in 4 patients with benign gastric ulcers. Two were considered malignant and one, a distal antral lesion, was not seen. In 1 patient gastroscopy was unsatisfactory because of the presence of an hour-glass stomach. Many of the patients with benign gastric ulcers

TABLE II. X-RAY-POSITIVE GROUP

Final diagnosis	No. of patients	Method of diagnosis		
		X-ray only	Gastroscopy only	X-ray and gastroscopy
Benign gastric ulcer	59	4	4	51
Carcinoma	12	0	2	10
Normal gastric mucosa:				
(a) Inconclusive X-ray	10	0	10	0
(b) Duodenal ulcer	8	8	0	0
(c) Hiatus hernia	3	3	0	0

were submitted to gastroscopy several times in order to document that complete healing of the lesion had occurred. Twelve patients had a carcinoma of the stomach. Of these, 2 had apparently benign lesions on barium-meal examination. A correct gastroscopic diagnosis was made in each patient.

X-ray-Negative Dyspepsia

There were 35 patients with upper gastro-intestinal symptoms and negative barium studies. In 8 cases the cause of the symptoms was established gastroscopically: 2 had healing, benign, lesser-curve antral ulcers, 1 had a benign ulcer on the lesser curve at the angulus, 1 had a benign prepyloric ulcer, 1 had a benign ulcer in a sliding hiatal hernia sac and 1 a small carcinoma on the posterior wall of the body of the stomach. This last patient had an atrophic gastric mucosa and suffered from pernicious anaemia. In 2 other patients a cause for their symptoms was suggested by gastroscopy. One had severe gastritis, probably due to the ingestion of large amounts of aspirin. In the other patient the fibrescope could not be advanced further than 37 cm. from the incisor teeth. A tentative diagnosis of oesophageal stricture was confirmed later by oesophagoscopy. Incidental gastric pathology was noted in a further 4 patients in this group. Three had gastric atrophy and 1 had a 3-4-mm. benign adenomatous polyp of the antrum.

There were 27 patients in this group with upper gastro-intestinal symptomatology, but in whom both the barium-meal examination and gastroscopy were negative. These patients have been followed up for a period of 2-20 months. No case has so far been shown to have gastric pathology which might have been missed at the time of the initial investigation.

The Postoperative Stomach (Tables III and IV)

Fifty-seven patients with symptoms of upper gastro-intestinal disease following gastric surgery were investigated by radiology and gastroscopy. The type of surgical procedure performed and the method by which a final diagnosis was established are listed in Table III. The efferent loop was entered or adequately visualized for several centimetres in all patients with a Polya gastrectomy. However, gastroscopy was technically unsatisfactory in 4 patients who had undergone vagotomy and gastro-enterostomy. In 2 of these patients the stoma was poorly visualized and could not be entered; 1 patient was unable to retain enough air in the stomach for adequate visualization, and in 1 patient with stomal obstruction the large gastric residue precluded adequate examination. The anastomotic site was well visualized in all subjects with

a Billroth I procedure. However, the instrument could not be introduced into the duodenum in any of these patients. A similar experience was noted in patients after vagotomy and pyloroplasty. In a patient who developed an hour-glass stricture of the stomach 4 years after suture of a perforated benign lesser-curve ulcer, gastroscopy was technically inadequate due to failure to visualize the distal segment of the stomach.

TABLE III. GASTROSCOPY IN THE POSTOPERATIVE STOMACH

Operation	No.	Method of diagnosis	
		X-ray and gastroscopy	Gastroscopy only
Polya gastrectomy	27	3	8
Billroth I gastrectomy	7	4	1
Vagotomy and gastro-enterostomy	9	2	2
Vagotomy and pyloroplasty	4	0	1
Hiatus hernia repair	6	1	1
Suture of perforated gastric ulcer	4	2	1
Total	57	12	14

TABLE IV. LESION AND MODE OF DIAGNOSIS IN THE POSTOPERATIVE STOMACH

Final diagnosis	No.	Method of diagnosis	
		X-ray and gastroscopy	Gastroscopy only
Stomal ulceration	16	8	8
Stomatitis	2	0	2
Gastric ulcer	4	2	2
Gastritis	1	0	1
Recurrent carcinoma	2	2	0
Pseudodiverticulum	1	0	1
Total	26	12	14

In 26 of the 57 patients gastric pathology was present. Table IV summarizes the nature of the lesions and the method by which the diagnosis was reached. In over half of them the diagnosis was made only at gastroscopy. Of those with pathological lesions, 16 had anastomotic ulcers. In 8 of these patients interpretations of the barium-meal examination was made impossible by the presence of considerable postoperative distortion. In 2 instances loose silk sutures were identified in the vicinity of the stomal ulcers. There were 4 patients who showed no abnormality on barium-meal examination. Gastroscopy revealed the presence of severe stomatitis in 2 of these patients, while each of the others had benign gastric ulcers. Radiological diagnoses of benign gastric ulcers in 2 cases and gastric carcinoma in 2 were confirmed at gastroscopy. Finally, in a patient investigated 18 months after simple suture of a perforated lesser-curve ulcer, the barium meal revealed a large outpouching at the site of previous surgery 2 cm. above the incisura. Gastroscopically, this was shown to be a pseudodiverticulum.

Haematemesis and Melaena (Table V)

Fifty-four patients were referred for gastroscopy because of bleeding from the gastro-intestinal tract. Division of the material into 2 groups, depending on whether they were

investigated within 7 days or later than 1 week following the upper gastro-intestinal bleed, proved useful in the assessment of results.

TABLE V. HAEMATEMESIS AND MELAEANA: LESIONS AND METHOD OF DIAGNOSIS ACCORDING TO TIME OF INVESTIGATION

Time	Final diagnosis	No.	Method of diagnosis	
			X-ray and gastroscopy only	Gastroscopy only
Within 7 days	Acute gastric mucosal lesions:			
	Salicylate gastritis	4	0	4
	Alcoholic gastritis	1	0	1
	Stress ulcer	1	0	1
	Mallory-Weiss lesion	1	0	1
	Stomal ulcer	2	1	1
	Chronic gastric ulcer	4	2	2
	Antral carcinoma	1	1	0
	Duodenal ulcer	2	0	0
	Undiagnosed	13	0	0
	Total	29*	4	10
After 7 days	Acute gastric mucosal lesions:			
	Salicylate gastritis	1	0	1
	Stomal ulcer	4	2	2
	Oesophageal varices	1	0	0
	Chronic gastric ulcer	5	5	0
	Duodenal ulcer	2	0	0
	Undiagnosed	12	0	0
	Total	25	7	3

*4 patients regarded as too ill for X-ray.

In 29 patients gastroscopic and barium-meal examinations were performed within 7 days of presentation. The cause of the bleed was identified in 16 of the 29 patients—10 by gastroscopy alone and in 2 by X-ray alone. In the remaining 4 patients the diagnosis was made radiologically and confirmed on gastroscopy. Further analysis of the 10 cases diagnosed only on endoscopy reveals that 7 patients suffered acute gastric mucosal lesions. These included 5 with haemorrhagic gastritis due to either salicylates or alcohol, 1 patient with an acute stress ulcer on the lesser curve of the antrum and 1 patient with a Mallory-Weiss laceration at the cardia.

There were 25 patients who were referred for gastroscopy more than 1 week following an upper gastro-intestinal haemorrhage. The site and nature of the bleeding lesion were diagnosed in 18 patients after investigation: 3 by gastroscopy alone, 3 by radiology alone, and in 7 patients the lesion was noted by both methods of investigation. Only 1 acute superficial gastric mucosal lesion was found in this group, the other 2 cases diagnosed only on gastroscopy being stomal ulcers which were not apparent on barium-meal examination.

Miscellaneous

Two patients with hereditary telangiectasia were examined. In 1, multiple pin-point telangiectatic lesions were scattered throughout the body of the stomach. There were 4 patients with pernicious anaemia and severe gastric atrophy, one of whom had, in addition, a carcinoma of the posterior wall of the body of the stomach.

Complications of Gastroscopy

Perforation of the cervical oesophagus occurred in one patient. This was due to an error of omission. The

flexible tip of the instrument was not straightened out before its removal from the stomach. The patient, an 87-year-old woman, complained of painful dysphagia for 2 days and X-rays revealed a small amount of air in the soft tissues of the neck. She was fed intravenously for 4 days and given parenteral tetracycline. She made an uneventful recovery.

In another patient 2 attempts to pass the instrument into the stomach had to be abandoned because of the development of severe laryngospasm.

DISCUSSION

Gastrosopes based on the fibre-optics principle present several advantages over the rigid or semi-rigid instruments. Their extreme flexibility and small diameter make them safe and easy to use. Neither general anaesthetic nor other special facilities are required during gastroscopy. As part of the present study many very ill patients were examined, some of them at the bedside. A small mouth, kyphoscoliosis, cervical spondylosis and inability to extend the neck no longer preclude the examination. Moreover, advanced age is no contraindication to gastroscopy; 18% of our patients were more than 70 years old. The only absolute contraindications to gastroscopy were an unco-operative patient, oesophageal obstruction or damage to the oesophageal mucosa, e.g. by caustics.

The unique features of this type of instrument, however, present some not inconsiderable disadvantages. It is difficult to control the position of the viewing lens of the gastroscope because of the flexibility of the instrument. Although there is no consistent blind area in the stomach, accurate localization of the field of vision and systematic examination of the stomach may be difficult. The angulus and pyloro-antral areas which are easily recognizable landmarks are exceptions to this rule. Moreover, because viewing is lateral the instrument cannot be advanced under direct vision. Finally, the field of vision depends upon the distance of the viewing lens from the wall of the stomach. At a distance of 5 cm. the field of vision is about 25 sq. cm., whereas at a distance of 1 cm. it is only about 0.5 sq. cm. The upper portion of the lesser curvature of the stomach is commonly very close to the lens. Insufflation of large quantities of air is often necessary to move the gastric mucosa away from the viewing lens for adequate scrutiny of this area.

Although no difficulty was encountered in passing the gastroscope through the stoma in patients who had undergone gastro-enterostomy, the duodenum could not be entered in any patient in the present series. This experience is similar to that of Cohen *et al.*⁴ who were unable to examine the duodenum during the course of 1,000 examinations of the stomach with the ACMI fibrescope. Examination of the distal end of the oesophagus was also not possible. Finally, the instrument possesses no biopsy channel; nor is it possible to obtain gastric washings for cytology. The last two features are not considered to be serious disadvantages. If biopsy or direct collection of gastric washings is subsequently thought to be necessary, instruments specifically designed for these purposes should be employed. Colcher³ and Morrissey *et al.*⁵ have recently reviewed the impressive array of available operating gastrosopes.

Gastroscopy as an adjunct to radiological studies of the

upper gastro-intestinal tract has proved to be a valuable procedure. Where the radiological features of a lesion are atypical, endoscopy may reveal characteristics which clinch the diagnosis. Gastroscopy has also proved useful in patients with upper gastro-intestinal symptoms and negative barium studies. In 8 out of 35 patients in this series the diagnosis was established gastroscopically. Further, because gastroscopy is now safe, easy to perform and comfortable for the patient, it is the method of choice for following the healing progress of gastric ulcers.

In the postoperative stomach, where the interpretation of the barium meal is difficult because of scarring and distortion, the gastroscopist can often make an invaluable contribution since adequate endoscopic examination in this sort of patient usually presents no difficulties either in carrying out the procedure or in the interpretation of the observations. In the present series of patients presenting after gastric surgery, pathological lesions demonstrated at gastroscopy were not evident on barium-meal examinations, carried out at approximately the same time, in over half the patients studied.

Finally, gastroscopy has been found to be a valuable procedure in the investigation of patients who are bleeding from the stomach. Although it is usually not possible to examine the gastric mucosa in the presence of active bleeding, gastroscopy within 48 hours of the cessation of haemorrhage will usually reveal the cause of bleeding if it originates within the stomach. If the procedure is delayed too long, however, the chance of demonstrating the presence of acute mucosal lesions such as an acute gastric ulcer, haemorrhagic gastritis or gastric erosions declines.

Of the 8 patients found to have acute gastric mucosal lesions, 7 were seen gastroscopically within 7 days of their presentation. The dangers of gastroscopy soon after an episode of gastric bleeding are negligible.⁶

SUMMARY

Two hundred and ninety-five gastroscopies were performed in 244 patients, using the Olympus GTF-A fibre-optic gastroscope with intragastric camera. The instrument is easy to use even in very ill patients. No serious complication occurred. No special facilities were required during gastroscopy. Visualization of all areas of the stomach was usually possible. Gastroscopy proved to be a useful adjunct to radiographic studies in the investigation of disease of the upper gastro-intestinal tract. It was of particular value in patients who had had previous gastric surgery and in those with acute upper gastro-intestinal haemorrhage.

We wish to thank Dr H. van Wyk, Medical Superintendent of Johannesburg Hospital, and Dr S. S. Weyers, Medical Superintendent of J. G. Strijdom Hospital, for permission to publish. We should also like to thank the Photographic Unit, Department of Medicine, University of the Witwatersrand, for the photographs. This study was made possible by the surgical and medical staff of the hospital who referred their patients to the Gastro-enterology Clinic.

REFERENCES

1. Ugi, T. (1954): Tokyo Medical Journal, **61**, 135.
2. Hirschowitz, B. I. (1961): Lancet, **I**, 1074.
3. Colcher, H. in Glass, G. B. J., ed. (1968): *Progress in Gastroenterology*, vol. 1, p. 97. New York: Grune & Stratton.
4. Cohen, N. N., Hughes, R. and Manfredi, H. E. (1966): Amer. J. Dig. Dis., **11**, 943.
5. Morrissey, J. F., Tanaka, Y. and Thorsen, W. B. (1967): Gastroenterology, **53**, 456.
6. Hirschowitz, B. I., Luketic, G. C., Balint, J. A. and Fulton, W. F. (1963): Amer. J. Dig. Dis., **8**, 816.