

VENOUS LIGATION FOR SEPTIC PULMONARY EMBOLI FOLLOWING SUPPURATIVE PELVIC THROMBOPHLEBITIS

H. R. KLEIN, M.B., B.CH., M.R.C.O.G., M.R.C.P. (LOND. AND EDIN.), *Department of Obstetrics and Gynaecology, University of the Witwatersrand, Johannesburg*, AND FAY SEGAL, M.B., B.CH., M.D. (RAND), *Department of Medicine, Baragwanath Hospital, Johannesburg*

Ligation of the inferior vena cava, for pyaemic metastatic abscesses due to septic emboli from suppurative pelvic thrombophlebitis, is not a new procedure. Despite the control and eradication of pyaemia in obstetrical and gynaecological practice, there exists a small number of cases where ligation of the venous drainage from the pelvis may be a life-saving measure.¹

In cases of puerperal pyaemia, Trendelenburg² and Miller³ demonstrated the presence of palpable thrombosed veins at operation. They ligated these individual veins proximal to the thrombus. Uninvolved branches of the inferior vena cava and ovarian veins were not ligated. As their mortality rates were only slightly better than those

following expectant therapy, this method fell into disrepute.

However, it was Collins *et al.*¹ who showed that surgical ligation could be highly successful in cases of pyaemia, even though medical treatment had failed. This they achieved, by completely interrupting the venous return from the uterus and ovaries by ligating the inferior vena cava and the ovarian vessels, irrespective of the site of the venous thrombophlebitis.

Five cases of septic pulmonary emboli following suppurative pelvic thrombosis are presented. Conservative treatment had failed, and ligation of the inferior vena cava was considerably beneficial and a life-saving procedure.

CASE REPORTS

Case 1

A 27-year-old Bantu female, gravida 2, was readmitted to hospital on 18 January 1963, after having had a curettage 6 days previously for an incomplete abortion. She was severely ill with lower abdominal pain, rigors, and pelvic peritonitis. Her temperature was 102.2°F, pulse rate 152 per minute, and respiratory rate 36 per minute.

Progress. In spite of numerous antibiotics and blood transfusions (Fig. 1 and Table I) her condition showed further deterioration. The persistent anaemia was due to infection, as there was no blood loss or haemolysis, and responded only to frequent blood transfusions.

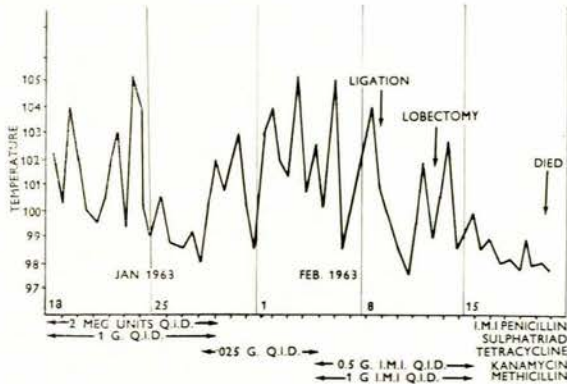


Fig. 1. Temperature chart of patient who died following rupture of the bronchus.

TABLE I. REFRACTORY ANAEMIA RESPONDING ONLY TO FREQUENT BLOOD TRANSFUSIONS

Date:	20/1/63	29/1/63	7/2/63	9/2/63	10/2/63	13/2/63	18/2/63
Hb. (G/100 ml.)	8.0	8.4	9.2	Liga-tion	9.9	Lo-bec-tomy	12.8
Blood transfusion (ml.)	1,000	1,500	1,500	500	1,000	1,500	—

On 4 February 1963, she developed a cough productive of purulent sputum. An X-ray film (Fig. 2) showed multiple lung abscesses on the right side. Blood, cervical and sputum cultures grew a profuse growth of *Escherichia coli*.

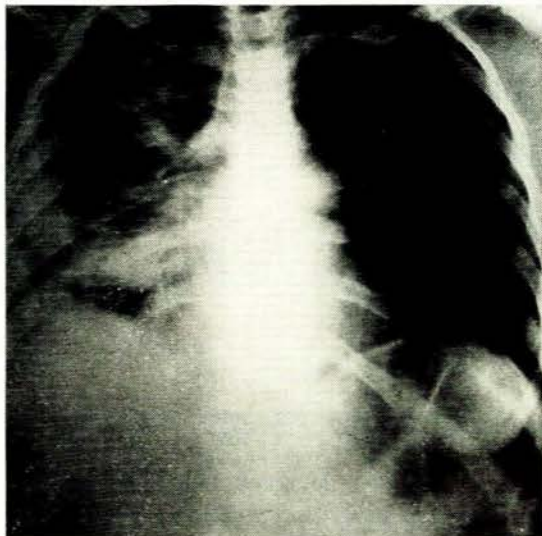


Fig. 2. X-ray of the chest showing abscesses in the right upper, middle and lower lobes.

Five days later, with her pulse rate 160 per minute and respirations 46 per minute, the inferior vena cava was ligated under general anaesthesia. The vessel was approached extraperitoneally through a right transverse oblique incision, and ligated 2.5 cm. below the entrance of the renal veins with 2 ligatures of No. 3 chromic catgut. The vessel appeared healthy.

Postoperatively, the fall in blood pressure was corrected by raising the foot of the bed and administering phenylephrine intravenously. A dramatic improvement in the patient's condition occurred. The pulse rate was 100 per minute and respirations 24 per minute. There was no oedema of the legs.

On 13 February 1963 she developed a persistent massive haemoptysis, and a right middle and lower lobe lobectomy was performed. The specimen of lung tissue removed showed 2 abscess cavities, and organized septic thrombus in the branches of the inferior pulmonary vein.

Convalescence was uneventful until 19 February 1963, when she suddenly became dyspnoeic and died. Autopsy showed the right bronchial stump had ruptured, producing a tension pneumothorax. The uterus contained a number of organizing intramural abscesses. There was a large right tubo-ovarian abscess (culture produced a profuse growth of *E. coli*). The inferior vena cava showed no evidence of thrombus formation above or below the ligature.

Case 2

A 25-year-old Bantu female, para 3, gravida 4, was admitted on 31 December 1963 with pelvic peritonitis.

Progress (Fig. 3). The patient required frequent blood trans-

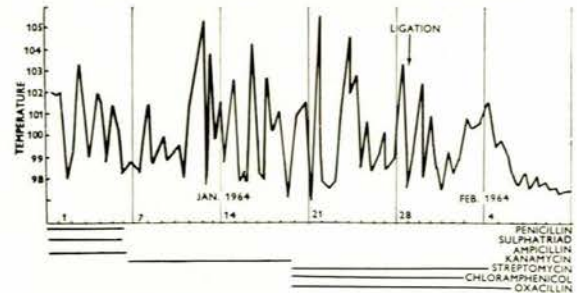


Fig. 3. Temperature chart showing lack of response to various antibiotics.

fusions for the refractory anaemia. Her general condition did not improve on conservative treatment, although the pelvic tenderness had completely regressed.

She became jaundiced on 13 January 1964 and this diminished only after operation (Table II). The blood urea was not raised.

TABLE II. BLOOD BILIRUBIN CONCENTRATION BEFORE AND AFTER OPERATION

Date:	17/1/64	24/1/64	28/1/64	29/1/64	7/2/64	29/2/64	9/3/64
Total bilirubin (mg./100 ml.)	6.6	12.8	14.6	Ligation	9.5	3.2	2.4
Direct (mg./100 ml.)	5.4	10.4	12.1		6.8	2.5	1.8

An X-ray film of the chest on 9 January 1964 showed clear lung fields. On 20 January 1964 she developed left-sided chest pain and an X-ray of the chest on this occasion (Fig. 4) showed numerous bilateral lung abscesses. Nine days later the inferior vena cava was ligated by the extraperitoneal approach. The vessel was healthy. She made a rapid and uneventful recovery after this procedure and was discharged on the 13th postoperative day.

Blood cultures were persistently negative. However, the sputum and cervical discharge produced an abundant growth of *E. coli*.

Case 3

A 30-year-old Bantu female, para 1, was admitted to hospital on 6 February 1964. She had a criminal abortion 17 days previously, and this was followed by rigors.

She was desperately ill with rigors, anaemia, jaundice, and obvious weight loss. Apart from a thrombophlebitis of the right leg there were no other abnormal signs. An X-ray film of the chest showed small areas of patchy consolidation in both lungs. These later broke down to form small abscess cavities. Culture of the sputum showed *Bacillus proteus*. Blood cultures were negative.

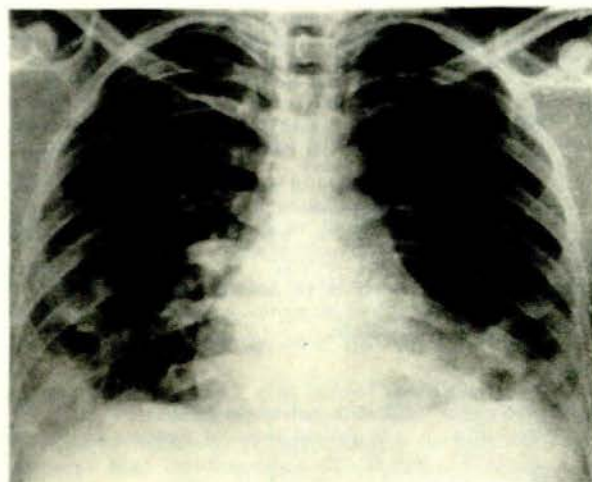


Fig. 4. X-ray of the chest showing numerous cavities in both lung fields.

There was no improvement on antibiotics and blood transfusions, and as the jaundice was becoming deeper, the inferior vena cava was ligated on 15 February 1964. A periphlebitis was observed and thrombi palpated in the vessel. There was a dramatic improvement in the patient's general condition. The day after operation the temperature was normal for the first time since admission, and the pulse and respirations were much slower.

A few days postoperatively she developed thrombophlebitis of the left leg. She was discharged from hospital on 28 March 1964 with bilateral pedal oedema and abdominal varicosities.

Case 4

A 23-year-old Bantu female, para 3, gravida 4, had a curettage on 3 February 1964 for an incomplete criminal abortion. She was readmitted on 11 February 1964 with bilateral salpingo-oophoritis and pelvic peritonitis. There was an oliguria (urinary output 400 ml. per 24 hours).

Special investigations. Haemoglobin 7.6 G/100 ml., serum bilirubin 14.4 mg./100 ml. (direct 13.6 mg./100 ml.); blood urea 79 mg./100 ml. *Staphylococcus pyogenes* was cultured from the sputum and *E. coli* from the cervix.

The acute renal failure was managed conservatively by restriction of fluids and protein (Table III) and by allowing 150 G lactose per day. On 27 February 1964 she developed a productive cough with purulent sputum. A chest X-ray showed multiple lung abscesses. On 10 March 1964 there was further deterioration in the patient's condition. Her jaundice had increased (bilirubin 19.8 mg./100 ml.) and she had required 5,000 ml. of blood during her stay in hospital. Ligation of the inferior vena cava via the extraperitoneal approach was performed. There was a mild periphlebitis, but no thrombus formation.

There was an immediate improvement in the patient's condition. The lung abscesses resolved with the aid of postural

drainage and physiotherapy. The fever subsided 6 days after operation (Fig. 5).

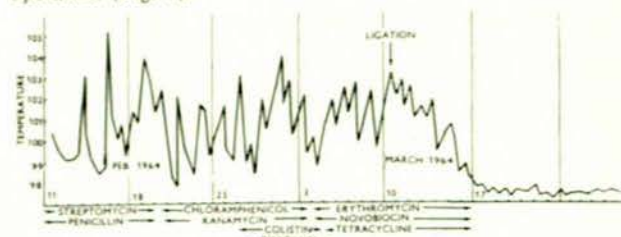


Fig. 5. Temperature chart showing the response to ligation of the inferior vena cava.

Case 5

A 19-year-old Bantu female, para 1, gravida 1, had a normal pregnancy and uncomplicated confinement on 27 March 1964. Four days later she appeared to be very ill with a high temperature (Fig. 6) and a rapid pulse and respiration. She had a

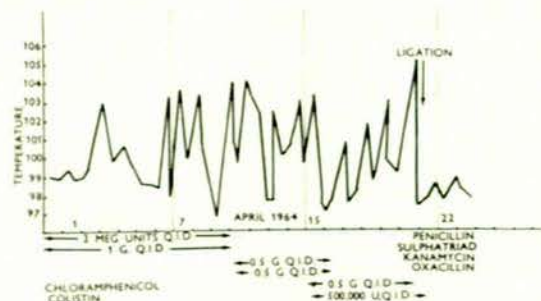


Fig. 6. Temperature chart showing prompt response to operation.

right parametritis.

An X-ray film of the chest showed an opacity in the right lower lobe suggestive of 'pneumonitis'. There was no improvement with therapy and further X-ray (Fig. 7) showed a solitary lung abscess in the right lower lobe. Rigors persisted and she

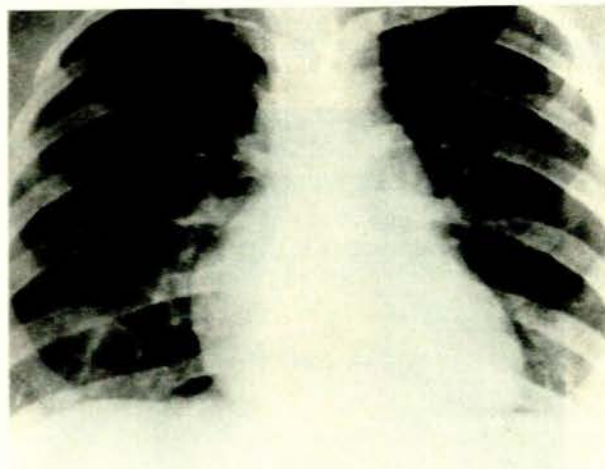


Fig. 7. X-ray of the chest showing a solitary lung abscess in the right lower lobe.

TABLE III. NO DETERIORATION OF RENAL FUNCTION AFTER LIGATION, AS SHOWN BY BLOOD UREA LEVELS

Date:	12/2/64	14/2/64	20/2/64	27/2/64	1/3/64	9/3/64	10/3/64	12/3/64	16/3/64	25/3/64
Urea (mg./100 ml.)	79	164	146	158	160	154	Ligation	122	52	39

developed jaundice (serum bilirubin 10 mg./100 ml., direct 7.2 mg./100 ml.).

On 20 April 1964 ligation of the inferior vena cava and ovarian veins was performed. An extraperitoneal approach was used, but as the inferior vena cava was bound down by adhesions, it could not be identified and this route was abandoned in favour of the intraperitoneal approach. There was evidence of a pelvic peritonitis and bilateral salpingo-oophoritis.

There was a dramatic improvement (Fig. 6) and the patient was discharged well. She required 4,800 ml. of blood during the course of her illness. Cultures from the cervix revealed *E. coli*. Blood cultures were positive on 10 occasions, showing *S. pyogenes* and *E. coli*.

DISCUSSION

The 5 cases of septic pulmonary emboli and infarction following on suppurative pelvic thrombophlebitis were seriously ill. All had high swinging temperatures and deterioration was noted in spite of the antibiotics used. In some cases the dosage of antibiotic used was greater than that generally recommended for severe infection. The patients all had severe persistent anaemia which responded only to frequent blood transfusions. From previous personal experience of this condition, it is felt that the majority of these patients would have died, had not ligation of the inferior vena cava been performed. Some of the effects after ligation were dramatic, as shown by a rapid improvement in their general state, temperature, pulse and respiration rates.

However, in our experience, not all cases with evidence of pyaemic emboli have a fatal outcome.⁴ Neuhof and Aufses⁵ reported 2 cases of pyaemic lung abscesses, demonstrated by radiology, which survived after being treated with sulphonamides.

In retrospective analysis there was considerable delay before venous ligation was performed in our cases (from 9 to 30 days after admission to hospital). In a series of 70 cases of suppurative pelvic thrombophlebitis treated by ligation of the inferior vena cava and ovarian veins, recovery was complete in 89% of cases.⁶ The 8 deaths were caused by metastatic septic foci, related in 4 to delay in operation. These results tend to place proximal venous ligation on a solid foundation.

According to Collins *et al.*¹ the indications for venous ligation in suppurative pelvic thrombophlebitis are:

1. Failure of the fever to respond to 4-5 days of medical treatment.
2. Development of pulmonary infarction while on treatment.
3. Evidence of pulmonary infarction on admission, when operation is immediately performed.

Our indications for ligation are:

- (a) Evidence of septic pyaemic emboli with pulmonary infarction demonstrated by radiology.
- (b) Poor or no response to medical treatment.
- (c) Jaundice and persistent or refractory anaemia.

We do not consider ligation in cases of septicaemia without evidence of pulmonary infarction (see above). If there is evidence of pulmonary infarction on admission (see 2 above) we would advise conservative treatment in the first instance, and only ligate the inferior vena cava if there is any deterioration in the patient's condition.

Suppurative pelvic thrombophlebitis is a distinct entity

resulting from sepsis affecting the pelvic veins, and may occur independently of thrombosis in the veins of the leg.⁷ This results in purulent thrombi, which tend to break off in showers as small infected emboli. This can occur under treatment with antibiotics (all our cases) or even if anticoagulants have been administered. We did not use anticoagulants in any of the cases as there is a greater risk of haemorrhage in septic emboli and septicaemia.

The diagnosis of the condition is often difficult,⁷ and a constant awareness of the possibility is necessary to make a diagnosis. In the presence of fever, rigors, tachycardia, jaundice or persistent anaemia, following an abortion, confinement or salpingo-oophoritis, an X-ray film of the chest should be taken, and may have to be repeated several times in the course of the illness. In 3 of our cases the condition was not suspected until after the development of signs and symptoms pertaining to the respiratory tract. After we became aware of the condition, 2 cases of pulmonary emboli were diagnosed before the development of respiratory symptoms.

Blood cultures are not always helpful in isolating the infective organism. In only 2 of our 5 cases were bacteria isolated, even after repeated cultures. The organisms which were cultured either from the blood or the cervix, and which were thought to be responsible for the pyaemia, were *E. coli* (2 cases), *B. proteus* (1 case), *S. pyogenes* (1 case), *S. pyogenes* and *E. coli* (1 case).

On pelvic examination hard tender cords of thrombosed veins may be palpable in the base of the broad ligament.¹ In our cases there were either no abnormal physical signs in the pelvis, or there was so much induration due to a parametritis or salpingo-oophoritis, that any thrombosed veins could not be identified apart from these masses.

Collins *et al.*¹ suggest that the venous return from the uterus should be interrupted by ligation of the inferior vena cava and ovarian veins through the intraperitoneal route, so that both ovarian veins can be tied and any pelvic abscess drained at the same time. In 4 of our cases the vessel was approached extraperitoneally as this was more easily performed with less trauma to the patient,⁸ but in the fifth case the intraperitoneal route was used, the inferior vena cava being inaccessible due to marked periphlebitis.

Often no postoperative sequelae are seen in the lower limbs, except for mild oedema which tends to persist for a few weeks. There appears to be an adequate collateral circulation through the vertebral, azygos and portal veins.⁹

The superficial veins of the trunk are the least important. If there is oedema of the lower limb before operation, this will persist or be aggravated (case 3). It appears that lower extremities with pre-ligation evidence of thrombophlebitis have more unfavourable sequelae such as oedema, ulceration, pain and dermatitis, than those without previous disease.⁸

Ligation of the inferior vena cava prevents further dissemination of the majority of septic emboli to the body, above the occlusion. The infection is localized to the pelvis allowing antibiotics and the natural defensive mechanisms of the body to resist and overcome it. There is also a reduced venous return to the heart and a bradycardia after ligation.¹⁰ This may improve the cardiac capacity especially if there is a toxic myocarditis.

SUMMARY

Septic pulmonary emboli and infarction were demonstrated in 5 cases following suppurative pelvic thrombophlebitis. These patients were critically ill and, in spite of medical treatment, their condition continued to deteriorate. Ligation of the inferior vena cava was performed. Four of the 5 cases survived, and evidence is presented that a fatal outcome was averted by the operation. The fifth case died as a result of a ruptured bronchus after lobectomy for a lung abscess.

We wish to thank Messrs. J. Hunt, S. Sher and other members of the medical staff of Baragwanath Hospital for their assistance with these cases. The illustrations were produced by the Photographic Unit, Department of Medicine, University of the Witwatersrand.

REFERENCES

1. Collins, C. G., Nelson, E. W., Ray, C. T., Weinstein, B. B. and Collins, J. H. (1949): *Amer. J. Obstet. Gynec.*, **58**, 1155.
2. Trendelenburg, F. (1906): *J. Amer. Med. Assoc.*, **47**, 81.
3. Miller, C. J. (1917): *Surg. Gynec. Obstet.*, **25**, 431.
4. Klein, H. R. and Segal, F. (1966): Unpublished data.
5. Neuhof, H. and Aufses, A. H. (1943): *Surg. Gynec. Obstet.*, **77**, 544.
6. Collins, C. G., Norton, R. O., Nelson, E. W., Weinstein, B. B., Collins, J. H. and Webster, H. D. (1952): *Surgery*, **31**, 528.
7. Collins, C. G., MacCullum, E. A., Nelson, E. W., Weinstein, B. B. and Collins, J. H. (1951): *Ibid.*, **30**, 298.
8. Kirtley, J. A. jnr., Riddell, D. H. and Hamilton, E. C. (1955): *Ann. Surg.*, **141**, 653.
9. Robinson, L. S. (1949): *Surgery*, **25**, 329.
10. Cossio, P. (1952): *Amer. Heart J.*, **43**, 97.