

## PELVIC ARTHROPATHY\*

RICHARD PERCY-LANCASTER, M.B., CH.B. (EDIN.), F.R.C.S. (EDIN.), *Department of Orthopaedic Surgery, Frere Hospital, East London*

Backache is a frequent complaint in pregnancy and during the puerperium. Elder (cited by Young)<sup>1</sup> found that 3.7% of pregnant women suffered from backache to such a degree that they required treatment.

As pregnancy advances, the abdominal contents are displaced upwards and there is distension of the abdominal musculature. In primigravidas, the abdominal wall is more tense and sags less than in women who have borne children. The pregnant woman throws her shoulders back and straightens her head and neck.<sup>2</sup>

The effect of pregnancy upon the curvature of the lumbar spine and the tilt of the pelvis is variable. Most observers describe an increase in the normal lumbar lordosis associated with a forward tilt of the pelvis, but a flattening of the lumbar spine is sometimes encountered. Some change in posture is inevitable, and reverse compensatory curves develop in the dorsal and cervical spine to maintain balance. The dynamics of the spinal column are disturbed due to the alteration of the patient's accustomed posture and it is therefore not surprising that lumbar backache is such a common symptom in pregnant women, for abnormal stresses and strains are thrown upon the intervertebral joints, affecting the discs, the ligaments and the spinal muscles. Young, healthy primigravidas are better able to adapt to the alterations in posture which pregnancy brings than debilitated women and those multiparas with pendulous abdomens and lax musculature.

In such patients the changes in posture are even more marked.

During the 9 months of pregnancy, the joints of the spine and the pelvis, together with their associated ligaments and muscles, have the opportunity to adapt gradually to the altered mechanics, but following parturition there is a sudden, though incomplete, return to the *status quo ante*. Even though the curvatures of the spine may revert to their pre-pregnant state, the poor-toned muscles and softened ligaments which have been overstretched and strained during pregnancy are unable to cope with the increased demand placed upon them by the mother faced with the burden of caring for her home and children. Backache in the puerperium is so common that it is almost taken for granted.

Patients with pre-existing abnormalities of the spine, whether congenital or acquired, are even more likely to develop lumbar backache during pregnancy and in the puerperium.

### PELVIC MECHANICS

The primary skeletal function of the pelvis is to provide for stable transference of body-weight from the vertebral column to the femora. Weight is transmitted through the upper part of the sacrum and the adjoining part of each iliac bone to the head of the femur. These parts constitute a pelvic arch of thickened bone. The ventral pelvic bar formed by the superior rami and bodies of the pubic bones connected by the symphyseal ligaments acts as a horizontal tie-beam connecting the bases of the pillars of the arch. The sacrum is the keystone of the arch (Fig. 1).

The body-weight tends to displace the sacrum down into the pelvis with a tendency to separation of the hip bones, but this is resisted by the strong ligaments behind the sacro-iliac joints. Any tendency to flattening of the arch, with opening of the sacro-iliac joints anteriorly, is resisted by the tie-beam action of the ventral pelvic bar.

A slight amount of gliding movement is possible at the sacro-iliac joints and the symphysis pubis.<sup>3</sup>

During pregnancy, relaxation of the ligaments of the pelvic girdle occurs in certain mammals, particularly in the pocket gopher, but in parturient women the normal range of movement is very slightly increased and this has only a minor influence on the process of labour.

The relaxation of the ligaments of the pelvic girdle is thought to be due to the presence of a hormone called relaxin. It has been found in many

\*Date received: 29 July 1968.

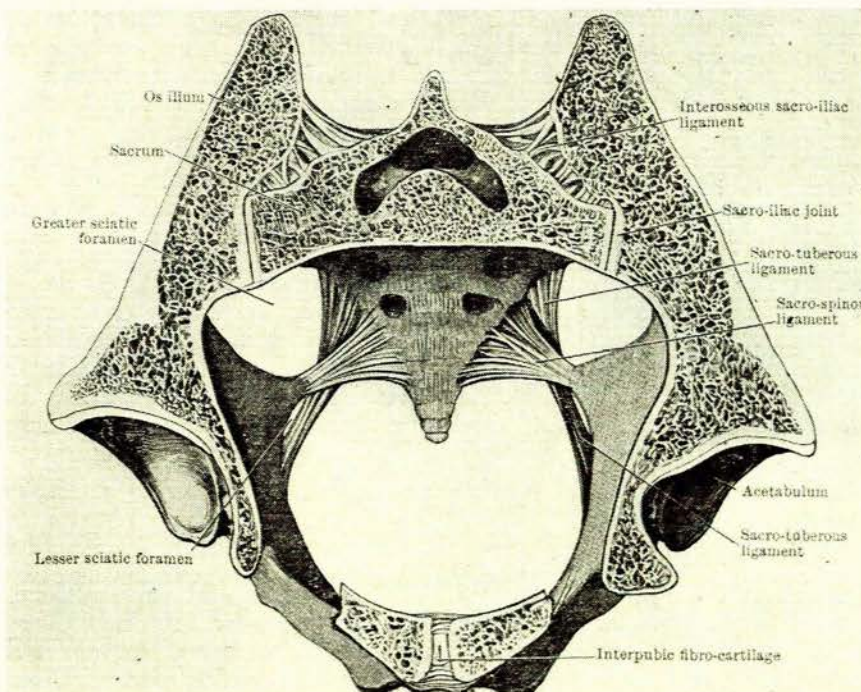


Fig. 1. Cross-section through pelvis showing the arch of the pelvis and the sacrum as the keystone.<sup>3</sup>

mammals and is obtained as an extractive fraction from the corpus luteum of the sow. The chemical identity of the hormone has not been clearly established, but it is believed to be a water-soluble, neutral protein or polypeptide. It has been demonstrated in the blood serum of normal pregnant women, increasing progressively during pregnancy and decreasing rapidly after parturition.<sup>2</sup>

The tissues of the pelvic joints absorb fluid, the capsules thicken, the vascularity is increased and the synovial membranes hypertrophy.

Relaxation of the ligaments of the symphysis pubis and sacro-iliac joints begins during the first half of pregnancy and reaches a maximum at the seventh month, diminishing after labour due to the withdrawal of the hormone relaxin. Within 6 months the skeletal ligaments return to their normal firmness in the average patient.

Separation of the pubic bones at the symphysis during pregnancy is a common finding, the width of the symphysis varying between 0 and 35 mm., the average being between 7 and 8 mm. Slate<sup>4</sup> considers that a separation of more than 8 or 9 mm. is pathological.

Vertical mobility of the symphysis pubis can be measured by the technique of Chamberlain.<sup>5</sup> The patient stands facing a vertical Potter-Bucky diaphragm. Antero-posterior views are taken of the symphysis, first with the patient standing with a wooden block under the right foot and then with a block under the left foot (Fig. 2).

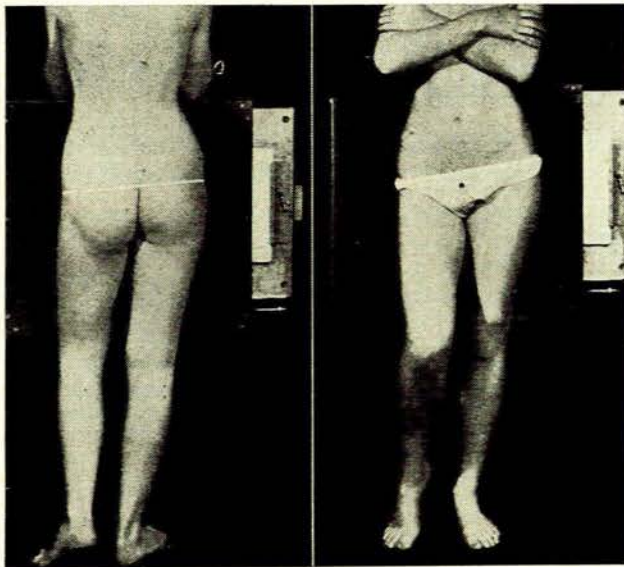


Fig. 2. The technique of Chamberlain (from Clark).<sup>6</sup>

Chamberlain<sup>5</sup> found that the normal shift in the male was between 0 and 0.5 mm. In the non-pregnant female the shift is between 0 and 1.5 mm.

#### *Pelvic Arthropathy*

Excessive relaxation of the ligaments of the pelvic joints causes symptoms which usually appear about the sixth or seventh month of pregnancy. The patient first experiences pain on walking or on exertion. The pain may

be sudden and so severe that walking or standing is almost impossible. It is frequently excruciating, particularly when the patient turns in bed or twists while in the standing position. The gait is usually affected. When the degree of relaxation is slight there is usually a one-sided limp, but when it is severe the patient exhibits a waddling gait similar to that seen in a patient with bilateral congenital dislocation of the hips, and ambulation is difficult and extremely painful.

Young<sup>7</sup> has suggested referring to this degree of excessive relaxation of the pelvic joints during pregnancy as 'pelvic arthropathy of pregnancy'.

The symptoms of arthropathy may only appear after labour, due to marked loosening of the sacro-iliac joints and diastasis of the symphysis pubis. This is more likely to occur with patients where the ligaments of the joints of the pelvis are unduly lax, and in those where general anaesthesia and the lithotomy position are used for delivery. Rupture of the ligaments of the symphysis pubis may occur during a forceps delivery, particularly if there is disproportion between the foetus and the pelvic brim. Usually the patient has complained of pain in the pubic and sacro-iliac joints, with difficulty in ambulation before labour. Labour is the period when the greatest strain is thrown on the spinal and pelvic ligaments and when maximal exertion of the abdominal and pelvic muscles occurs. The patient complains of severe pain over the symphysis pubis and the sacro-iliac joints, radiating down the thighs. The legs are everted and she has difficulty in moving them. Subsequently the woman is severely crippled and is confined to bed, being unable to walk properly for weeks or months. A similar condition develops when the ligaments are overstretched.

The diagnosis of pelvic arthropathy should never be in doubt once one is aware of the problem. The history of pregnancy together with pain over the symphysis pubis or the sacro-iliac joints or both, together with difficulty in ambulation, should arouse one's suspicion. Tenderness over the sacro-iliac joints and particularly over the symphysis pubis is characteristic. The relaxation of the symphysis pubis can be ascertained by standing behind the patient as she walks and placing one's fingers over the superior aspects of the pubic bones. In well-marked cases, the vertical shift of the symphysis pubis is readily elicited. Another recommended method of determining the degree of movability of the symphysis is to examine the patient on her back with a forefinger placed in the vagina and the thumb over the symphysis. An assistant pulls down on one ankle and pushes the other foot upwards. The amount of movability is readily felt by the examiner during the manipulation.

If one is in doubt, Chamberlain's<sup>5</sup> test reveals the shift at the symphysis pubis.

Those women who are severely crippled in pregnancy should be made to rest as much as possible and be given muscle-toning exercises. They should wear suitable corsets. During labour such patients must be handled carefully. The posture adopted for delivery is important and the lithotomy position is particularly harmful. Excessive and unwarranted movements of the trunk and the limbs should be prevented, as the ligaments of the sym-

physis pubis and the sacro-iliac joints are soft and liable to rupture.

If symptoms commence or persist following parturition, absolute bed rest, pelvic supportive measures and exercises are imperative for some weeks.

In a series of 4,512 pregnant women reported on by Young,<sup>2</sup> pelvic arthropathy occurred 34 times, an incidence of 0.75%. In following up these cases, he found that 46.6% had persistent severe crippling backache.

#### CASE REPORTS

##### Case 1

A patient aged 36 years had had 6 pregnancies in 8 years. In each pregnancy, especially in the later stages, the only way she could maintain her balance in locomotion was by throwing her shoulders far backwards. She experienced severe backache during each pregnancy.

Her last confinement was on 4 July 1960. Labour was rapid and the baby weighed 9 lb. 1 oz. She was allowed up on the 3rd day and apparently was able to walk satisfactorily.

On the 6th day, while walking, she was seized with severe pain in the perineum and had great difficulty in returning to bed. Subsequently she found it almost impossible to turn without assistance, because of severe pain over the symphysis pubis and sacro-iliac joints.

She was discharged from hospital on the 10th day but went home to bed. A week later, while walking to the toilet, she was immobilized by excruciating pain in the pubis and perineum.

When I saw her a month after confinement, she had a pronounced limp of the right leg and a bilateral Trendelenburg's sign. Abduction of the right hip caused perineal pain. She was very tender over the symphysis, both rami of the right side of the pubis and both sacro-iliac joints.

A study of the radiographs revealed an upward vertical shift of the right side of the pubis of 7 mm. When the patient stood on the left leg the amount of displacement of the left side of the pubis was 3 mm. (Fig. 3).

Absolute bed rest was recommended, together with the wearing of a lumbosacral corset, and physiotherapy.

A slight limp and symphyseal and sacro-iliac pain were still present 2 months later, but 5 weeks thereafter the limp had disappeared, though tenderness of the pelvic joints remained, as did excessive mobility of the symphysis.

She became symptom-free some months after confinement.

##### Case 2

A woman of 35 years, with 5 children, was 7 months pregnant and complained of incapacitating backache and difficulty in walking.

She had a waddling gait and was very tender over the symphysis pubis and sacro-iliac joints. Bed rest and the wearing of a firm pelvic support were recommended.

Labour was induced at the 36th week. Unfortunately the child died on the second day from respiratory distress syndrome. In spite of rest in bed for a further month, she

continued to complain of pain over the symphysis pubis. Her activities were gradually increased and a month later she was symptom-free.

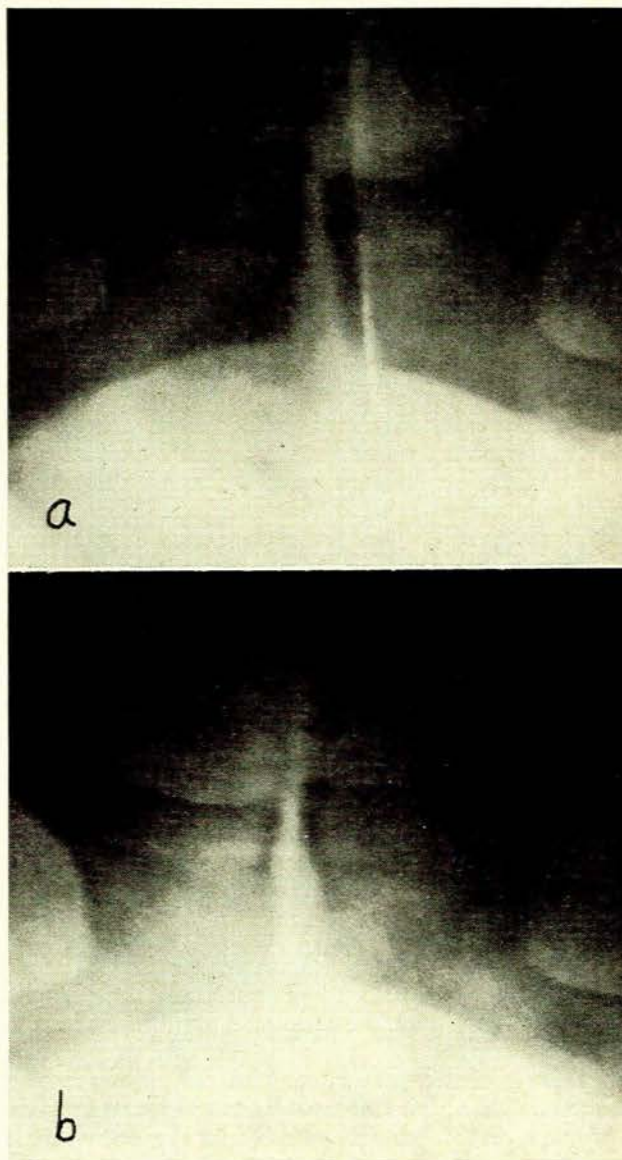


Fig. 3a. Upward vertical shift of right pubis (7 mm.).  
3b. Upward vertical shift of left pubis (3 mm.).

Radiographs after delivery revealed that the width of the symphysis was 6 mm. Chamberlain's<sup>3</sup> test showed that there was a 3-mm. vertical shift of the right side of the pubis when she stood on the right leg, but no shift of the left side when she stood on the left leg (Fig. 4).

##### Case 3

A woman of 30 years—para 1, gravida 2—had complained of backache and difficulty in walking during both pregnancies, increasing as pregnancy advanced. She used

to have acute attacks of pain in the right sacro-iliac joint while walking which would temporarily immobilize her. Tenderness was present over the symphysis pubis and the right sacro-iliac joint.

of her first trimester she had complained of backache and pain over the symphysis pubis. Towards the end of her pregnancy she was only able to walk from the front door of her house to the gate, and did so with great difficulty because of severe pain. Labour was normal.

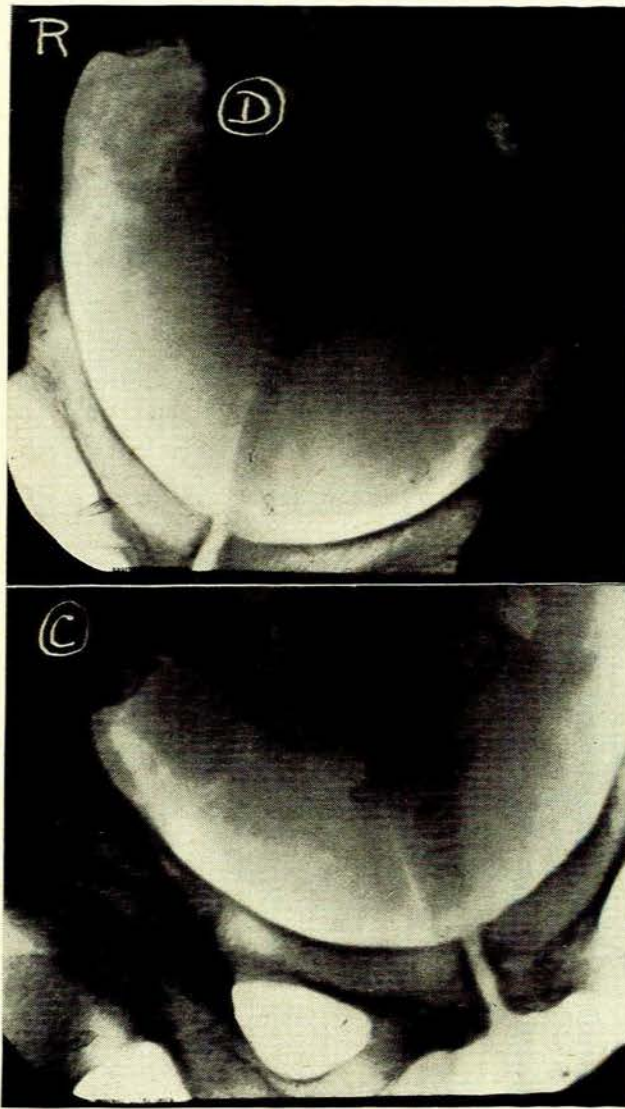


Fig. 4. Above: Vertical shift of right pubis (3 mm). Below: No shift of left pubis.

Labour was normal. Following her confinement she continued to experience sacro-iliac and symphyseal pain for months, especially on bending and turning.

Radiographs taken after confinement showed the width of the symphysis pubis to be 6 mm. and the upper margin of the body of the left pubis to be slightly higher than that on the right side. Chamberlain's test revealed a 3-mm. vertical shift of the left side of the pubis, but no shift on the right (Fig. 5).

#### Case 4

A woman of 32 years—para 1—was seen by me on 5 March 1965, 5 months after her confinement. At the end

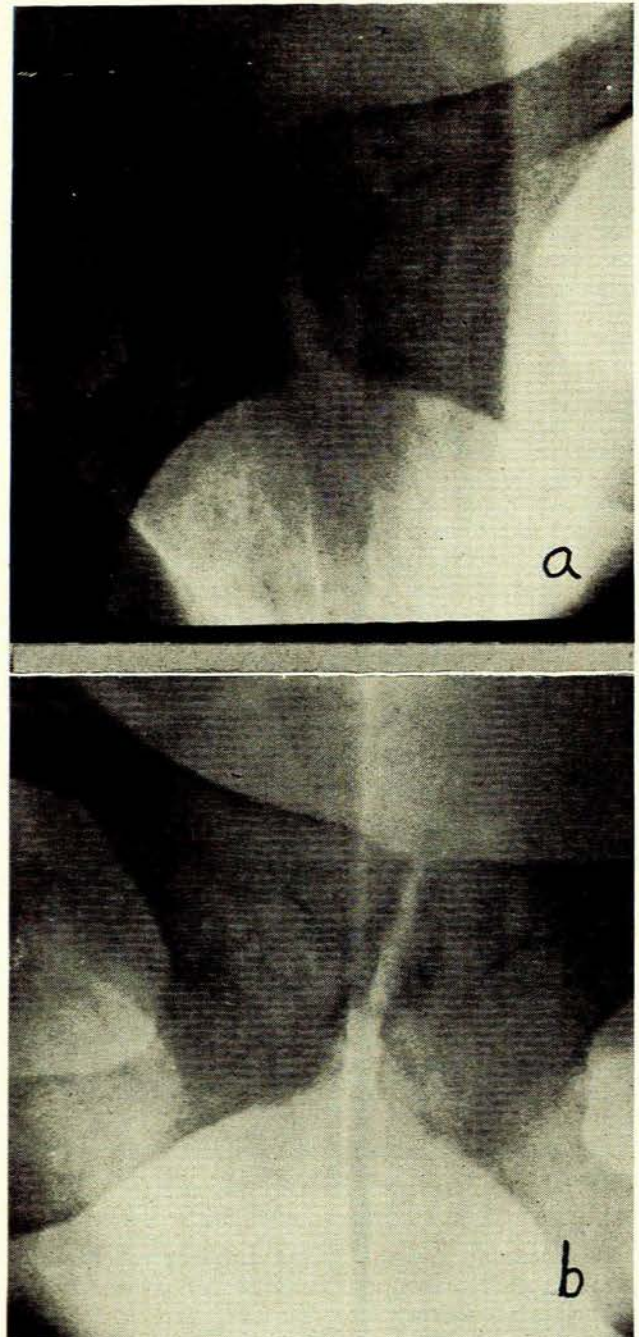


Fig. 5a. Vertical shift of left pubis (3 mm.). 5b. No shift of right pubis.

Following confinement she continued to complain of pain over the symphysis, particularly on walking. The

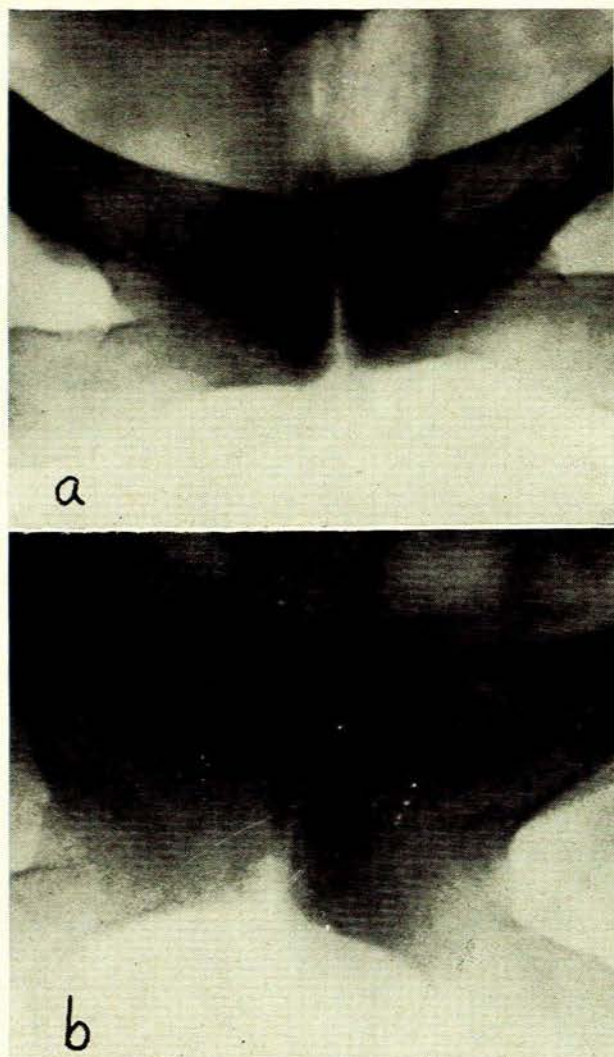


Fig. 6a. Vertical shift of left pubis (3 mm.). 6b. No shift of right pubis.

pain was aggravated by vigorous exercises, but was also experienced on rising to the erect position after lying down or sitting for any length of time.

She was very tender over the symphysis, the inferior ramus of the right side of the pubis and over the right sacro-iliac joint. Abduction of the right hip was very painful.

Radiographs revealed that the width of the symphysis pubis was 2 mm. Chamberlain's<sup>5</sup> test showed an upward shift of 3 mm. of the left side of the pubis on standing on the left leg, but no shift on standing on the right leg (Fig. 6).

#### Case 5

A woman of 25 years—para 2, gravida 3—was seen at her 38th week of pregnancy. The patient had had backache in all 3 pregnancies but no difficulty in ambulation during the first 2 pregnancies. Following the first confinement, ambulation was difficult for a few weeks.

At the end of the second trimester of the present pregnancy she developed lumbar backache and pubic pain. The pain was particularly severe on walking, sitting and turning in bed.

Examination revealed tenderness over the symphysis pubis. A gap could be palpated between the pubic bones. The gait was unaffected; but on placing one's fingers on the pubis during ambulation, one was conscious of a slight up-and-down movement.

The width of the symphysis pubis was 12 mm., and the right side of the pubis was higher than the left in the recumbent position.

Chamberlain's<sup>5</sup> test revealed a vertical shift of 8 mm. of the right side of the pubis but no shift of the left side (Fig. 7).

Labour was induced at the 42nd week. Backache was severe during and after labour, but symphyseal pain was negligible.

She was discharged from hospital on the 10th day, without a limp but complaining of severe sacro-iliac pain. Physiotherapy and a corset were prescribed.

Slate<sup>4</sup> considers that a separation of more than 8 mm. of the symphysis pubis during pregnancy is pathological and often produces symptoms. Chamberlain<sup>5</sup> found that more than a 2-mm. vertical shift of the symphysis was accompanied by pain.

In my series, the width of the symphysis varied between 2 and 12 mm., with an average of 7.2 mm., and the vertical symphyseal shift varied between 3 and 7 mm., with an average of 4.8 mm.

Although my series of patients with pelvic arthropathy of pregnancy is very small, I am inclined to the view that even a small shift of the symphysis pubis can evoke troublesome pain and severely cripple a pregnant woman not only during her pregnancy but for several weeks or months after confinement.



Fig. 7. Left: Vertical shift of right pubis (8 mm.). Right: No shift of left pubis.

### SYMPHYSEOTOMY

The operation of symphyseotomy was abandoned many years ago because of the dangers inherent in the operation, such as haemorrhage, osteitis pubis, damage to the bladder and dislocation of the urethra.

The operation is still undertaken by some obstetricians in South Africa when dealing with certain selected cases of cephalopelvic disproportion in the Bantu, especially among the primitive people who live in isolated rural areas.

Those who advocate the procedure feel that once a caesarean section has been undertaken in these people the resultant scarring that ensues predisposes the uterus to rupture in a subsequent labour unless the operation is repeated, for, as is well-known, the uneducated Bantu frequently seeks medical advice at a very late stage. In those cases of gross cephalopelvic disproportion which have undergone caesarean section, rupture of the uterus is apparently a very real possibility. It is felt that symphyseotomy in such women, while it has its drawbacks, at least increases the chances of a successful spontaneous delivery.

The operation is indicated when labour is prolonged, in cases of marked cephalopelvic disproportion and when a fair trial of labour (including the use of vacuum extractors) has failed. It can be done under general anaesthesia or under narcosis induced by the intravenous injection of pethidine and Phenergan together with local anaesthesia. Through a stab incision, the ligaments of the symphysis pubis, including the arcuate ligament, are divided. A wide episiotomy is also undertaken. Almost immediately the symphysis pubis begins to separate, until a thumb can be placed between the pubic bones. Descent of the head is rapid and frequently delivery can be effected within a matter of minutes, although this is not always the case.

#### Case Report

A Bantu woman aged 22 was admitted to the non-White orthopaedic ward at Frere Hospital in East London. She had undergone symphyseotomy 3 months previously at a mission hospital and was quite unable to walk. She lay in bed with both legs flexed and externally rotated, and had great difficulty in moving her legs and turning in bed. She experienced severe pain in both sacro-iliac joints, the symphysis pubis, the perineum and the back of the left thigh.

A radiograph of the symphysis pubis taken on 11 May 1966 revealed wide separation. She was treated with a tight pelvic bandage, was nursed on a firm mattress and was given analgesics and physiotherapy. Six weeks later she was walking with a limp and still complaining of symphyseal and sacro-iliac pain.

Chamberlain's test revealed a vertical shift of 8 mm. of the right pubis. Radiographs of the sacro-iliac joints suggested undue widening of the left joint (Fig. 8).

#### Summary of Clinical Features of 10 Cases

Through the cooperation of obstetricians at the Maternity Department of Frere Hospital, I have examined 10 patients who had undergone this procedure. They were allowed out of bed usually on the 3rd or 4th day and were discharged from hospital between the 7th and 12th day.

Two patients were seen and examined within a few days of the operation. Both had symphyseal pain and were crippled.

Six of the others still complained of pain, either in the the back or pubis or both, although a year or two had elapsed since the operation. In 3 patients tenderness was still present over the symphysis pubis or sacro-iliac joints. Two had a slight limp.

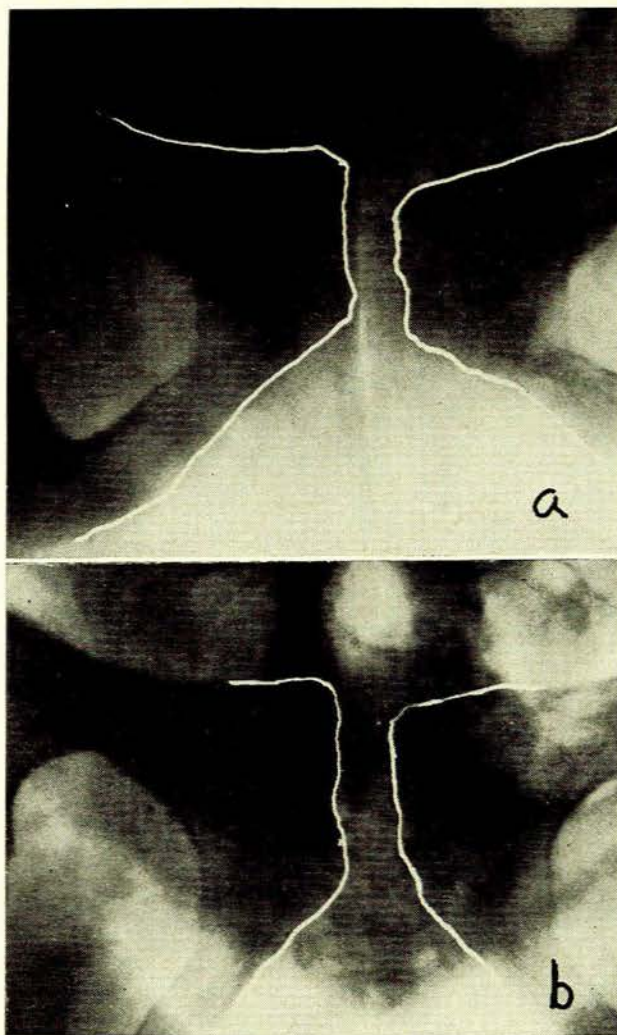


Fig. 8a. Vertical shift of right pubis (8 mm.). 8b. Excessive widening of left sacro-iliac joint.

Radiographs of all 10 patients revealed wide separation of the symphysis pubis. Chamberlain's test was positive in each case.

#### DISCUSSION

The arch of the pelvis is not a rigid structure and any disruption of the tie-beam of the arch must result in instability of the keystone. In consequence, the ligaments surrounding the sacro-iliac joints are overstretched and strained. In an attempt to correct the instability, there is over-action of the muscles attached to the pelvic girdle, resulting in muscle fatigue. It is therefore not surprising that pain is experienced.

If sound obstetrical reasoning dictates that symphyseotomy be undertaken, the pelvis must be firmly supported, the muscle tone maintained and improved by exercises, and ambulation not encouraged too soon postoperatively, for the stability and dynamics of the pelvis have been severely interfered with and these should be restored or at least minimized as soon as possible to prevent the inevitable consequences which instability brings in its wake.

#### SUMMARY

The factors responsible for backache in pregnancy and in the puerperium are outlined. The hormone relaxin is responsible for relaxation of the pelvic ligaments.

Pelvic arthropathy is due to excessive relaxation of the pelvic ligaments, causing pain in the sacro-iliac and symphyseal

joints during pregnancy or in the puerperium. The clinical features and radiological appearances are described. The case histories of 5 patients are given. The indications for symphyseotomy are outlined and the clinical and radiological effects of the operation on 11 patients are discussed.

#### REFERENCES

1. Young, J. (1940): *J. Obstet. Gynaec. Brit. Emp.*, **47**, 493.
2. Greenhill, J. P. (1965): *Obstetrics*, pp. 182 and 245. Philadelphia: W. B. Saunders.
3. Cunningham, D. J. (1931): *Cunningham's Text-Book of Anatomy*, p. 348. London: Oxford University Press.
4. Slate, W. G. (1960): *Obstet. and Gynec.*, **16**, 626.
5. Chamberlain, W. E. (1930): *Amer. J. Roentgenol.*, **24**, 621.
6. Clark, K. C. (1962): *Positioning in Radiography*, p. 127. London: Heinemann.