

LINGUAL THYROID: A REPORT OF THREE CASES AND DISCUSSION*

J. F. JARVIS, M.B., B.S. (LOND.), PH.D. (CAPE TOWN), M.R.C.P. (LOND.), F.R.C.S. (ENG.), D.L.O. (LOND.), D.T.M. & H., *Department of Otorhinolaryngology, Groote Schuur Hospital and University of Cape Town*

Three examples of aberrant thyroid in the posterior part of the tongue have been encountered at Groote Schuur Hospital, Cape Town, during the past 6 years, and identified in each case by the radio-iodine scanning technique. All of these cases are in young women, and radio-iodine scans prove that no functioning thyroid tissue is present in the neck in the normal position of the gland.

During this same period about 5 other lingual swellings were subjected to ¹³¹I scanning but were shown not to contain functioning thyroid.

Approximately 500 cases of thyroid disease are seen at this hospital each year, of which about 300 come to surgical operation.

CASE HISTORIES

Case 1

An unmarried girl of 19 years consulted a colleague on account of frequent attacks of sore throat. On subsequent questioning she admitted to an occasional feeling of a lump in the throat when she was 'nervous'. Examination showed a midline spherical swelling in the posterior third of the tongue, 2 cm. in diameter. At one point it showed a thin, bluish area 5 mm. in diameter, suggesting a cyst. No thyroid gland could be palpated in the neck. Radio-iodine scanning showed the tumour to be active thyroid tissue with no thyroid present in the neck. In view of the minimal symptoms, it was decided to watch progress and interfere only if symptoms became more marked.

Case 2

An unmarried woman of 24 was admitted under the care of Prof. J. H. Louw. Her complaint was dysphagia of 1 year's duration, some voice changes, and haemorrhage into the mouth a few days before admission. This continued, until admission, to such a degree that the haemoglobin fell to 9 G/100 ml., necessitating pre-operative transfusion. There was a tumour 3 × 2 × 1.5 cm. in the base of the tongue, and a second tumour, 2 cm. in diameter, over the hyoid bone. Radio-iodine uptake showed activity in the lingual swelling but none in the hyoid area in the neck. The lingual swelling was removed in February 1964 by Mr. W. M. Roberts, by the oral route, and the

hyoid mass by a collar incision in the neck. Bleeding from the oral incision was troublesome after operation. Pre-operative and postoperative blood replacement totalled 4 pints. Subsequent recovery was uneventful and the patient was discharged on thyroxin replacement therapy.

Histology of the lingual nodule showed normal but rather hyperactive thyroid tissue. The hyoid nodule was a mixed foetal adenoma with a normal thyroid. Fibrous trabeculae and foreign-body giant cells were noted.

The patient was recalled for examination 3½ years after the operation. The tongue showed no trace of the original swelling, and in fact the operation scar was hardly visible. She did not complain of any symptoms, but on questioning and examination was clearly myxoedematous. It then transpired that she had not continued to take the thyroxin that had been prescribed. She was referred to the Endocrine Unit for reassessment and treatment.

Case 3

This unmarried girl, aged 19, had no symptoms, and a tumour at the base of the tongue was discovered accidentally. Radio-iodine studies confirmed that this was active thyroid tissue and that no thyroid was present in the normal position. In view of the absence of symptoms at the time (June 1966), no treatment was advised.

On re-examination in August 1967 no change was found, and the decision to withhold active treatment was confirmed. The future prospects were frankly discussed with the patient and she was advised to return for further consultation should the question of pregnancy arise.

INCIDENCE

The first case to be described is usually attributed to Hunt¹ who, however, did not appear to appreciate the true nature of the tumour he observed. His account of the operation makes most alarming reading by modern standards, and the fact that the patient died a few days later, apparently from cerebral damage consequent on respiratory obstruction relieved too late by laryngotomy, is not surprising.

Hickman² was probably the first to describe and recognize the condition correctly. Montgomery³ was able to collect records of 144 cases that fulfilled the criteria that

*Date received: 11 January 1968.

had been laid down. These criteria were: the presence of a midline tumour in the base of the tongue between the epiglottis and the foramen caecum, which was shown on biopsy to be thyroid tissue, or, in the absence of histological proof, the demonstration that myxoedema supervened after the tumour had been excised. Buckman⁴ has also made an extensive review in which he cites 236 references and lists the main feature of 242 cases. Many records of other cases have been published since these 2 classical reviews, and the frequency of the condition has variously been reported as 1 case in every 2,500 - 4,000 cases of thyroid disease. Schilling *et al.*⁵ found one case among 244,000 general hospital admissions, 11,900 autopsies and 4,200 cases of thyroid disease. Bronson⁶ quotes Clute as having seen 2 lingual thyroids among 8,500 cases of thyroid disease.

It is a condition, as with thyroid diseases generally, that affects predominantly the female sex. In Buckman's⁴ series he found 173 females, 28 males and 41 whose sex was unrecorded, an incidence of a little over 6:1. Other authors have given 3:1 and 8:1, and of the other cases published the great majority have been females.

The commonest ages at which symptoms are first noted are in childhood, at puberty and in the young adult, pregnancy often causing the tumour to enlarge and become apparent. However, a large tumour caused death in a neonate,² or remained unobserved until the age of 63 in a woman with a normal neck thyroid who noticed its enlargement after being treated with androgens for carcinoma of the breast.⁷

EMBRYOLOGY

There has been much discussion about the development of the thyroid gland. All agree that an anlage appears at the 2.5-mm. embryo stage in the situation which later becomes the foramen caecum at the junction of the anterior two-thirds and posterior third of the tongue. This grows down the neck as the thyroglossal duct which forms the main part of the thyroid gland; remnants of the duct, if persisting, may give rise to thyroglossal cysts. It had also been claimed that further elements are contributed by portions arising from the 4th branchial pouches, as stated by Walton,⁸ which later fuse with the main gland. Others feel that these portions normally atrophy and have no part in the definitive thyroid gland. However, detached lateral masses of thyroid tissue are occasionally found in the neck, about once in every 1,000 goitre operations according to Schwartz,⁹ but Hendrick¹⁰ claims that these masses are really metastases in glands from a papillary carcinoma of the thyroid itself. Since no gland can be found in the neck in at least 70% of cases of lingual thyroid, it would appear that the 4th pouch element does not usually make any contribution to the gland, but the occasional presence of lateral thyroid nodules might suggest that the 4th pouch anlage may at times persist in a functional form.

The lingual thyroid represents a normally originating gland that has failed to migrate in the usual manner. It may descend partially and be found under the tongue in the hyoid region. Hendrick¹⁰ found 5 lingual and 5 sublingual thyroids among 1,309 thyroid operations, and Gruber¹¹ reported finding ectopic thyroid tissue in one site or another in 10% of routine autopsies.

Goetsch¹² found tissue present resembling parathyroid gland on section in one of his cases, and Asch¹³ reported the development of tetany after excision of a lingual thyroid. Goetsch¹² concedes, however, that the histological differentiation between foetal adenoma and parathyroid may be difficult. On embryological grounds it is difficult to see how parathyroid tissue could become incorporated into a lingual thyroid, on account of the known development of the parathyroid glands from the 3rd and 4th branchial pouches.

MORBID ANATOMY

An excellent colour picture of a typical lingual thyroid can be seen in the paper by Wapshaw.¹⁴ It usually presents as a roughly hemispherical tumour 2-4 cm. in diameter in the midline of the posterior third of the tongue. Its volume is probably rather less than that occupied by a normal thyroid gland, and when physiological demands require it to enlarge, it has a more restricted space in which to swell. Where normal thyroid is also present in the neck, the tumour is usually about 1 cm. in diameter and the need for hypertrophy is not present to the same degree. Accordingly, such cases are often discovered only later in life. Many workers report that palpation of the neck has failed to show a normally placed gland, but the fact that in the days before the availability of radio-iodine scanning, surgeons often deliberately explored the neck before removing a lingual thyroid, is sufficient indication that palpation is not a reliable method of detecting the presence of a normal gland.

HISTOLOGY

All the pictures found in the normal thyroid may be found in the lingual thyroid: normal gland, foetal adenoma, colloid goitre, toxic goitre, cystic degeneration and malignant change. As in the thyroid generally, the histological diagnosis of malignancy is not easy, and Wapshaw¹⁴ has reported a case where the excised tissue was histologically cancerous yet the subsequent course was benign.

Cases have been reported where radio-iodine studies suggested the absence of functioning thyroid in a lingual nodule, yet where, on section, normal thyroid tissue has been demonstrated. This has an important bearing on the evaluation of the viability of autotransplants by the use of radio-iodine scanning.¹⁵

DIFFERENTIAL DIAGNOSIS

Since radio-isotope scanning has become available, the problem of diagnosis of swellings at the base of the tongue has been greatly facilitated. Other lesions that might be confused with a lingual thyroid include thyroglossal cysts, angioma, lymphangioma, gumma, fibroma and lipoma. Of the malignant growths, carcinoma of the tongue is a possibility, although uncommon in this position, and lymphosarcoma of the lingual tonsil might cause confusion. The removal of specimens for biopsy, with the risk of haemorrhage, is not indicated if radio-iodine studies are available.

CLINICAL FEATURES

The age and sex incidence has already been discussed. Some cases are without symptoms, but commonly voice

changes, choking attacks, dyspnoea and dysphagia are caused. These symptoms are often accentuated by physiological enlargement of the gland at puberty or during pregnancy. Haemorrhage has been a serious complication in a number of reported cases as well as in the second case described in this paper.

Baker and Szanto¹⁶ describe a middle-aged male patient who died of unexplained gastro-intestinal haemorrhage and who was found at autopsy to have a 4-cm. lingual thyroid from which the bleeding had come. Schilling *et al.*⁵ describe a female patient of 30 years who bled from a lingual thyroid during her pregnancies, and Mill *et al.*¹⁷ report a female aged 24 who first noticed the tumour during pregnancy. This patient bled during each of her 3 pregnancies.

Sicher¹⁸ reported the case of a female aged 30 who needed transfusion of 3 pints of blood when she was admitted for haematemesis when 6 months pregnant. The cause was not discovered at that time, but when she had further bleeding 6 months later, a tumour 2.5 cm. in diameter was found in the posterior third of the tongue, with dilated veins running over its surface. Radio-iodine studies confirmed that all active thyroid tissue was located in the tumour. Five mc of ¹³¹I caused no change, and 4 months later 20 mc were given. This caused the tumour to enlarge and further bleeding occurred. The tumour was later satisfactorily removed by the oral route. Two months after operation the basal metabolic rate (BMR) was -38% and thyroid replacement therapy was instituted.

Carcinomatous change in a lingual thyroid is not common. In some female patients it has been reported on histological grounds, but the subsequent course has almost always been that of a benign condition. Mill *et al.*¹⁷ were able to collect 15 cases reported between 1910 and 1958. Of these, 8 were female and 7 male. They added that the prognosis in these female cases seemed much better than in the males.

The true incidence of malignant change is not easy to assess. Cases where cancer has supervened are more likely to be reported than when the lesion remains benign. From the experience of various clinics, it would appear that, as observed by Bishop,¹⁹ many more cases of lingual thyroid exist than have been reported in the literature. As a guess it might be found that 1 out of 100 cases becomes malignant. Since the sex incidence in reported malignancies is approximately equal and the sex ratio of all cases is about 7 females to 1 male, we can say with certainty that the risk of malignancy is many times greater in the male, more so as the majority of the female cases so diagnosed histologically appear to run a benign course.

INVESTIGATION

Radio-iodine scans are mandatory in all tumours in this region and have made neck exploration and biopsy obsolete. One of the earliest accounts of the use of ¹³¹I employing a Geiger-Muller collimated tube is given by Feitelberg *et al.*,²⁰ who were able in this way to prove a tumour in the tongue to be the only active thyroid in a woman of 20.

The radioactive isotope of iodine, ¹³¹I, has a half-life of about 8 days and emits beta and gamma radiation. The

test dose of 0.6-1.0 μ C/lb. body-weight is given to the patient to drink.²¹ At first, radioactivity is found in the body generally, but after 24 hours a large proportion is

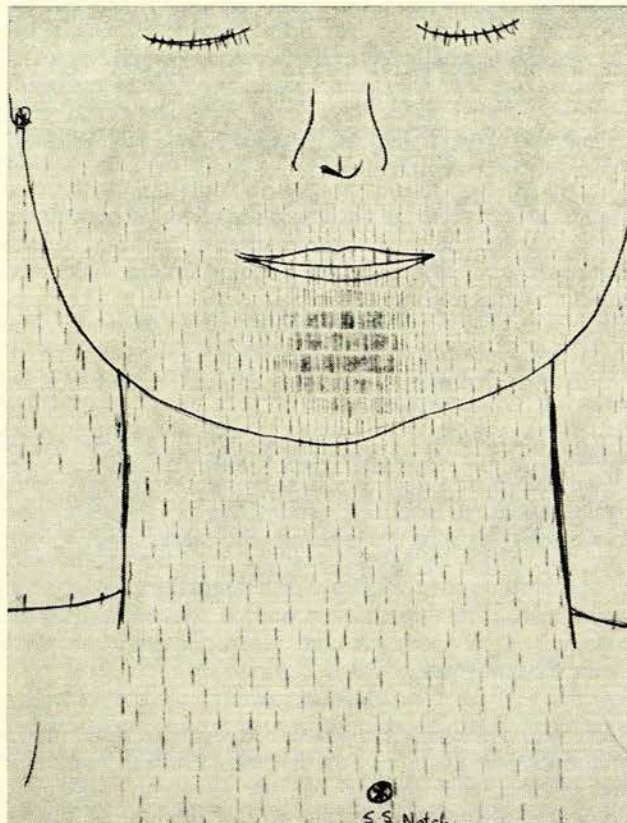


Fig. 1. Typical scanning result in a case of lingual thyroid.

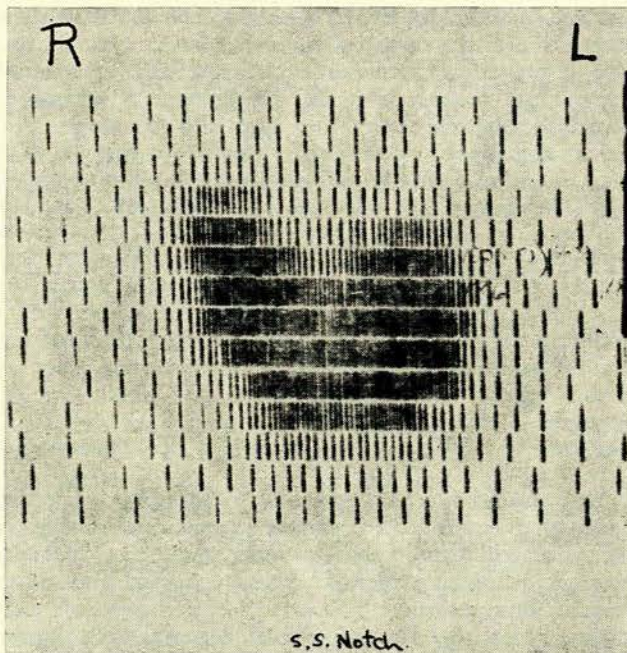


Fig. 2. Scanning of gland normally situated in the neck.

concentrated in the thyroid gland where its presence and concentration are detected by a Geiger counter and plotted on a chart. Fig. 1 is a typical scanning result in a case of lingual thyroid, while Fig. 2 shows the picture obtained from a gland normally situated in the neck.

This dose is small and apparently harmless; to destroy the gland, the dose has to be increased to the millicurie range. Crispell and Parsons²² employed radio-iodine for both diagnosis and treatment in one case. A small decrease in size of the tumour was observed 4 months after 6.8 mc with some symptomatic relief.

Wible and Freeman²³ report on 3 cases diagnosed by scans. In one the tumour had been removed by the oral route, but 4 months after operation the ¹³¹I investigation showed remnants to be present at the site of operation. In one of their cases a therapeutic dose produced a shrinkage of the lingual tumour. Timmons and Timmons,²⁴ Alhadefi,²⁵ Nachman *et al.*,²⁶ and Zaslou *et al.*²⁷ all report the use of ¹³¹I in diagnosis of lingual thyroid.

TREATMENT

Expectant treatment is indicated where no symptoms of note are being caused in a female, although it is important to bear in mind that trouble may be experienced at subsequent puberty or during future pregnancies. In the male, however, the higher incidence of carcinomatous change of bad prognosis would suggest that total excision should always be advised.

Surgical treatment. Removal may be complete or partial and may be achieved via the mouth or through a median or lateral pharyngotomy. The advantages of pharyngotomy are the better control of bleeding, and the possibility of removing the mass without opening the oral cavity. The tumour is normally sessile with a portion buried in the substance of the tongue, but Bishop²⁸ reports the unusual finding of a pedunculated mass that he was able to remove with a snare.

Partial removal was advised formerly in the hope of preserving some useful thyroid function, but it is condemned by most modern authors. Dietrich and Schall²⁹ condemn partial excision but consider that removal by the oral route is satisfactory unless the tumour is very large. After excision, two possibilities are open to the surgeon: he may accept the inevitable myxoedema if no other thyroid is present, or he may consider auto-transplantation of the excised thyroid in the hope that it will continue to function, rendering the patient euthyroid or requiring a reduced dose of replacement therapy.

Stone *et al.*²⁹ undertook a study in which they were able successfully to implant homografts of parathyroid and thyroid tissue in dogs. They subsequently reported the relief of tetany in 3 patients by homografts of parathyroid tissue and one partially successful thyroid graft. They also had failure in several other thyroid cases. They advised implantation into axilla or groin to avoid the pressure that might be exerted on the graft implanted into a muscle, and, to minimize reaction by the host, they cultured their graft material for some weeks in host serum.

Several other authors have published the results of implantation of thin slices or small cubes of the excised lingual thyroid into the rectus abdominis muscles. Radio-isotope scanning has enabled them to study subsequent

function in the implants. Jones³⁰ removed a tumour from a girl of 9 years and implanted 150 cu.mm. in small pieces into the rectus abdominis. Temporarily hypothyroid, the patient ultimately became almost euthyroid. Swan *et al.*,³¹ in a girl of 9, found that their implants showed no radio-iodine uptake at first, but function was present 6 months later, and at 9 months 20% of the ¹³¹I was taken up in the grafts. On giving thyroid by mouth, function was greatly depressed, but recovered on cessation of the hormone. Wapshaw³² had the interesting experience of implanting tissue into the rectus and finding that on histological examination the gland was reported as carcinomatous. However, the subsequent course was benign, although the patient developed myxoedema. Swan *et al.*³¹ had one partly successful implant, and in another female, aged 7, the graft was functional 4 months later but not enough to keep the patient euthyroid. However, 2 years later the function became normal, only to regress again as the child grew.

Lawson³² implanted excised tissue from a lingual thyroid into the rectus abdominis in an 11-year-old girl. One year later the patient was euthyroid, although ¹³¹I scan had shown that this was the only functional tissue. He has since reported³³ that the patient is married, with one normal child, and remains euthyroid. At puberty the patient had some tenderness in the abdominal scar during menstruation, and a thickening had been reported at the site of the implant during her pregnancy. Three months after the birth of her child this could no longer be felt.

In review, therefore, it appears that auto-implantation of the excised lingual thyroid is worth a trial where no normal thyroid exists. A few patients may become euthyroid, at least until the heavy demands of puberty and pregnancy; others will have grafts that survive, albeit inadequately to meet the patient's needs; others will fail. Hormonal replacement by oral administration is so simple that it may be felt that the extra disturbance to the patient is not worth the problematical benefit likely to result. In view of the higher risk of malignant change, auto-implantation is strongly contraindicated in the male subject.

RADIOTHERAPY

The facility with which radioactive iodine is concentrated in the thyroid gland makes possible the selective irradiation of thyroid tissue in a manner almost unique in the human body. By giving radio-iodine by mouth in doses much larger than those used for diagnostic scanning, thyroid tissue may be destroyed. The patient described by Mill *et al.*¹⁷ showed cancerous change in a lingual thyroid during her third pregnancy. A therapeutic dose of ¹³¹I caused rapid shrinkage of the tumour and no subsequent uptake of a tracer dose. Schilling *et al.*³ treated a female, aged 30, with radio-iodine, causing a 4-cm. diameter lingual mass to shrink to 1.5 cm. in 3 years with development of myxoedema. Waggoner³⁴ treated an intralaryngeal aberrant thyroid which was histologically cancerous, in a 19-year-old female, by radio-iodine.

Radio-iodine therapy is clearly effective but leaves a small residual mass. Only a long-term study will show if there is an enhanced risk of cancerous change in later years. Other forms of radiotherapy have been tried. Bronson⁶ gave 3,360 rads to the tumour, with only slight

reduction, in the case of a female aged 39 years. Five months later radon seeds were implanted, which caused sloughing and necrosis. At a subsequent excision severe haemorrhage complicated the postoperative course. Auto-transplants of apparently normal parts of the tumour sloughed. The patient was left with mild myxoedema.

HORMONAL SUPPRESSIVE THERAPY

Any endocrine gland tends to atrophy if very large doses of its own hormone are supplied to the patient artificially. Alhadeff²⁵ treated a female, aged 32, who had a 2-cm. diameter lingual thyroid, with l-thyroxine plus iodized salt, with reduction of the swelling. Moreover, enlargement of the mass at puberty and during pregnancy may be partially controlled by the administration of iodine as in the case of the ordinary colloid goitre. Thyroxine suppression offers an alternative therapy for lingual thyroid, leading, of course, to the ultimate need to maintain therapy at a reduced dosage indefinitely.

SUMMARY

Three cases of lingual thyroid in young females are described. In each case ¹³¹I scans proved these tumours to be the only functioning thyroid. Excision, with subsequent myxoedema, was performed in one case; and the other two, having minimal symptoms, are being observed. The incidence of this condition is reviewed, the female: male ratio being about 7:1. Symptoms include dysphonia, dysphagia and respiratory obstruction. Haemorrhage during pregnancies is a frequent and serious complication. Malignant change is much more common in the male and has a worse prognosis than in the female. The tumour tends to enlarge at puberty and during pregnancy, and is most often diagnosed during the early part of life, but may give symptoms for the first time at any age.

Surgical excision is the treatment of choice where symptoms are marked, and some success has been obtained in auto-implantation of the excised tissue into other sites in the body, a few cases remaining euthyroid after the procedure. The tumour has also been made to regress by radio-iodine in larger doses or by the administration of thyroxine.

I should like to thank Prof. J. H. Louw and Mr. E. B. Malherbe for permission to include their cases in this survey. The first case was kindly referred to me by Dr. A. J. P. Snyman, of East London. The Radio-isotope Unit at Groote Schuur Hospital undertook the scans and kindly made their records and Figs. 1 and 2 available. I also wish to thank Dr. J. G. Burger, Medical Superintendent of Groote Schuur Hospital, for permission to publish.

REFERENCES

- Hunt, W. (1866): *Amer. J. Med. Sci.*, **51**, 163.
- Hickman, W. (1869): *Trans. Path. Soc. Lond.*, **20**, 160.
- Montgomery, M. L. (1936): *West. J. Surg.*, **44**, 54.
- Buckman, L. T. (1936): *Laryngoscope (St. Louis)*, **46**, 765.
- Schilling, J. A., Karr, J. W. and Hursh, J. B. (1950): *Surgery*, **27**, 130.
- Bronson, S. R. (1938): *Arch. Surg.*, **37**, 316.
- Turcot, J. (1962): *Amer. J. Surg.*, **104**, 677.
- Walton, Sir James in Turner, G., ed. (1943): *Modern Operative Surgery*, 3rd ed., p. 1748. London: Cassell.
- Schwartz, H. W. (1953): *J. Laryng.*, **67**, 417.
- Hendrick, J. W. (1956): *Surgery*, **39**, 297.
- Gruber, W. (1876): *Virchows Arch. path. Anat.*, **66**, 447.
- Goetsch, E. (1948): *Ann. Surg.*, **127**, 291.
- Asch, R. (1914): *Dtsch. Z. Chir.*, **130**, 593.
- Wapshaw, H. (1942): *Brit. J. Surg.*, **30**, 160.
- Swan, H., Harper, F. and Christensen, S. P. (1952): *Surgery*, **32**, 293.
- Baker, R. J. and Szanto, F. B. (1961): *Ann. Surg.*, **153**, 310.
- Mill, W. A., Gowing, N. F. C., Reeves, B. and Smithers, D. W. (1959): *Lancet*, **1**, 76.
- Sicher, K. (1953): *Brit. Med. J.*, **2**, 186.
- Bishop, F. J. (1934): *Ann. Otol. (St. Louis)*, **43**, 294.
- Feitelberg, S., Kaunitz, P., Wasserman, L. and Yohalem, S. (1948): *Amer. J. Med. Sci.*, **216**, 129.
- Harrill, J. A., Whitley, J. E., Meschan, I. and Winston-Salem, N. C. (1959): *Ann. Otol. (St. Louis)*, **68**, 109.
- Crispell, K. R. and Parsons, W. (1950): *Sth. Med. J. (Bgham, Ala.)*, **43**, 945.
- Wible, L. E. and Freeman, G. R. (1962): *Arch. Otolaryng.*, **75**, 168.
- Timmons, J. R. and Timmons, J. M. (1951): *Ann. Surg.*, **133**, 90.
- Alhadeff, R. (1954): *Proc. Roy. Soc. Med.*, **47**, 510.
- Nachman, H. M., Crawford, V. and Bigger, I. A. (1949): *J. Amer. Med. Assoc.*, **140**, 1154.
- Zaslow, J., Sklaroff, D. M. and Kornfield, H. (1954): *Ibid.*, **155**, 359.
- Dietrich, H. J. and Schall, L. A. (1952): *Ann. Otol. (St. Louis)*, **61**, 395.
- Stone, H. B., Owings, J. and Gey, G. (1935): *Surg. Gynec. Obstet.*, **60**, 390.
- Jones, P. (1961): *Arch. Dis. Childh.*, **36**, 164.
- Swan, H., Jenkins, D. and MacGregor, C. (1958): *Arch. Surg.*, **76**, 458.
- Lawson, R. S. (1957): *Aust. N.Z. J. Surg.*, **26**, 241.
- Idem* (1967): Personal communication.
- Waggoner, L. G. (1958): *Ann. Otol. (St. Louis)*, **67**, 61.