

HAEMANGIOMA OF THE PLACENTA

J. ADNO, M.B., B.CH., DIP. O. & G. (RAND), *Obstetrician and Gynaecologist, Johannesburg, and Department of Obstetrics and Gynaecology, University of the Witwatersrand*

The commonest benign tumour occurring in the placenta, is the haemangioma.⁷ The exact incidence varies in different reports, and comprehensive reviews have already been written by Siddal,⁶ Marchetti,⁸ DeCosta *et al.*,¹ Shaw-Dunn⁵ and Wentworth.⁷ These reviews, however, represent only a small series of cases and, as the clinical significance of this tumour is still unexplained, it was thought pertinent to report two further cases of haemangioma of the placenta — especially as both cases were associated with another mysterious obstetrical condition, namely hydramnios.

CASE REPORTS

Case 1

This patient was seen during her first pregnancy at the fifteenth week of gestation. She was 28 years of age. The previous history was not contributory. The pregnancy progressed favourably until the 32nd week, when the patient complained of sudden enlargement of her abdomen and also gross swelling of both her lower limbs. This was also associated with some breathlessness.

On examination: BP 120/100 mm.Hg. Haemoglobin 12 G/100 ml. The urine was clear. Her girth at that stage was 42 inches, and the size of the uterus had enlarged dramatically since her previous antenatal visit. Hydramnios was diagnosed. An X-ray of the abdomen showed a normal foetal skeleton. She had gained 15½ lb. in weight over a period of 4 weeks. She was given an oral diuretic and put on to a salt-free diet.

Two days later, the girth had reduced to 41 inches and she seemed to be a little more comfortable. Blood pressure was 110/90 mm.Hg. The weight had come down by 4 lb. Eight days later there was slight albuminuria. Weight again rose by 4 lb., the girth was 41½ inches. BP 120/80 mm.Hg. Four days later, the girth had come down to 40 inches, but 4 days after this it had gone up again to 41½ inches. After 2½ weeks, the weight had come down to the previously normal weight of 145½ lb., and the girth to 38½ inches. The patient was feeling much more comfortable, and the oedema of the feet had diminished and there was no further breathlessness. The girth remained at 38½ inches until she delivered, which was on her due date.

The patient was admitted in fair labour. The membranes ruptured during the second stage, and the liquor was heavily stained with meconium. The heart beat, however, was normal. A low forceps extraction was done, and a female infant weighing 7 lb. 13 oz. was born. There was no asphyxia and the infant cried immediately. No congenital defects were noted.

The placenta was delivered normally, and at the base of the insertion of the cord, and involving this area, was an obvious swelling about 2½ inches in diameter. On the maternal side, this area was covered with old, brownish clots, and this resembled an old haemorrhage (Fig. 1). On sectioning the area of the tumour, it was found to be the size of a tennis ball, consisting mainly of old necrotic material and blood clot. It seemed to be involving the area of the base of the umbilical cord.

On microscopical examination the picture was that of a haemangioma of the placenta.

Postpartum and neonatal periods for both mother and child were absolutely normal.

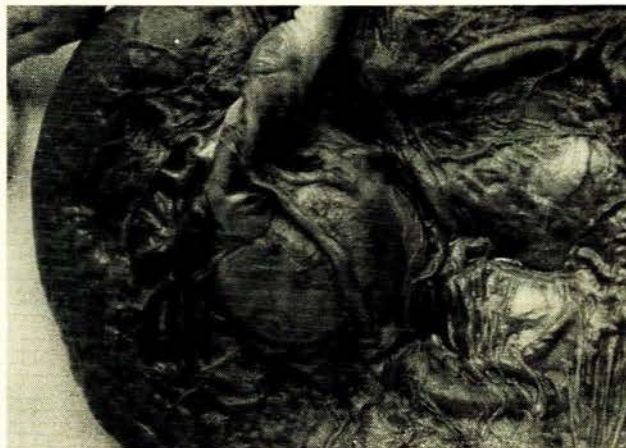

Fig. 1. Foetal surface of the placenta showing the haemangioma adjacent to and involving the umbilical cord.

Case 2

Case no. 2 was a para 2, gravida 3, aged 22 years. Her two previous confinements were absolutely normal. She was first seen at 9 weeks of her pregnancy. There was nil of note in her history, and everything on examination was normal. This patient and her pregnancy progressed normally until the 31st week of her pregnancy, when the size of the uterus seemed to be very much larger than her period of amenorrhoea. At that stage it was thought that a twin pregnancy might be the cause

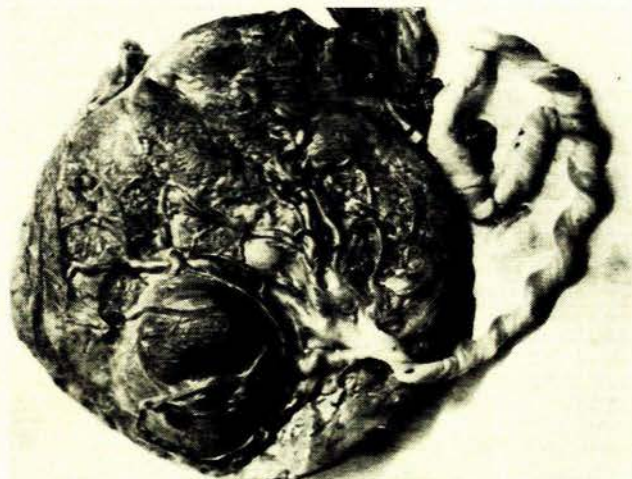


Fig. 2. Foetal surface of the placenta with bulging haemangioma.

of this. Towards term, however, the uterus definitely enlarged abnormally, so much so, that she developed an area of anaesthesia and paraesthesia over the right side of the anterior abdominal wall.

Hydramnios was diagnosed. There were no other signs or symptoms, such as excess weight gain, oedema of the feet, albuminuria or hypertension. The patient was treated conservatively and she commenced labour spontaneously. After a short labour she delivered a healthy female child, weighing 7 lb. 10 oz. The liquor, however, was meconium-stained, but at no stage was there any foetal distress. No congenital defects of the child were noted.

The placenta followed normally, and on the foetal surface there was a large swelling which occupied the area from the edge of the placenta to within 1-1½ inches of the insertion of the cord (Figs. 2 and 3).

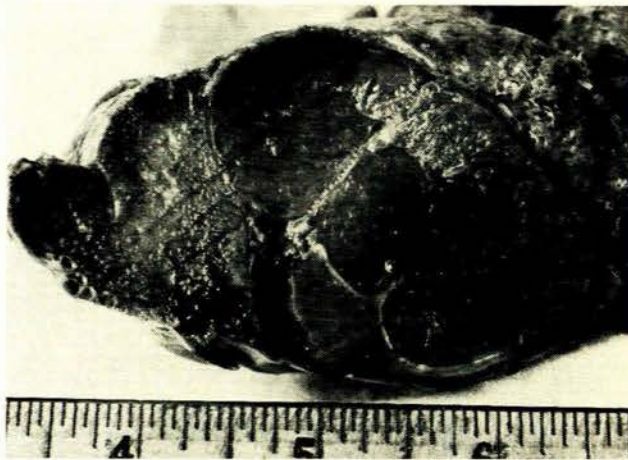

Fig. 3. Cross-section of haemangioma.

The placenta was large and measured 8 x 8 inches; it was 2 inches in its thickest part and weighed 2 lb. 5 oz. There was a tumour mass present in the placenta, which could almost be shelled out from the placental tissue. It measured 2½ x 3 x 2 inches. There were occasional small infarcts present in the maternal surface of the placenta. Sections of the placental tumour showed the presence of a capillary haemangioma. Most of this tumour was necrotic, and there was also an area of haemorrhage in this.

Postpartum and neonatal periods were absolutely normal.

DISCUSSION

These 2 cases represent an incidence of 2 in 1,200 obstetrical deliveries. The incidence varies greatly, and Table I shows this gross discrepancy. The reason for this variability in the incidence is most probably due to the fact that the tumours are easily missed on cursory examination of the placenta.

TABLE I. INCIDENCE OF HAEMANGIOMATA

Author	Number of placenta examined	Incidence of haemangiomata
Siddal (1924)	600	1 in 100
Kühnel (1933)	72,000	1 in 9,000
Traut and Kuder (1934)	1,500	1 in 500
Marchetti (1939)	20,000	1 in 3,500
Novak (1952)	Not stated	1 in 700
Shaw-Dunn (1959)	500	1 in 72
Benirschke (1962)	Not stated	1 in 100
Wentworth (1965)	620	1 in 77
Adno (1966)	1,200	1 in 600

In Wentworth's series of 8 haemangiomas, only 2 tumours bulged the foetal surface of the placenta and were not recognized before sectioning. This illustrates how easily they can be missed by a superficial examination of the placenta.

In the present 2 cases both tumours bulged the foetal surface and both were easily recognizable as tumours, although the type of tumour could only be surmised.

Marchetti³ classified placental haemangiomas into 3 types; vascular, cellular and degenerative. Both the present cases reported, belong to the capillary type, but both were also associated with extensive areas of necrosis. Most probably the degenerative type of haemangioma is a result of necrosis, possibly due to some thrombotic phenomenon taking place in the tumour itself.

Siddal,⁵ DeCosta *et al.*¹ and Shaw-Dunn⁵ all state that hydramnios was a complication of placental haemangioma in about one-third of cases. Wentworth⁷ describes 1 case of hydramnios in his series of 8 cases. McInroy and Kelsey⁴ thought that blood which passed through a placental haemangioma would bypass the placental bed and so limit the removal of waste products and this would in turn call for increased foetal renal activity and secretion of foetal urine leading to hydramnios. Wentworth⁷ thought that it was also conceivable that this bypass effect, by limiting the passage of nutrients to the foetus, could account for the low birthweights in his cases. Gruenwald² mentions haemangiomas as a rare cause of placental insufficiency. He described a case where the entire placenta had been replaced by multiple haemangiomas and the full-term infant weighed only 2,894 G.

Hydramnios was a feature in both of the cases here reported. In case 1, the tumour definitely involved the base of the cord and almost certainly interfered with the circulation of the foetus. It is thought that the acute episode occurred with haemorrhage and necrosis and oedema surrounding the base of the cord, and when this had subsided the circulation was reinstated and so did the hydramnios recede.

The second case, however, was not so clear-cut, and the hydramnios could not be explained. It is difficult to accept this explanation of bypass where the base of the cord is not involved. It is often noted with grossly infarcted placentas, where there must be an even greater bypass, that oligohydramnios occurs in fact and not hydramnios. Some other factor must be looked for, and one might even postulate that the presence of the tumour may in fact irritate the immediate foetal membranes and thus stimulate the formation of excess liquor.

SUMMARY

Two cases of placental haemangiomas are described. The literature is reviewed. Hydramnios as a complication is also discussed.

Thanks are due to the Photographic Unit, Department of Medicine, University of the Witwatersrand, for the photographs. The histopathology was reported on by Dr. S. Shippel.

REFERENCES

1. DeCosta, E. J., Gerbie, A. B., Andresen, R. H. and Gallanis, T. C. (1956): *Obstet. and Gynec.*, 7, 249.
2. Gruenwald, P. (1963): *Biol. Neonat. (Basel)*, 5, 215.
3. Marchetti, A. A. (1939): *Surg. Gynec. Obstet.*, 68, 733.
4. McInroy, R. A. and Kelsey, H. A. (1954): *J. Path. Bact.*, 68, 519.
5. Shaw-Dunn, R. I. (1959): *J. Obstet. Gynaec. Brit. Emp.*, 66, 51.
6. Siddal, R. S. (1924): *Amer. J. Obstet. Gynec.*, 8, 430 and 554.
7. Wentworth, P. W. (1965): *J. Obstet. Gynaec. Brit. Emp.*, 72, 81.