

THIAMINE DEFICIENCY AND BERIBERI HEART DISEASE

BIOCHEMICAL AND CLINICAL INVESTIGATIONS

A. J. BRINK, M.D., A. LOCHNER, D.Sc., AND C. M. LEWIS, M.B., CH.B., *Department of Internal Medicine and the Degenerative Diseases Group of the Council for Scientific and Industrial Research, University of Stellenbosch Medical School, Karl Bremer Hospital, Bellville, Cape Province*

In 5% of a consecutive series of 2,033 Cape Coloured patients presenting with heart disease in the Western Cape, South Africa, we could discover no cause for the condition. A similar incidence of this form of heart disease in the same racial group was reported by Schrire.¹ Among the Bantu people in other parts of this country, heart disease of obscure origin is the most common cardiac condition and has, for example, accounted for 27% in one series² and 37% of all cases of heart disease in another series.³

It is recognized that malnutrition is common in both the Bantu and the Cape Coloured people. Their diets have a low fat and protein content and consist largely of carbohydrates. There is a high incidence of alcoholism among these people. Thiamine deficiency resulting in beriberi heart disease must, therefore, be considered as a likely causative or contributory factor for congestive cardiac failure in this country. In the course of our studies on patients with heart disease, it was thus found necessary to determine their thiamine status.

Although thiamine is one of the few vitamins which can be assayed microbiologically,⁴⁻⁶ chemically,⁷ chromatographically⁸ and biochemically,^{9,10} most of the techniques are cumbersome. In this study preference was given to the transketolase method of Wolfe *et al.*¹¹ and Brin *et al.*^{12,13} to determine the thiamine status.

Fifty-four consecutive patients admitted in congestive cardiac failure were screened for thiamine deficiency. Of these patients 2, who presented with heart disease of obscure origin and were shown to have a thiamine deficiency, had coronary sinus catheterization studies to determine myocardial blood flow and metabolism. One of the two had the acute form of beriberi known as Shoshin and the other was in a subacute phase of congestive cardiac failure.

METHODS

Transketolase Method for Determining Thiamine Status

Because the activity of the enzyme transketolase is dependent on the presence of its co-enzyme thiamine pyrophosphate, the activity of this enzyme complex is used as an index of thiamine adequacy.

In this assay blood was prepared as a haemolysate with a constant cell-to-volume ratio. Each sample was divided into 3 parts; one sample was incubated with ribose-5-phosphate, the second sample with the co-enzyme thiamine pyrophosphate followed by incubation with ribose-5-phosphate, while the third sample served as a control. After 1 hour the reaction was stopped with trichloroacetic acid and the protein-free filtrates examined for the amounts of pentose which had disappeared.

The increase in enzyme activity due to incubation of the haemolysate with thiamine pyrophosphate is expressed as a percentage of activity of the sample which was not

treated with thiamine pyrophosphate (TPP effect). In this study a TPP effect of 12% or more was considered to indicate a thiamine deficiency.

Cardiac Catheterization Procedures

These consisted of right heart catheterization and intubation of the coronary sinus. Blood samples for biochemical analyses were obtained from the arterial side via a catheter in the brachial artery or aorta and from the coronary sinus via the indwelling catheter. Pressures were recorded by means of a Statham strain-gauge P23D and a direct-writing Sanborn polygraph. The cardiac output was determined by the Fick principle and the coronary flow by the N:O technique of Kety and Schmidt,¹⁴ as modified by Eckenhoff *et al.*¹⁵ and applied by Bing *et al.*¹⁶

Oxygen and nitrous oxide volumes were determined by the method of Van Slyke and Neill.¹⁷ The left ventricular work, the mechanical efficiency and the myocardial consumption of oxygen and other substrates were calculated according to the method of Bing *et al.*¹⁶ The tension-time-index (TTI) per min. in mm.Hg/sec. was determined by the method of Sarnoff *et al.*¹⁸

Other Biochemical Analyses

Blood glucose, lactate and pyruvate were determined as follows: 3 ml. of blood drawn with a minimum amount of stasis was pipetted into 5 ml. 6% PCA and allowed to stand on ice for 10 minutes. After centrifuging, the supernatant fluid was drawn off and the analyses done as soon as possible. Glucose was assayed in the supernatant fluid by the glucose-oxidase method.¹⁹ The lactate content of the supernatant was determined by the enzymatic method²⁰ (UV-method with DPN), as modified by Opie *et al.*²¹ For the determination of pyruvate, 3 ml. of the perchlorate-free supernatant was neutralized with K₂HPO₄ (Ph-solution, TC-C kit, Boehringer and Soehne GmbH) to ca. pH7 and the pyruvate concentration of the buffered solution determined by the UV-method with DPNH.²² The free fatty acid concentration of the plasma was determined by the method of Dole and Meinertz.^{23*} Blood samples for this determination were collected before the patients had received any heparin, as this has been shown to affect the FFA levels.²⁴ Creatine phosphokinase and aldolase values of the blood were determined by UV-methods with DPNH, using Biochemica Boehringer kits. Inorganic phosphate was determined according to the method of Hiller.²⁵

CASE REPORTS

Of the 40 non-White patients presenting in congestive cardiac failure, 10 (25%) were found to have a thiamine

*The chemicals and enzymes for the determination of glucose, lactate and pyruvate were obtained from Boehringer and Soehne GmbH, Mannheim, Germany. Perchloric acid (60% Analar) was obtained from British Drug Houses, Ltd., Poole, England.

deficiency (Tables I and II). The pertinent details of these 10 patients are summarized as case reports. The 2 patients

TABLE I. THIAMINE STATUS (EXPRESSED AS TPP EFFECT) OF 54 PATIENTS IN CONGESTIVE CARDIAC FAILURE

Race	Total No. of patients	Male	No. of males with TPP effect >12%	Females	No. of females with TPP effect >12%	Total No. with TPP effect >12%
White	14	10	0	4	0	0
Non-White	40	18	5	22	5	10
Total	54	28	5	26	5	10

TABLE II. SUMMARY OF PATIENTS IN CONGESTIVE CARDIAC FAILURE WITH ASSOCIATED INCREASE IN TPP EFFECT

Patient	Race	Age	Sex	Clinical diagnosis	% TPP effect
1	Bantu	67	M	?Hypertensive, hemiparesis	20.1
2	Cape Col.	33	F	Hypertensive, hemiparesis	25.1
3	Bantu	43	M	Beriberi with jaundice and pellagra	29.0
4	Cape Col.	60	F	Hyperthyroidism, jaundice	17.7
5	Cape Col.	27	F	?Tricuspid valve disease	31.3
6	Cape Col.	61	M	Aortic incompetence, peripheral neuritis	22.7
7	Cape Col.	61	M	Chronic renal failure	14.1
8	Cape Col.	21	F	Chronic rheumatic heart disease and pregnancy	16.8
9	Bantu	24	M	Acute beriberi	89.4
10	Cape Col.	35	F	Sub-acute beriberi	13.3

(Nos. 9 and 10) who appeared to have beriberi heart disease unassociated with any other pathological change in the heart and who were also subjected to special myocardial metabolic studies, are described in greater detail than the others.

In the cases to be reported, the thiamine status was only appreciated when the TPP effect on transketolase activity was determined in the laboratory, usually some days after the blood specimens had been collected, following the admission of the patient. No patient, therefore, had specific thiamine supplements. All were treated for congestive cardiac failure by means of digitalization, salt restriction and the use of oral diuretics. They received a balanced diet in hospital and were given mixed vitamin supplements as a routine. The more usual laboratory investigations are set out in Table III for each patient and are not repeated in the case reports.

Case 1

J.C., Bantu male, aged 67 years. This patient had a slight right-sided hemiplegia, had no one to care for him and had very little to eat for some time. Progressive dyspnoea leading to orthopnoea, developed over a period of 4 months. He had swelling of the ankles and a pleuritic type of pain in the right chest for 3 weeks.

On examination he was markedly orthopnoeic, his heart rate was 112/min. and his blood pressure 210/130 mm.Hg. The jugular venous pressure was elevated, the liver was palpable and there was slight oedema of the ankles. The maximal cardiac impulse was in the 6th interspace outside the mid-clavicular line, and a gallop rhythm was noted. Scattered ronchi and bilateral basal crepitations were present in the lungs. There was an area of bronchial breathing at the right lung base. A right-sided hemiparesis completed the clinical picture.

The electrocardiogram showed diffuse T wave changes with inversion from lead V₁ through V₆ with flattening of the T wave in V₆. Radiographic examination of the chest showed cardiac enlargement and congestion of both lung fields. In this patient the TPP effect on transketolase activity was 20.1%.

The patient responded well to treatment. During the course of a few days his blood pressure came down to 160/90 mm.Hg and then to 140/80 mm.Hg and he was discharged 2½ weeks after admission. The final clinical diagnosis was one of beriberi in a patient mildly hypertensive and probably atherosclerotic.

TABLE III. LABORATORY INVESTIGATIONS IN 10 PATIENTS WITH INCREASED TPP EFFECT

Case	Haematology			Serum chemistry			Liver function			Serology			Urinalysis										
	Hemoglobin (G/100 ml.)	Leucocyte count/cu.mm.	ESR (mm./1st hour)	Blood urea (mg./100 ml.)	Total serum protein (G/100 ml.)	Albumin (G/100 ml.)	Globulin (G/100 ml.)	Cholesterol (mg./100 ml.)	Carb. diox. (mEq./l.)	Bilirubin (mg./100 ml.)	Alk. phosph. (Bodansky units/ml.)	SGOT (Wroblewski units/ml.)	SGPT (Wroblewski units/ml.)	LDH (Wroblewski units/ml.)	LDH (Wroblewski units/ml.)	Serum tests for syphilis (Wassermann, VDRL, Kahn)	Albumin	Bilirubin	Urobilinogen	RBC	Pus cells	Casts	
1	11.0	6,100	15	37	7.1	3.73	3.37	102	30.7	—	—	—	—	—	—	Negative	0	0	0	0	0	0	0
2	11.0	7,500	8	48	5.6	3.00	2.60	94	26.2	—	—	—	—	—	—	Negative	0	0	0	0	0	0	0
3	12.0	18,000	107	73	6.0	2.77	3.23	89	18.6	—	—	—	—	—	—	Negative	0	0	0	0	0	0	0
4 (i)	10.5	10,700	20	40	6.8	2.90	3.90	90	13.4	—	—	—	—	—	—	Negative	0	0	0	0	0	0	0
4 (ii)	11.0	7,300	5	26	7.7	2.50	5.20	96	3.1	—	—	—	—	—	—	Negative	0	0	0	0	0	0	0
5 (i)	14.0	8,500	4	37	5.4	2.70	2.70	96	35.0	—	—	—	—	—	—	Negative	0	0	0	0	0	0	0
5 (ii)	13.0	12,500	1	44	8.0	2.80	2.50	98	34.5	—	—	—	—	—	—	Positive	0	0	0	0	0	0	0
6	14.5	11,900	10	130	5.3	2.60	3.20	95	27.3	—	—	—	—	—	—	Positive	0	0	0	0	0	0	0
7	5.5	10,500	22	384	5.8	2.60	3.20	100	16.0	—	—	—	—	—	—	Positive	0	0	0	0	0	0	0
8	12.0	12,000	32	264	6.3	2.50	3.80	104	14.2	—	—	—	—	—	—	Positive	0	0	0	0	0	0	0
9	14.6	26,000	—	28	6.9	3.40	3.50	107	25.6	—	—	—	—	—	—	Negative	0	0	0	0	0	0	0
10	9.5	5,800	55	—	—	—	—	—	—	—	—	—	—	—	—	Negative	0	0	0	0	0	0	0

Case 2

M.P., Cape Coloured female, aged 33 years. The patient was unemployed. She presented with complaints of progressive dyspnoea on effort, orthopnoea and productive cough for 2 weeks before admission.

On examination she was found to be in gross congestive cardiac failure, with intense dyspnoea, orthopnoea, marked oedema, hepatomegaly and considerable elevation of her jugular venous pressure. An initial blood pressure reading was 170/110 mm.Hg and the heart rate was 110/min. The heart was enlarged with a thrusting apex beat in the 6th interspace in the anterior axillary line and a protodiastolic gallop rhythm was present. Rhonchi and crepitations were heard over both lungs.

The initial electrocardiogram suggested left ventricular hypertrophy—mainly on voltage criteria—T wave inversion appearing in the left ventricular leads on subsequent recordings. A chest radiograph showed cardiomegaly, signs of pulmonary venous congestion and a small pleural effusion at both lung bases. Infiltrations at both lung apices suggested tuberculosis, but the radiological appearances were against an active lesion. In addition to the laboratory investigations shown in Table III, a FIGLU excretion was found to be 20-25 mg. in 24 hours. The TPP effect on transketolase activity was 25.1%.

The patient showed satisfactory improvement as a result of treatment. Her blood pressure dropped to levels as low as 130/80 mm.Hg, but fluctuated and at the time of discharge 3 weeks later, was 160/70 mm.Hg. At this time she was no longer in congestive failure and her heart was not enlarged. Five weeks later she was again admitted in congestive failure. The blood pressure now was 170/110 mm.Hg but during this admission the blood pressure rose again to levels of 170/135 mm.Hg and on the 4th day, despite anti-hypertensive therapy, she suffered a cerebrovascular accident which resulted in a right-sided hemiplegia.

This patient had systemic arterial hypertension but appeared also to have beriberi heart disease. The elevated FIGLU excretion lent support to a more generalized deficiency state as did the low serum albumin levels. Serum transaminase values and subsequently LDH values also provided evidence of hepatocellular damage (Table III).

Case 3

K.S., Bantu male, aged 43 years. This patient admitted to excessive alcohol intake and his diet was composed largely of carbohydrates. He complained of upper abdominal discomfort and substernal pain for a week. He also had a pleuritic type of pain and a non-productive cough and had been vomiting for a few days. For a week, too, he had been markedly dyspnoeic. He was aware of palpitations. He had also noticed that his urine had become very dark in colour.

On examination he was deeply jaundiced, dyspnoeic and acutely ill. He had the typical cutaneous changes of pellagra. His heart rate was 76/min., the pulse volume small and the blood pressure 80/65 mm.Hg. His temperature was subnormal (95°F). The jugular venous pressure was not raised and there was no oedema. The cardiac impulse was thrusting in quality and outside the midclavicular line and a protodiastolic gallop rhythm was present. No clinical abnormalities could be found in the lungs. There was tenderness in the upper abdomen and the liver was 4 fingers enlarged. The TPP effect on transketolase activity was 29.0%. Agglutination tests for leptospirosis were negative and the faecal and urinary porphyrin excretions were normal.

Radiographic examination of the chest showed marked cardiac enlargement and congestion of both lung fields. There was evidence of old tuberculosis in the right upper lobe. The electrocardiogram showed striking T wave changes extending from lead V₂ through V₆. Similar changes were also present in standard leads I, II and III.

The patient's subnormal temperature persisted and he remained severely ill for some days. During the first 48 hours after admission he tended to be hypotensive and a vasoconstrictor, metaraminol (Aramine) was required to maintain blood pressure levels of 80/60 mm.Hg. The patient responded gradually to treatment for liver failure as well as congestive car-

diac failure. The T wave changes of the electrocardiogram became more marked and deeply negative while he was in hospital and persisted despite the return of heart size to normal within 3 weeks. During this time the blood urea returned to normal values (27 mg./100 ml.) and there was no further clinical or laboratory evidence of hepatocellular damage. He was regarded as a case of beriberi heart disease and pellagra in association with severe hepatocellular damage.

Case 4

M.E., Cape Coloured female, aged 60 years. This patient complained of shortness of breath. She had episodes of paroxysmal nocturnal dyspnoea and was aware of swelling of her lower limbs. She had also suffered from palpitations and had noticed a swelling in her neck for about a year.

On examination she was found to be in congestive cardiac failure. The blood pressure was 120/70 mm.Hg. The heart rate was 180/min. and atrial fibrillation was present. The maximal cardiac impulse was in the 7th interspace in the anterior axillary line and was thrusting in nature. Jugular venous pressure was elevated, the liver was enlarged and there was peripheral oedema as well as ascites. Bilateral pleural effusions were present. In addition, she was seen to be jaundiced and had a multi-nodular thyroid swelling. She showed no other clinical features of hyperthyroidism. The BMR was 0%. The I¹³¹ uptake by the thyroid gland was 63.6% after 6 hours and 38.9% after 24 hours. Chest radiographs showed marked cardiomegaly and signs of posterior segment atelectasis in the right lower lobe of the lung. The electrocardiogram showed an atrial fibrillation but no other abnormalities. Liver biopsy showed mild hydropic degeneration of a few bile ducts. A number of the parenchymal cells displayed diffuse icterus of the cytoplasm, but necrosis and cirrhosis were not found.

The patient was treated for congestive heart failure and was also given antithyroid drugs. After 2 weeks jaundice was absent. Although atrial fibrillation persisted, the heart failure was brought under control and she was able to return home after 6 weeks. Four months later she was readmitted in a state of congestive cardiac failure again associated with jaundice. She had not carried on with her prescribed treatment. Rapid atrial fibrillation (ventricular rate 210/min.) was present and the blood pressure was 120/80 mm.Hg. The heart was of the same size as previously and a protodiastolic gallop rhythm was present. There was a mild proptosis with lid lag and she had a fine tremor in her hands. An electrocardiographic series showed, in addition to atrial fibrillation, T wave inversion, particularly in the precordial leads from V₁ through V₅ and V₆. A chest radiograph showed the presence of a large heart, pulmonary congestion and right basal pleural effusion. Radioactive iodine uptake by the thyroid gland was 69.2% after 6 hours and 51.4% after 24 hours. The BMR was +40. The TPP effect on transketolase activity shortly after this admission was 17.7%. Treatment for congestive cardiac failure was reinstated and she had a therapeutic dose of radioactive iodine. When she returned home after 5 weeks she was euthyroid and her heart size was greatly diminished, but atrial fibrillation persisted. She still had electrocardiographic changes which were consistent with a diagnosis of beriberi heart disease.

Case 5

A.M., Cape Coloured female, aged 27 years. In 1961 she developed swelling of the legs in association with dyspnoea and palpitations for a period of 9 months before coming under our observation. Her blood pressure was then found to be 140/100 mm.Hg and her pulse rate 70/min. The jugular venous pressure was elevated, the liver enlarged and she had oedema of the ankles. The maximal cardiac impulse was in the 5th interspace just outside the mid-clavicular line. There was a palpable thrill at the lower end of the sternum and the associated holosystolic murmur was accentuated on inspiration.

Chest radiographs showed cardiac enlargement, but no definite congestive changes in the lungs. The electrocardiogram demonstrated peaked P waves, but no other definite abnormalities. A phonocardiogram provided graphic evidence of a presystolic murmur at the apex of the heart maximal on inspiration and also showed a holosystolic murmur at this area.

Within 6 weeks after starting on conservative treatment for congestive cardiac failure her blood pressure was lowered to 125/85 mm.Hg, her heart had returned to normal size and the murmur which had been audible at the lower end of the sternum became very soft, no more than grade I/VI in intensity. In January 1962 she returned and her heart was found to be enlarged on a chest radiograph, but she was not in congestive failure. The murmurs at the tricuspid area were still present but diminished. Right heart catheterization was carried out and this showed the presence of a mild tricuspid stenosis with a diastolic gradient of 5 mm.Hg across the valve. An electrocardiogram taken at this time showed T wave inversion in the precordial leads V_1 through V_4 . The patient was discharged without any specific therapy. She again came under our care 3 years later in January 1965. She was now in gross cardiac failure, very short of breath and orthopnoeic. The blood pressure was 170/100 mm.Hg. Jugular venous pressure was raised, the liver was enlarged and there was oedema of the lower extremities. The maximal cardiac impulse was in the 6th intercostal space outside the mid-clavicular line and there was clinical evidence of pulmonary congestion. The presystolic and holo-systolic murmurs previously noted, were again audible over the tricuspid area. A chest radiograph showed considerable cardiac enlargement and congestive changes in both lung fields. The electrocardiogram now showed T wave inversion in precordial leads V_5 and V_6 . A further electrocardiogram taken 2 weeks after admission showed T wave inversion from leads V_1 to V_4 , but no longer present in leads V_5 - V_6 . Cineangiography demonstrated free incompetence of the tricuspid valve. There was a poorly contracting myocardium and considerable enlargement of both right atrium and right ventricle. Right heart catheterization showed no gradient across the tricuspid valve. The TPP effect on transketolase activity determined shortly after admission was 31.3%. This patient again responded well to treatment and left hospital in a satisfactory state. The blood pressure soon came down to levels of 120/80 mm.Hg. Her heart size had diminished and she was no longer in congestive cardiac failure. It was now considered that thiamine deficiency had contributed very largely to her cardiac failure and that she had an insignificant tricuspid valve lesion.

Case 6

J.L., Cape Coloured male, aged 61 years. This patient was in advanced congestive cardiac failure when first seen. He was orthopnoeic, had gross oedema, elevation of the jugular venous pressure to the angle of the jaw, and hepatic enlargement. The maximal cardiac impulse was in the 6th interspace in the anterior axillary line. The pulse had a full quality, but was not collapsing in nature. The blood pressure was 120/60 mm.Hg. An early blowing diastolic murmur was heard at the left sternal border. There was marked loss of power in both lower extremities, the patient being unable to move them. The deep reflexes were completely absent. He admitted to an excessive alcohol intake.

The electrocardiogram showed left-axis deviation and left ventricular hypertrophy. A chest radiograph demonstrated gross enlargement of the heart with pulmonary congestion. The TPP effect on transketolase activity was 22.7%.

The patient responded very poorly to conservative therapy for cardiac failure. Some improvement in diuresis was achieved following intravenous infusion of 10% mannitol. The degree of cardiac decompensation was considered to be out of proportion to the degree of aortic incompetence. The presence of follicular hyperkeratosis raised the possibility of hypovitaminosis-C; the plasma ascorbic acid level was found to be 0.4 mg./100 ml. A haemoptysis set in and persisted for some days. The patient's condition deteriorated steadily and he died 2 weeks after admission. At autopsy examination a syphilitic aortic incompetence of moderate degree was found but no narrowing of the coronary arteries was noticed. There was considerable enlargement of the heart particularly because of left ventricular hypertrophy. Histological examination (H. W. Weber, Department of Pathology) of the myocardium showed hydropic degeneration in many of the muscle fibres, particularly in the subendocardium and mostly in the right ventricle. In a few fibres the sarcoplasm had largely been dissolved. There was also marked oedema in the interstitial tissue and a mild fibrosis. There was no macroscopic evidence of kidney disease. Histolo-

gical sections of the kidney revealed hyperaemic tissue with normal glomeruli, a slight nephrosclerosis and severe autolytic changes of the tubular epithelium.

Case 7

J.B., Cape Coloured male, aged 61 years. This patient had been under observation for a period of 2 years. He was known to have chronic pyelonephritis in association with hypertension and renal failure. In January 1965 he was admitted in a condition of gross congestive cardiac failure, his blood pressure was 210/140 mm.Hg and a presystolic gallop rhythm was present. He remained in a state of chronic uraemia until he lapsed into an irreversible coma and died 3 weeks after admission. At this last admission the TPP effect on transketolase activity was 14.4%. Autopsy examination proved the presence of chronic pyelonephritis with superimposed acute pyelonephritic changes and arteriosclerosis and there was evidence of hypertensive heart disease and congestive cardiac failure.

Case 8

M.P., Cape Coloured female aged 21 years. This patient was first referred to us in March 1962 because of the incidental finding of heart murmurs. She was found to have a pure mitral stenosis and an aortic insufficiency, but was asymptomatic. The maximal cardiac impulse was in the 5th interspace within the mid-clavicular line. Her blood pressure was 115/65 mm.Hg. There was no evidence of rheumatic activity and an electrocardiogram was found to be within normal limits.

She remained well until 1965, when she became pregnant and went into congestive cardiac failure at about the 5th month of pregnancy. After hospitalization and conservative therapy for cardiac failure, she was considered fit for discharge 3 weeks later. At this stage she showed no signs of congestive failure and was maintained on oral diuretics, acetyldigitoxin and a salt-restricted diet.

In March 1965 with her pregnancy at 32 weeks, she was once again seen to be in congestive cardiac failure and also complained of abdominal pain. Premature labour was suspected, and because of the cardiac condition it was decided to induce labour and undertake a forceps delivery. The patient subsequently did well and was fit enough to be discharged from hospital 4 days later. She showed no evidence of congestive failure and was put on maintenance treatment with acetyldigitoxin, an oral diuretic and a salt-free diet. At this last admission the TPP effect on transketolase activity had been found to be 16.8%.

Case 9

A.T., Bantu male aged 24 years. This patient, a labourer, who admitted taking large quantities of alcohol, was seen in an acutely ill condition. He complained of swelling of the ankles which had been progressive over a period of at least 3 weeks, and also of facial and peri-orbital swelling. He had been short of breath and somewhat orthopnoeic for the same period. He had had 3 episodes of epistaxis. He also gave a history of having had diarrhoea 4 weeks previously, of having passed very little urine for 3 weeks and of substernal pain and cough. The patient was severely ill, with a subnormal temperature and gross generalized oedema. He became hypotensive, the blood pressure dropping from an initial reading of 150/90 mm.Hg to unrecordable levels. During the first 12 hours following admission it became necessary to administer a vasoconstrictor (metaraminol) to maintain his circulation. The jugular venous pressure was markedly elevated and the liver was enlarged. The heart was enlarged with the maximal cardiac impulse in the 6th interspace in the anterior axillary line. The heart sounds were softly heard and a protodiastolic gallop was clearly audible. There were crepitations heard over both lungs and there was clinical evidence of bilateral pleural effusion. The deep reflexes were absent. In addition to the other laboratory investigations (Table III), the blood platelets were 28,000/cu.mm. at admission and 47,000/cu.mm. 2 days later. The TPP effect on transketolase activity was 89%, suggesting a marked thiamine deficiency. The electrocardiogram showed unimpressive T wave changes in the right precordial leads V_1 to V_4 . Radiographic examination of the chest showed a markedly enlarged heart with signs of pulmonary oedema.

The patient improved markedly and rapidly with bed rest, the normal hospital diet and conservative therapy for conges-

tive cardiac failure. A clinical diagnosis was made of acute beriberi heart disease (Shoshin). Thiamine supplements were not given. Forty-eight hours after admission, while the patient still had all the evidence of his congestive cardiac failure, his condition had improved sufficiently to permit cardiac catheterization. Coronary sinus studies and the determination of coronary flow by the nitrous oxide method were carried out. The results are summarized in Tables IV and V and are discussed later.

The acute renal failure, as demonstrated by oliguria, an elevated blood urea and potassium, and a reduced CO₂-combining power improved rapidly and at the time of discharge after 1 month of treatment, all clinical and laboratory evidence of heart, liver and renal failure had disappeared. The electrocardiographic series showed characteristic progressive T wave inversion in right precordial leads during his hospital stay (Fig. 1). A radiograph of his chest showed a return to normal in heart size after 1 month (Fig. 2(a) and (b)).

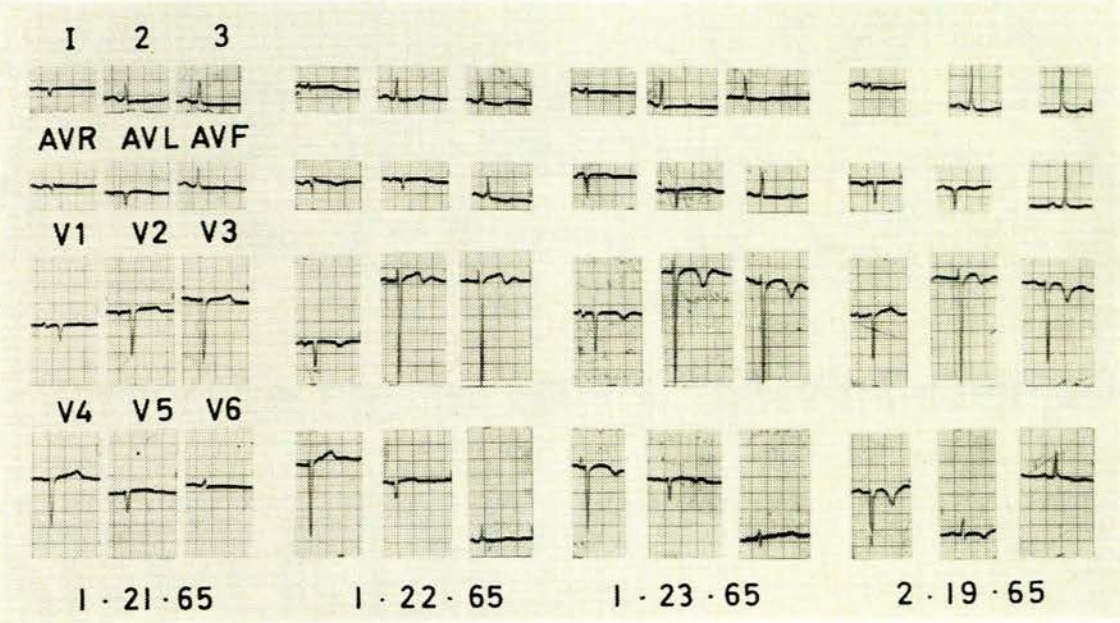


Fig. 1. Serial ECG changes in beriberi heart disease (Patient 9).

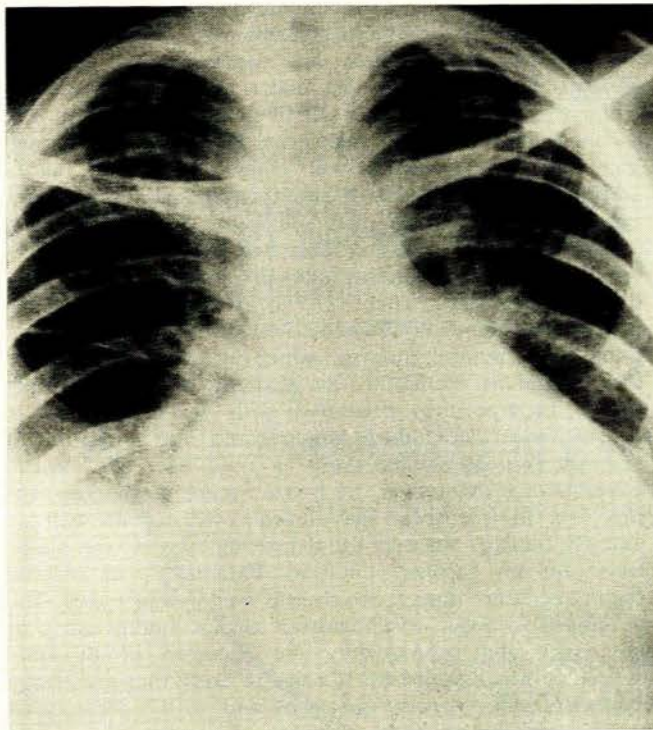


Fig. 2a. PA radiograph of chest showing cardiomegaly, pleural effusion and pulmonary congestion (Patient 9).

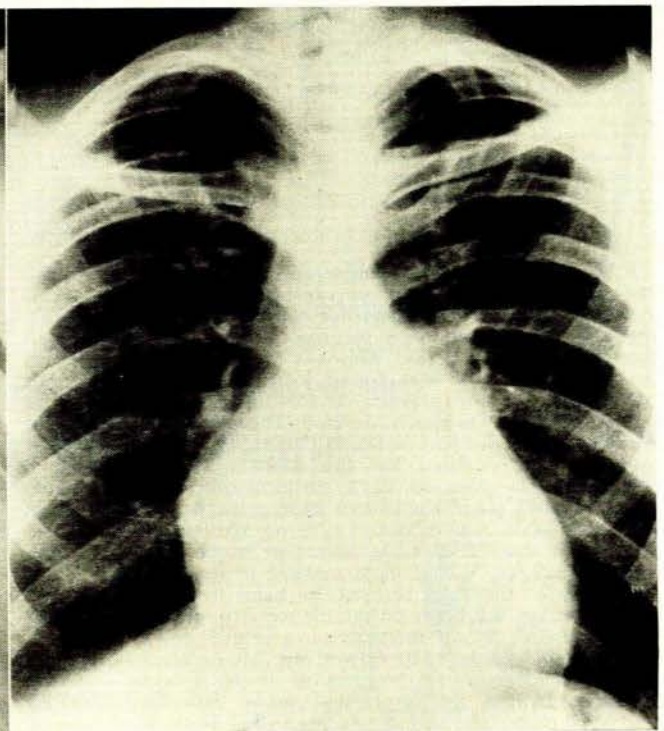


Fig. 2b. PA radiograph of chest showing marked decrease in heart size after 1 month's therapy (Patient 9).

He was readmitted in congestive cardiac failure 2 months after being discharged, not as acutely ill as before and not in renal failure, but otherwise having the same cardiovascular findings. This time no evidence for thiamine deficiency could be established by the transketolase technique.

TABLE IV. CARDIAC STUDIES: HAEMODYNAMICS AND ENERGETICS IN 2 PATIENTS WITH BERIBERI HEART DISEASE

	Patient 9		Patient 10	
	AT	RO	AT	RO
Mean pulmonary capillary wedge pressure (mm.Hg)	25	6.5		
Mean pulmonary arterial pressure (mm.Hg)	40	9		
R. ventricular pressures (mm.Hg):				
Systolic	65	24		
Diastolic	12-25	-6-4		
Mean R. atrial pressure (mm.Hg)	13	-2.5		
Mean aortic pressure (mm.Hg)	100	80		
L. ventricular pressures (mm.Hg):				
Systolic	103	—		
Diastolic	27-42	—		
Cardiac index (l./min./m ²)	2.51	2.91		
Total peripheral resistance (dynes-sec.-cm. ⁻⁵)	1,800	1,520		
Pulmonary vascular resistance (dynes-sec.-cm. ⁻⁵)	311	46		
Oxygen uptake (ml./min./m ²)	143	124		
Oxygen content: coronary sinus blood (vols. %)	4.00	2.90		
Arterial—coronary sinus O ₂ difference (vols. %)	14.7	8.1		
Arterial—mixed venous O ₂ difference (vols. %)	5.70	4.26		
Coronary blood flow (ml./min./100 G L. ventricle)	26.5	90.8		
Diastolic coronary vascular resistance (dynes-sec.-cm. ⁻⁵)	170,000	45,000		
Myocardial oxygen usage (ml./min./100 G L. ventricle)	3.90	7.35		
Left ventricular work (kg.-m ² /min./m ²)	2.28	3.83		
Mechanical efficiency ratio	18.59	17.54		
Tension-time index per min. (mm.Hg sec. per min.)	2,327	2,081		

TABLE V. CARDIAC STUDIES: MYOCARDIAL METABOLISM AND ENZYME STUDIES IN 2 PATIENTS WITH BERIBERI HEART DISEASE

	Patient 9		Patient 10	
	AT	RO	AT	RO
Coronary blood flow (ml./min./100 G)	26.5	90.0		
Myocardial oxygen extraction (vols. %)	14.7	8.1		
Myocardial oxygen usage (ml./min./100 G)	3.9	7.4		
Arterial glucose (mg./100 ml.)	89-10	77-76		
Myocardial glucose extraction (mg./100 ml.)	2.34	6.66		
Myocardial glucose usage (mg./min./100 G)	0.620	6.05		
Arterial pyruvate (mg./100 ml.)	0.896	1.10		
Myocardial pyruvate extraction (mg./100 ml.)	-0.52	0.29		
Myocardial pyruvate usage (mg./min./100 G)	—	0.263		
Arterial lactate (mg./100 ml.)	7.44	4.28		
Myocardial lactate extraction (mg./100 ml.)	2.11	2.55		
Myocardial lactate usage (mg./min./100 G)	0.559	2.315		
Arterial FFA* (mEq./100 ml.)	0.0730	0.0495		
Myocardial FFA* extraction (mEq./100 ml.)	0.0343	0.0120		
Myocardial FFA* usage (mEq./min./100 G)	0.0091	0.011		
FFA* oxygen equivalent as per cent of oxygen extraction	133	84		
Arterial inorganic phosphate (mg./100 ml.)	—	4.4		
Coronary sinus inorg. phosph. (mg./100 ml.)	—	4.6		
Arterial CPK (Wróblewski units/ml.)	—	0.2		
Coronary sinus CPK (Wróblewski units/ml.)	—	0.7		
Arterial aldolase (milli-units/ml.)	—	0.9		
Coronary sinus aldolase (milli-units/ml.)	—	1.3		
Pyruvate-lactate redox: Arterial E _h (mV)	-260	-240		
Pyruvate-lactate redox: Δ E _h (mV)	+11	+16		
Transketolase activity (% TPP effect)	89.4	13.3		

* FFA = Free fatty acids.

Case 10

R.O., Cape Coloured female, aged 35 years. This patient had progressive dyspnoea on exertion, attacks of nocturnal dyspnoea and ankle oedema for a month before admission. She also complained of a pleuritic type of pain in the left chest for the same period. She was the mother of 6 children. On examination she was found to be in congestive cardiac failure with a blood pressure of 155/100 mm.Hg. The jugular venous pressure was much elevated. There was enlargement of the liver and dependent oedema. The maximal cardiac impulse could not be localized but the heart sounds were normal except for the presence of a protodiastolic gallop rhythm. Bilateral basal pleural effusions were present. The TPP effect on transketolase activity was 13.3% on admission. An electrocardiogram showed T wave inversion to be present in precordial leads V₃-V₆ but most marked in leads V₃ and V₆. A radiograph of the chest showed the heart to be enlarged, and on fluoroscopy the heart pulsations were found to be poor.

The patient's blood pressure soon settled down to normal levels in the region of 120/80 mm.Hg. An electrocardiographic series showed an initial progression of the T wave inversion especially in the left precordial leads. Subsequent graphs showed a regression in the left precordial leads to upright T waves, while inversion of the T wave developed in right precordial leads and persisted.

Cardiac catheterization with coronary sinus studies was performed 13 days after admission while the patient's heart was still enlarged. The results of these studies are summarized in Tables IV and V. The cardiac size on the radiograph showed a decrease during the 3 weeks following admission. The patient improved steadily and maintained her improvement until discharged from hospital 4 weeks after admission.

COMMENTS ON CLINICAL MATERIAL

In 54 patients with heart disease reported here, thiamine deficiency was present in 5 male and 5 female Coloured patients. The TPP values varied from 13.3% in patient 10 to as high as 89.4% in patient 9 (Table II). With the possible exception of 10 (13.3%), the TPP values observed were well above the marginal value of 12%. According to Brin *et al.*¹² these high TPP values are a definite indication of depressed transketolase activity and thus of thiamine deficiency. Brin¹⁰ also demonstrated that the effect of thiamine deficiency on the erythrocyte is a reflection of similar effects on other tissues, since thiamine deficiency also resulted in a reduced transketolase activity in liver, kidney, spleen, intestine, lung and heart.

The clinical evidence suggests that 3 of these patients (3, 9 and 10) had no other cause for congestive cardiac failure apart from their deficiency state. Patients 1 and 2 were regarded as being 'hypertensive' but in both cases this hypertension was subsequently thought to be, at least in part, that which is associated with beriberi and which tends to return to normal as the illness improves.²⁷

Patient 5 had a tricuspid valve murmur. Cardiac catheterization indicated a mild tricuspid stenosis and incompetence. This finding, however, could not account for her generalized congestive cardiac failure, and it is our belief that she was in failure wholly as a result of her thiamine deficiency. The electrocardiographic evidence in this patient also strongly supported this concept.

From the above discussion it appears that 6 of these patients, 1, 2, 3, 5, 9 and 10, had a myocardial cause for congestive failure which in all likelihood was mainly the consequence of thiamine deficiency. Patient 4 was interesting in that she presented with congestive cardiac failure and had hyperthyroidism. The thiamine status had not been determined on her first admission. Six months later, again in gross congestive cardiac failure, she had a severer degree of hyperthyroidism and thiamine deficiency was demonstrated (TPP effect 17.7%). It is likely that this patient's thiamine requirements had been increased by an initial mild hyperthyroidism which subsequently became more apparent. Patient 6, an alcoholic with a syphilitic aortic incompetence, presented with severe irreversible congestive cardiac failure, which could not be attributed to what was considered to be a mild degree of aortic incompetence. Moreover, he had a severe peripheral neuritis and in retrospect the clinical evidence as well as autopsy findings suggests the deficiency state as the major cause for his cardiac condition. Patient 8 had chronic rheumatic heart disease which was well-compensated. She developed evidence of congestive cardiac failure early in pregnancy and subsequently the presence of thiamine deficiency was established. It appears likely that pregnancy aggravated the thiamine deficiency and, in the presence of rheumatic heart disease, congestive cardiac failure was precipitated. In only 1 patient (No. 7) was there adequate

reason, apart from the presence of a thiamine deficiency, to explain the congestive cardiac failure. (He was a known chronic nephritic with hypertension and uraemia).

It appears to us in retrospect, that the clinical setting of these 10 patients was such that thiamine deficiency could well have been suspected to have been at least a contributory factor producing heart failure in the majority and that the biochemical confirmation should perhaps not have been unexpected.

A leucocytosis is known to occur in acute beriberi,²⁸ but a thrombocytopenia, as in our patient 9, has not been described. This could well have been associated with the acute renal failure and the uraemic condition.

Acute renal failure was shown to be present in patient 9. In patient 6 too, renal failure was evident, yet there was no autopsy evidence of underlying renal pathology. Renal involvement has been reported before in cases of beriberi.²⁹ It has also been shown that whereas total peripheral resistance may drop to as low as a quarter of the normal in cases of beriberi, there is an increase of resistance to flow in the skin and the kidney.³⁰ In a discussion on the causes of irreversible acute renal failure Eales *et al.*³¹ list a case of acute beriberi with bilateral cortical necrosis of the kidneys. Metabolic acidosis as observed in our patient 9, has also been said to be a factor causing death in the acute form of this condition.³⁰

A further observation which may have significance in the pathogenesis of beriberi heart disease in these patients is the evidence of liver damage demonstrated in 5 of these patients (2, 3, 4, 6 and 9). Patient 3 had a marked degree of jaundice and appeared to be in severe liver failure. Jaundice and elevated bilirubin levels were also present in patient 4, who displayed diffuse icterus of the liver parenchyma but not liver necrosis, such as might have been expected in view of the presence of hyperthyroidism, while the other patients had raised transaminase and lactic acid dehydrogenase (LDH) levels. Liver failure has so far as we can determine not been described as part of the beriberi syndrome. It has been shown experimentally that liver damage can depress transketolase activity.³² It is, therefore, conceivable either that thiamine deficiency may be responsible for a degree of hepatocellular damage or that pre-existing liver disease may predispose to beriberi heart disease through a depression of enzymatic activity.

The serum albumin values, where available in the group of 54 patients studied, strengthened the evidence supporting a state of undernutrition in the patients with thiamine deficiency (Table VI). Albumin values lower than 3 G/100

ml. were found in no less than 6 out of 8 non-White patients (75%) with established thiamine deficiency, in comparison with 33% of the White patients and 40% of the non-White patients without thiamine deficiency (TPP effect < 12%).

More evidence for existing deficiency states was found, viz. the increased FIGLU excretion in patient 2, evidence of pellagra in patient 3 and severe peripheral neuritis and low plasma ascorbic acid levels in patient 6. Moreover, the known social circumstances of patients 1, 2 and 6 predisposed towards a deficiency condition.

The greater metabolic requirements for thiamine in the hyperthyroid state in patient 4 and by the pregnancy in patient 8, may together with a degree of thiamine depletion have precipitated heart failure.

The electrocardiogram, however, provided the best additional evidence of possible thiamine deficiency in these 10 patients. Electrocardiographic changes may be strongly indicative of beriberi heart disease,³³ the precordial V-leads being most useful in this respect. The initial electrocardiogram may show little in the way of abnormalities apart from flattening of T waves, but during the course of the next few days of this illness, T wave inversion may occur progressively from lead V₁, through to leads V₃, V₄ or V₅. These T wave changes may, moreover, be labile but in general tend to become more pronounced as the condition appears to improve. Other patients may have more pronounced T wave inversion in left precordial leads V₅ and V₆. Some patients again may during the course of observation have T wave changes first in right precordial leads and at another time in left precordial leads. Definite and progressive T wave inversion in right precordial leads V₁ to V₄ or V₅ was found in patients 1, 3, 4, 5, 9 and 10. Patient 5, in addition, showed few T wave changes of significance when first studied, but subsequently showed T wave inversion from V₁ through V₄ and V₅. On another occasion there was T wave inversion in leads V₅ and V₆ and yet later there was T wave inversion again on leads V₁ to V₄ but no longer in V₅ and V₆. On the criteria of T wave inversion from V₁ to V₃ or from V₆ back through V₃ being present or developing and fluctuating during the course of the condition, 9 of the 10 patients with known thiamine deficiency could be regarded as also having electrocardiographic evidence compatible with a diagnosis of beriberi heart disease. On the other hand, only 15 (or 43%) of the other non-White patients could by these criteria be regarded as possibly having a thiamine deficiency and similarly only 4 (or 33%) of the White patients (Table VII).

TABLE VI. CORRELATION OF THIAMINE STATUS AND SERUM ALBUMIN VALUES IN 54 PATIENTS IN CONGESTIVE CARDIAC FAILURE

	Total No. of patients	Serum albumin values	
		No. of patients in whom determined	% age with albumin < 3 G/100 ml.
White:	12	6	33
Non-White:			
Patients with TPP effect > 12%	10	8	75
Patients with normal transketolase activity	32	15	40

TABLE VII. CORRELATION BETWEEN THIAMINE STATUS AND ECG EVIDENCE OF BERIBERI HEART DISEASE IN 54 PATIENTS IN CONGESTIVE CARDIAC FAILURE

	Number of patients in CCF	No. with ECG T wave inversion in V ₁ to V ₃ or V ₆ to V ₃ or labile T waves	Percentage with significant T wave inversion
White:	12	4	33
Non-white:			
Patients with TPP effect > 12%	10	9	90
Patients with normal transketolase activity	32	15	43

The relapse into congestive failure occurring in patient 9 two months after the first observations, this time without laboratory evidence of thiamine deficiency (the TPP effect being 0% in contrast to the 89% on the first admission) may have some bearing on the question of the progression of chronic thiamine deficiency to an irreversible form of cardiac damage. There is experimental evidence for structural damage to heart muscle in thiamine deficiency³⁴ and some clinical observers hold that permanent cardiac damage may result.^{30,35,36} Progress to irreversible heart failure has, however, not been proved and is disputed.³⁷ The findings in this patient lend some support to the observations and views of Gillanders,³⁸ who described cryptogenic heart disease in the Bantu in Johannesburg and concluded that it had a nutritional basis. Doubt was cast on these conclusions and his patient's condition was regarded as being part of the spectrum of cryptogenic heart disease seen in South Africa and not as having a nutritional basis.^{39,40}

Patient 10 illustrates that beriberi heart disease may masquerade as other conditions. Initially this patient was regarded as being hypertensive, but hyperpiesis is known to be associated with beriberi.²⁷ Beriberi heart disease may also simulate constrictive pericarditis as was the case in this same patient who was found to have markedly elevated venous pressure and other prominent signs of right-sided heart failure with very poor cardiac pulsations on fluoroscopy.

Patients 9 and 10 were considered to be in congestive cardiac failure as a result of thiamine deficiency and not to have any other underlying cardiac condition or associated pathology which might have contributed to the clinical picture. Patient 9 was regarded as having an acute form of beriberi, presenting with vascular collapse—a form which has been named Shoshin by the Japanese, while patient 10 was thought to be a subacute form with initial hypertension. These 2 patients were subjected to more intensive cardiovascular studies, both haemodynamic and metabolic, and this aspect is, therefore, discussed in the following section.

HAEMODYNAMICS, ENERGETICS AND MYOCARDIAL METABOLISM IN 2 CASES OF BERIBERI HEART DISEASE

Patients 9 and 10 were studied by cardiac catheterization. The haemodynamic findings and cardiac energetics are presented in Table IV. Patient 9 showed evidence of congestive cardiac failure on catheterization with elevation of end-diastolic pressures in both left and right ventricles. The pulmonary capillary pressure and pulmonary artery pressures were elevated. Systemic pressures and resistance were normal, while the cardiac output was low. Patient 10 was not in congestive failure at the time of catheterization and pulmonary artery, and systemic pressures and resistance were normal. The cardiac index, however, was also low.

The finding of a low-output type of heart failure is in conformity with the experience of others who have noticed that beriberi heart disease need not be of the high-output type.⁴¹⁻⁴³

Coronary flow was markedly reduced in patient 9 in acute failure (26.5 ml./min./100 G left ventricular muscle) and mildly elevated in patient 10 (90.8 ml./min./100

G). The average normal flow by the N:O method is 65 ml./min./100 G heart muscle.³⁶ Patient 9 showed a high oxygen extraction value (14.7 vols.%) but it is to be observed that the oxygen consumption by the myocardium was much reduced, viz. 3.9 ml./min./100 G, the normal being 7-8 ml./min./100 G. Patient 10 with a high flow averaged a somewhat lower than normal extraction of 8.1 vols.% with normal myocardial usage of oxygen (7.35 ml./min./100 G). It has been suggested that the coronary flow to heart muscle is delicately adjusted by the oxygen usage and when this is low, a reduction in coronary flow may occur in the presence of normal mean aortic pressure.⁴⁴ Diastolic coronary vascular resistance was much increased in patient 9, being 170,000 dynes-sec.-cm.⁻⁵ and reduced in patient 10, 45,000 dynes-sec.-cm.⁻⁵, the average normal being in the region of 69,000 dynes-sec.-cm.⁻⁵⁴⁵

In the instance of patient 9, thiamine deficiency in the acute condition appears to have reduced the capacity for oxygen utilization even though, as will be apparent from other evidence to be presented, there was no evidence for anaerobic metabolism. A reduction in coronary flow appears to have resulted from a lessened metabolic demand for oxygen. In patient 10, who was already in the stage of recovery and no longer in congestive cardiac failure, this did not appear to be the case.

Left ventricular work according to accepted standards,⁴⁶ was reduced in both patients. The mechanical efficiency of the left ventricular muscle was determined from the work of the left ventricle (kg./meters/min.) in relation to the energy cost of myocardial contraction in terms of left ventricular myocardial oxygen usage (ml./min.) and appears to be less than reported normal values.⁴⁶ The tension-time-index (TTI) per minute in mm.Hg/seconds was obtained by planimetric integration of the area under the systolic portion of the aortic pressure curve and is equal to the product of mean systolic pressure, the duration of systole and the heart rate. It has been stated that in any given functional state of the beating heart the tension-time-index (TTI) is the principal if not the sole determinant of myocardial oxygen utilization.⁴⁵ The values obtained in our patient appear to be of the same order but less than those found by the previous authors and by Gorlin in normal subjects at rest.⁴⁵

The myocardial metabolic observations are presented in Table V. The myocardial metabolism in patient 9 was determined in the fasting state and in patient 10 in the postabsorptive state. In the former patient this would have favoured the preferential use of fats to supply energy.⁴⁷ This study shows indeed that in this patient glucose extraction was low, even though the arterial blood glucose concentration was as high as 89 mg.%. Myocardial glucose usage was only 0.62 mg./min./100 G heart muscle, a value much below the limits established for the normal heart.⁴⁸ Pyruvate extraction was negligible and usage nil, while lactate extraction and usage were low, despite average normal arterial levels. It is evident that this patient depended heavily on other foodstuffs for myocardial energy supply. The elevated extraction (0.0343 mEq./100 ml.) and usage (0.0091 mEq./min./100 G) of free fatty acids especially in terms of the oxygen equivalent (133%) are high when compared with normal average values (57.2%) described by Ballard *et al.*²⁴

In patient 10, studied in the postabsorptive state and in a phase of recovery from her thiamine deficiency, glucose extraction and consumption values, despite a lower arterial glucose level (77.8 mg.%) than in patient 9, were average normal. Blood pyruvate levels were high normal and extraction values an average normal, while lactate had normal extraction and consumption values. Nevertheless this patient too, appeared to make big demands on fats for energy supplies as can be seen by the high extraction values (0.012 mEq./100 ml.) and consumption values (0.0109 mEq./min./100 G). Again the oxygen equivalent as percentage of oxygen uptake (77%) is higher than the reported normal average values.

Both of these patients' fasting blood pyruvate levels were not elevated and it is recognized that an elevation of this substrate in beriberi is not a *sine qua non* for the diagnosis,⁴³ although this may be present and has also been shown to occur experimentally in thiamine-deficient dogs.⁴⁹ Olson⁴³ described a high-output type of beriberi in which the extraction of pyruvate and lactate of the heart muscle was very low.

It has been suggested that the difference in redox potential referred to as ΔE , calculated from the lactate/pyruvate ratios in arterial and coronary sinus blood, may reflect the aerobic and anaerobic metabolic conditions in the heart muscle.⁵⁰ When ΔE_h is positive, active cellular oxidation occurs and energy required is supplied by oxidative phosphorylation. When ΔE_h is negative, glycolysis and anaerobic phosphorylation become an important source of energy. The redox potential for the pyruvate-lactate system was calculated and in both instances found to be decidedly positive, suggesting dependency on oxidative phosphorylation for energy requirements. The coupling mechanism refers to the formation of energy-rich phosphate bonds (ATP) which occurs during the oxidation of various substrates. Under certain conditions, oxidation may occur without the simultaneous formation of high-energy bonds, viz. a process of 'uncoupling'. It has been shown that uncoupling of oxidative phosphorylation results in an increased intracellular concentration of inorganic phosphate.⁵¹ Sundermeyer *et al.*⁵² attribute the elevated inorganic phosphate concentration in the blood of patients with muscular dystrophy to such a mechanism.

The evidence for oxidative phosphorylation in patients 9 and 10 derived from the positive redox potential together with a normal inorganic phosphorus content of both arterial and coronary sinus blood in patient 10 suggests that uncoupling of oxidative phosphorylation is not responsible for the metabolic failure. The deductions made from differences in lactate/pyruvate ratios in arterial and coronary sinus blood have, however been criticized by Olson.⁵³

Because of the known disturbances in the enzymes aldolase and creatine phosphokinase in certain muscular dystrophies,⁵⁴ the concentrations of these enzymes were also determined in the arterial and coronary sinus blood in patient 10. Both enzymes, aldolase being a cytoplasmic enzyme and creatine phosphokinase a mitochondrial enzyme, show a greater concentration in coronary sinus blood suggesting a release from muscle cells.

CONCLUSIONS

The transketolase method has proved to be a very useful technique for indicating thiamine status in a series of 54 patients in congestive cardiac failure. Additional clinical and laboratory evidence of a deficiency state indicated that this method could be regarded as reliable.

In our own area (the environs of Cape Town) we were able to establish that as many as 25% of Cape Coloured and Bantu patients in congestive cardiac failure may have thiamine deficiency either as the sole cause for congestive cardiac failure or as a contributory factor to some other underlying cardiac condition.

It is conceivable, moreover, that some of our patients in South Africa with cryptogenic heart disease may yet be shown to have a progressive form of beriberi heart disease.

In 2 patients with beriberi heart disease, it could be observed that the left ventricular work and left ventricular myocardial efficiency were reduced. Both patients had a low cardiac output and peripheral resistance was not decreased. In the acute form of beriberi as in patient 9, the coronary blood flow was much reduced and appears to be the consequence of a reduced metabolic demand for oxygen. There is an accompanying increase in coronary vascular resistance. In the subacute or recovery phase, as in patient 10, coronary flow was increased and coronary vascular resistance decreased.

From our patients we have observed that the energy supply to the myocardium in beriberi heart disease both in the fasting and the postabsorptive state, is largely through the medium of fats, while carbohydrates are not called upon to supply energy to the same extent. Nevertheless, the oxidative phosphorylation mechanism appears to be intact as judged from the positive difference in redox potentials across the heart muscle with no increase in inorganic phosphorus content of the coronary sinus blood.

These observations would appear to us to support the concept of a suppression of enzymatic reactions in the supply of energy for the contractile mechanism so that the total metabolic requirements of oxygen may be reduced, although the main pathway of energy supply is still an oxidative one.

SUMMARY

1. Thiamine status was studied by means of the effect of thiamine pyrophosphate on transketolase activity in a series of 54 patients in congestive cardiac failure.
2. A deficiency state could be demonstrated in 10 patients all of whom were from the Cape Coloured or Bantu groups, representing a 25% incidence of thiamine deficiency in non-White patients with congestive cardiac failure. No White patient was found to be deficient in thiamine.
3. Additional evidence for a deficiency state was indicated by the low serum albumin levels, the electrocardiographic appearances and other clinical associations.
4. Two patients were studied by means of cardiac catheterization and coronary sinus studies with the determination of coronary blood flow and observations on myocardial metabolism. One patient had an acute form of beriberi heart disease (Shoshin), while the other had a subacute manifestation of the condition. Both patients had a low-output type of heart failure with a normal peripheral resistance.
5. The observations showed that coronary blood flow was markedly reduced in the acutely ill patient, while in both cases carbohydrates were a poorer source of energy for the heart than fats.

6. The conclusion is made that the metabolic inability to utilize oxygen in cases of thiamine deficiency results from a toxic depression of the energy-liberating pathways and that the oxidative phosphorylation mechanism proceeds without uncoupling taking place. As a consequence of the lessened metabolic demand for oxygen, coronary blood flow may be reduced.

7. The myocardium may release both aldolase and creatine phosphokinase into the coronary sinus blood in this condition.

REFERENCES

- Schrire, V. (1964): S. Afr. Med. J., **38**, 598.
- Cosnett, J. E. (1962): Brit. Heart J., **24**, 76.
- Schwartz, M. B., Schamroth, L. and Seftel, H. C. (1958): Med. Proc., **4**, 275.
- Banhidi, Z. G. (1959): Analyst, **84**, 657.
- Edwards, M. A., Kaufman, M. L. and Storvick, C. A. (1957): Amer. J. Clin. Nutr., **5**, 51.
- Baker, H., Frank, O., Fennelly, J. J. and Leevy, C. M. (1964): *Ibid.*, **14**, 197.
- Haugen, H. N. (1960): Scand. J. Clin. Lab. Invest., **12**, 384.
- Kingsley, G. R. (1961): Analyt. Chem., **33**, 13R.
- Horwitt, M. K. and Kreisler, O. (1949): J. Nutr., **37**, 411.
- Buckle, R. M. (1965): Metabolism, **14**, 141.
- Wolfe, S. J., Brin, M. and Davidson, C. S. (1958): J. Clin. Invest., **37**, 1476.
- Brin, M., Tai, M., Ostashever, A. S. and Katinsky, H. (1960): J. Nutr., **71**, 273.
- Idem* (1962): Ann. N.Y. Acad. Sci., **98**, 528.
- Kety, S. S. and Schmidt, C. F. (1945): Amer. J. Physiol., **143**, 53.
- Eckenhoff, J. E., Hafkenschiel, J. H., Harmel, M. H., Goodale, W. T., Lubin, M., Bing, R. J. and Kety, S. S. (1948): *Ibid.*, **152**, 356.
- Bing, R. J., Hammond, M. M., Handelsman, J. C., Powers, S. R., Spencer, F. C., Eckenhoff, J. E., Goodale, W. T., Hafkenschiel, J. H. and Kety, S. S. (1949): Amer. Heart J., **38**, 1.
- Van Slyke, D. D. and Neill, J. M. (1924): J. Biol. Chem., **61**, 523.
- Sarnoff, S. J., Braunwald, E., Welch, G. H., Stainsby, W. W., Case, R. B. and Macruz, R. (1958): Amer. J. Physiol., **192**, 148.
- Hugget, A. St. G. and Nixon, D. A. (1957): Biochem. J., **66**, 12P.
- Horn, H. D. and Bruns, F. H. (1956): Biochem. Biophys. Acta, **21**, 378.
- Opie, L. H., Shipp, J. C., Evans, J. R. and Leboeuf, B. (1962): Amer. J. Physiol., **203**, 839.
- Redetzki, H., Bloedorn, H. and Bansi, H.-W. (1956): Klin. Wschr., **34**, 845.
- Dole, V. P. and Meinertz, H. (1960): J. Biol. Chem., **235**, 2595.
- Ballard, F. B., Danforth, W. H., Naegle, S. and Bing, R. J. (1960): J. Clin. Invest., **39**, 717.
- Hiller, A. (1957): *Practical Clinical Chemistry*, p. 118, 2nd ed. Springfield, Ill.: Charles C. Thomas.
- Brin, M. (1962): J. Nutr., **78**, 179.
- Walters, J. H. (1953): Quart. J. Med., **22**, 195.
- Wolf, P. K. and Levin, M. B. (1960): New Engl. J. Med., **262**, 132.
- Platt, B. S. (1958): Fed. Proc., **17**(3), Part II, 8.
- Blacket, R. B. and Palmer, A. J. (1960): Brit. Heart J., **22**, 483.
- Eales, L., Dowdle, E. B. and Saunders, S. J. (1964): S. Afr. Med. J., **38**, 251.
- Fennelly, J., Frank, O., Baker, H. and Leevy, C. M. (1964): Proc. Soc. Exp. Biol. (N.Y.), **116**, 875.
- Schrire, V. and Gant, J. (1959): S. Afr. J. Lab. Clin. Med., **5**, 195.
- Follis, R. H. (1958): Fed. Proc., **17**(3), Part II, 23.
- Smith, J. J. and Furth, J. (1943): Arch. Intern. Med., **71**, 602.
- Dock, W. (1940): Trans. Assoc. Amer. Phycns., **55**, 61.
- Rowlands, D. T. and Vitter, C. F. (1960): Circulation, **21**, 4.
- Gillanders, A. D. (1951): Brit. Heart J., **13**, 177.
- Becker, B. J. P., Chatgidakis, C. B. and Van Lingen, B. (1953): Circulation, **7**, 345.
- Report of a joint seminar of the Departments of Pathology and Medicine of the University of the Witwatersrand (1957): S. Afr. Med. J., **31**, 854.
- Wagner, P. J. (1965): Amer. Heart J., **69**, 200.
- Blankenhorn, M. A. (1945): Ann. Intern. Med., **23**, 398.
- Olson, R. E. (1958): Fed. Proc., **17**(3), Part II, 24.
- Idem* (1962): *Handbook of Physiology*, section 2, Circulation 1, 199. Washington, D.C.: American Physiological Survey.
- Gorlin, R. (1960): *Modern Trends in Cardiology*, p. 191. London: Butterworths.
- Horwarth, S. M. (1959): *Coronary Blood Flow and Cardiac Energetics*. New York: Paul. B. Hoeber Inc.
- Bing, R. J. (1954): Harvey Lect., **50**, 27.
- Bing, R. J., Siegel, A., Vitale, A., Balboni, F., Sparks, E., Taeschler, M., Klapper, M. and Edwards, S. (1953): Amer. J. Med., **15**, 284.
- Hackle, D. B., Goodale, W. T. and Kleinerman, J. (1953): Amer. Heart J., **46**, 883.
- Gudbjarnason, S., Hayden, R. O., Wendt, V. E., Stock, T. B. and Bing, R. J. (1962): Circulation, **26**, 937.
- Lehninger, A. L., Wadkins, C. L. and Rimmert, L. F. in Wolstenholme, G. E. W. and O'Connor, C. N., eds. (1958): *Regulation of Cell Metabolism*, p. 130. London: J. & A. Churchill.
- Sundermeyer, J. F., Gudbjarnason, S., Wendt, W. E., den Bakker, P. B. and Bing, R. J. (1961): Circulation, **24**, 1348.
- Olson, R. E. (1963): Ann. Intern. Med., **59**, 960.
- Dreyfus, J. C. and Schapiro, G. (1962): *Biochemistry of the Hereditary myopathies*. Springfield, Ill.: Charles C. Thomas.