

SOME OBSERVATIONS ON THE ACUTE ABDOMEN IN CHILDREN

MICHAEL KATZEN, M.B., B.CH. (RAND), F.R.C.S. (EDIN.), *Department of Surgery, University of the Witwatersrand, Johannesburg*

The pattern of the acute abdomen varies according to age. In infants and children it may be classified into the following groups:

(i) *Neonatal period* (up to 3 months of age). This is a highly specific group of cases and consists mainly of perforation or obstruction of the alimentary tract, usually due to congenital abnormality.

(ii) *3-12 months*. The predominant problem in this group is intussusception. Other surgical causes are uncommon and, as a rule, unusual in nature.

(iii) *1-3 years*. The acute abdomen is comparatively uncommon in this group, which is fortunate since the diagnosis is frequently difficult to make at this age. The cause is often 'medical' in nature. Acute appendicitis is not a common entity at this age.

(iv) *3-13 years*. Here the acute abdomen appears to fall into a fairly constant pattern and this review indicates the experience gained in this age-group at the Transvaal Memorial Hospital for Children, Johannesburg, over a 2-year period (November 1962-October 1964) and provides some observations made on these patients.

ANALYSIS OF CAUSES OF ACUTE ABDOMINAL PAIN

The series consisted of 285 White children aged 3-13 years admitted as emergency cases with acute abdominal pain as the predominant symptom. The cases were consecutive and unselected. Two groups of cases are specifically excluded, viz. (1) those with a history of abdominal trauma, and (2) non-emergency cases of recurrent abdominal pain admitted for investigation. Obviously, however, many patients in the series under review had a history of previous similar attacks of abdominal pain.

The final diagnosis in the 285 patients is depicted in Table I. It will be noted that approximately one-quarter

TABLE I. DIAGNOSIS OF CAUSE OF ABDOMINAL PAIN IN 285 CASES

	<i>No. of cases</i>
Acute appendicitis	64
Mesenteric adenitis	70
Gastroenteritis	18
Urinary tract infection	20
Primary peritonitis	4
Intestinal obstruction	5
Constipation	7
Miscellaneous	21
'Undiagnosed'	76
Total	285

of the patients suffered from acute appendicitis, approximately one-quarter had mesenteric adenitis and about one-quarter were discharged without a definite diagnosis being made. The series will be examined in more detail:

1. *Acute Appendicitis*

This diagnosis was proven in all cases by laparotomy

and histological examination of the appendix except for 4 patients who presented with an appendicular 'mass' or abscess and who were initially treated conservatively.

(a) *Age incidence*. The ages of the children with acute appendicitis are shown in Fig. 1 and compare well with the

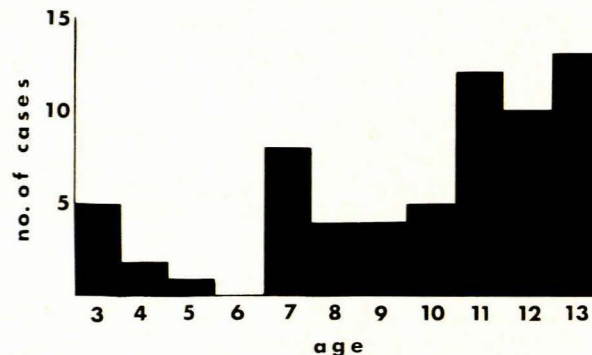


Fig. 1. Age incidence of acute appendicitis.

age incidence as reported by other authors.¹ It will be noted that appendicitis in children appears to be more common after the age of 11.

(b) *Monthly incidence*. This is depicted in Fig. 2 for the 2 consecutive years. It will be noted that during only one period




Fig. 2. Monthly incidence of acute appendicitis.

(August-September 1963) was acute appendicitis particularly common, and this was not the same in the previous year. It is the impression of many surgeons that acute appendicitis occurs 'in runs' 2 or 3 times a year. Though the numbers are small, this observation is not borne out by this series nor is it shown that 'runs' of acute appendicitis occur in association with virus epidemics as is commonly believed.

(c) *History*. An analysis was made of 5 factors in the history of patients suffering from acute appendicitis, viz. mid-line colic preceding the pain in the right iliac fossa, vomiting, diarrhoea, urinary symptoms and a history of previous similar attacks (Fig. 3).

A history of mid-line or generalized visceral pain at the onset of the attack appears to be not as frequent as that found in adults. This might be due to the difficulty in obtaining an

adequate history from children or possibly because a relatively larger proportion of acute appendicitis is catarrhal in origin in children as compared with adults.

Vomiting is a common symptom and nearly all those children without this symptom complained at least of nausea or anorexia.

Diarrhoea occurred in 2 phases: either in association with the visceral symptoms at the onset of the attack, making the distinction from gastroenteritis a difficult one, or 24-48 hours after the onset of the disease when it was always a sign of perforation.

Urinary tract symptoms and a history of previous similar attacks were no guide to the diagnosis of acute appendicitis.

(d) *Duration of symptoms.* The duration of symptoms of all cases of acute appendicitis at the time of admission is shown in Table II and this is compared with the duration of

TABLE II. SYMPTOMS IN ACUTE APPENDICITIS

Symptoms	% positive
Mid-line pain	64
Vomiting	80
Diarrhoea	21
Urinary tract symptoms	12
Previous attacks	17

symptoms of the cases in which the appendix was found to be perforated at laparotomy (one-quarter of all cases). It will be noted that the peak of duration of symptoms is approximately the same for the unperforated as for the perforated appendices and therefore, once the diagnosis of acute appendicitis is definitely made, operation should be performed as soon as possible.




Fig. 3. Duration of symptoms in acute appendicitis.

Since perforation occurred with histories as short as 12 or 18 hours, it is apparent that the disease may progress to an advanced stage before the appearance of symptoms.

(e) *Leucocyte count (WBC).* Table III indicates the WBCs

TABLE III. WBC IN ACUTE APPENDICITIS

WBC	% of cases
5 - 10,000	14
10 - 15,000	33
15 - 20,000	33
20 - 30,000	20

performed on 43 of the 60 patients with acute appendicitis who were operated upon. It will be noted that in 14% a normal WBC was found. Though a raised WBC may well be confirmatory evidence of acute appendicitis, it is evident that a normal WBC should never exclude the diagnosis.

(f) *Accuracy of diagnosis.* While 60 children were operated upon for acute appendicitis during the period under review, 27 children underwent laparotomy with a pre-operative diagnosis of acute appendicitis and the diagnosis was not confirmed at operation. In 2 of these cases primary streptococcal peritonitis was found and 1 case had a torsion of an ovarian remnant in the broad ligament. Thus the operation in these 3

cases was warranted. In the remaining 24 subjected to surgery, 11 were diagnosed as mesenteric adenitis at operation and in 13 no cause for the symptoms was found. The ratio of positive to negative explorations was therefore 5:2 which is certainly considered high in comparison with adults.

Perusal of the records of the 24 patients undergoing 'negative exploration' revealed 3 features which might have indicated that acute appendicitis was not the correct diagnosis, viz.: (1) Tenderness over the appendix was not always persistent and localized; (2) absence of 'visceral history'—a positive history of mid-line colic was obtained in only 28% of this group and vomiting was present in only 37% (see Table II); and (3) a normal WBC was present in 9 out of 17 cases in which the investigation was performed (see Table III).

Persistent and localized tenderness over the appendix is the best sign of acute appendicitis. However, if tenderness is present but no corroborative evidence is present in the form of a positive 'visceral' history or rise in the WBC then it is probably advisable that the patient be observed for a further period (say 2-4 hours) when the physical signs, notoriously variable in children, will be confirmed or a change in them noted.

That unnecessary laparotomy may be harmful was exemplified in 1 girl in this group, who underwent negative exploration and appendicectomy and developed wound-sepsis followed by transient intestinal obstruction. Presumably a low-grade peritonitis had occurred and this child now runs the risk of possible sterility and recurrent intestinal obstruction.

The risk of exploratory laparotomy is not inconsiderable and it should not be undertaken without a very good reason. The mortality of acute appendicitis (nil in this series) is acknowledged to be minimal provided children are referred to hospital early, and it is likely that today the dictum of 'when in doubt, open' should be changed to 'when in doubt, observe' provided the conditions for observation are adequate.

(g) *Appendicular 'mass' and abscess.* Five of the 64 children with acute appendicitis presented with a mass in the right iliac fossa at the time of admission. One child in whom the history was short underwent appendicectomy immediately. The other 4 were treated on conservative lines initially; in 2 the mass resolved and in 2 an abscess was drained. All 4 ultimately underwent interval appendicectomy.

It is impossible to say from this small series whether the advice of Bruce² that 'there is no defensible place for conservative treatment at any stage of classical acute appendicitis' is correct. It has been recommended that conservative treatment of the appendicular 'mass' or abscess is undesirable in the very young and probably the advice of Mason Brown³ that 'although in older children appendicular abscesses of several days' duration may be treated conservatively in some instances, there is virtually no place for delayed treatment in childhood and none in children under 5 years of age' is the correct line to follow.

(h) *Histological examination of the appendix.* In all 91 children who underwent appendicectomy the appendix was submitted for histological examination. In 2 instances unexpected pathology was found, viz. carcinoid in 1 and bilharzial infestation in the other. This represents unexpected pathology in 2.2% and certainly justifies this important examination.

2. Mesenteric Adenitis

The diagnosis of mesenteric adenitis was made on the following criteria:

- The presence of infection, viz. pyrexia, flushed face and suffused eyes.
- Tenderness in the right iliac fossa, usually shifting in nature and frequently extending to the umbilicus and left hypochondrium.
- The absence of signs and symptoms suggestive of any other diagnosis.

Of the 70 cases of mesenteric adenitis, 11 were confirmed at laparotomy. The diagnosis of mesenteric adenitis is a difficult one in many instances, often made retrospectively and by exclusion. We have applied our criteria strictly. The

associated signs noted in these cases are depicted in Table IV and indicate a high incidence of associated upper respiratory tract infection but a comparatively low incidence of associated extra-abdominal lymphatic involvement.

TABLE IV. ASSOCIATED FEATURES IN MESENTERIC ADENITIS

	<i>No. of cases</i>
Mild upper respiratory tract infection	21
Severe upper respiratory tract infection	19
Generalized lymphadenopathy	7
Lymphadenopathy + splenomegaly	2
Rash + lymphadenopathy + pharyngitis	1
No associated signs	20
Total	70

The WBCs found in these cases are shown in Table V. It will be noted that the WBC is considerably lower than

TABLE V. WBC IN MESENTERIC ADENITIS

<i>WBC</i>	<i>% of cases</i>
5 - 10,000	39
10 - 15,000	36
15 - 20,000	9
20 - 30,000	16

that occurring in acute appendicitis (see Table III). It might indicate that mesenteric adenitis is viral in origin in many instances.

There are 2 important observations regarding mesenteric adenitis in this series:

- (i) Two patients suffering from acute appendicitis had concomitant severe acute tonsillitis. If the abdominal signs are indicative of acute appendicitis one should not be persuaded to change the diagnosis to that of mesenteric adenitis because of associated upper respiratory tract infection.
- (ii) One case of mesenteric adenitis was readmitted to hospital 2 weeks later with acute rheumatic fever. I have also had experience of 2 other cases, 1 with rheumatic fever and 1 with acute glomerulonephritis following mesenteric adenitis. It is important to attempt to make a positive diagnosis of mesenteric adenitis, and if there is any doubt that it might be streptococcal in origin then an adequate course of penicillin should be prescribed.

3. Gastroenteritis

Eighteen children in this series were found to be suffering from gastroenteritis, including frank dysentery in some cases. The diarrhoea frequently made its appearance only after admission to hospital.

Twenty percent of the children with acute appendicitis in this series had diarrhoea. A high incidence of acute appendicitis during epidemics of gastroenteritis has been reported³ in which the same organism responsible for the gastroenteritis has caused the appendicitis. The distinction between these 2 diseases may therefore become increasingly difficult during an epidemic of gastroenteritis.

4. Urinary Tract Infection

Twenty children were found to have urinary tract infection as the cause of their acute abdomen. The criteria for the diagnosis were as follows:

- (a) General evidence of infection, viz. pyrexia or rigors.
- (b) Pain or tenderness in the loin or over the bladder.

(c) Dysuria.

(d) Positive microscopic and bacterial examination of the urine.

It might well be that by applying such strict criteria for the diagnosis some milder cases have been missed. Because of the difficulty of collecting uncontaminated urine in children (especially in girls) and the confusion which surrounds the assessment of urine examination, it is thought that many children will be saved extensive urological investigation with inadequate indications if these criteria are strictly applied. Should further attacks suggestive of urinary tract infection occur then further investigation is obviously indicated.

From the series under review it would appear that pain in the right iliac fossa is an uncommon mode of presentation of urinary tract infection.

The 20 children in this group included 16 girls and 4 boys. It is of note that an underlying urological abnormality existed in all 4 boys whereas it was present in only 5 of the 16 girls. It is common experience that urinary tract infection in boys is nearly always associated with an underlying anomaly but that in girls it frequently results from retrograde spread from the perineum.

5. Primary Peritonitis

There were 4 cases of primary peritonitis in the series—2 streptococcal and 2 pneumococcal in origin. The 2 cases of streptococcal peritonitis were indistinguishable from acute perforated appendicitis clinically and were subjected to laparotomy. The 2 cases of pneumococcal peritonitis were classical in presentation and were treated successfully along conservative lines.

It is noteworthy that several girls with acute appendicitis in this series suffered from a vaginal discharge which is not uncommon several months before the onset of menstruation. It is redundant to add that before a diagnosis of pneumococcal peritonitis is made in a child with an acute abdomen and a vaginal discharge, the presence of pneumococci in the discharge must be proven. This can be done by direct examination of a smear and there is no need to wait for the results of bacterial culture.

6. Intestinal Obstruction

The 5 children in the series with intestinal obstruction all presented in classical fashion and the obstructions were due to adhesions from previous surgery or peritonitis in every case.

The straight X-ray of the abdomen is the most valuable investigation in the exclusion or confirmation of intestinal obstruction.

7. Constipation

The 7 children in the series in whom the acute abdomen was considered to be due to constipation all had a long history of 'colonic inertia' and demonstrated a distended caecum and a rectum loaded with faeces. It is probable that several of the cases in the 'undiagnosed' group were examples of mild constipation.

8. Miscellaneous

The 21 cases in this group are listed in Table VI. The list includes many of the uncommon yet very important causes of the acute abdomen in children. The surgeon, though well aware of the endless variety of 'surgical'

causes of the acute abdomen, should also bear in mind the more common 'medical' and extra-abdominal causes not included in this list, e.g. Henoch-Schönlein purpura, referred pain from pericarditis, haemophilia, etc.

TABLE VI. MISCELLANEOUS CAUSES OF ABDOMINAL PAIN

Diagnosis	Remarks
1. Ovarian pathology (3)	'Mittelschmerz' (2) Torsion ovarian remnant (1)
2. Infective hepatitis (3)	Jaundice developed after admission
3. Acute duodenal ulcer (2)	
4. Iliac lymphadenitis (2)	Septic abrasions on right foot —both cases
5. Lobar pneumonia	
6. Septic arthritis right hip	
7. Haematocolpos	
8. Haemangioblastoma of liver	Haemorrhage into tumour under capsule
9. Lymphosarcoma	Involvement of mesenteric glands
10. Bornholm's disease	
11. Strangulated epigastric hernia	
12. Measles	Rash developed after admission
13. Encephalitis	Vomiting and distension main symptoms
14. Asthma	Torn fibres rectus abdominis
15. 'Munchausen's syndrome'	Simulated pain to gain hospital admission—unhappy home

9. 'Undiagnosed'

Of the 285 children in the series there were 76 who were discharged without a definite diagnosis being made. In many instances a tentative diagnosis was ventured, e.g. ? constipation or ? mesenteric adenitis, though never proven to our satisfaction, possibly because of the application of very strict criteria for each diagnosis. Laparotomy was undertaken in 13 of these 76 cases without assisting in the diagnosis.

In most instances these children had a transient illness lasting 24 - 48 hours characterized by not very severe pain predominantly in the right iliac fossa, mild pyrexia, equivocal pharyngitis and admitting to mild urinary or bowel symptoms often in response to leading questions. It is probable that if the diagnoses were possible in these cases they might prove to be mild cases of mesenteric adenitis, constipation, gastroenteritis or urinary tract infection in that order of frequency.

The sex incidence in these 76 cases was approximately equal for boys and girls, which excludes ovarian pain as

a likely common syndrome especially as very few of the girls had reached the menarche.

It is important to remember that some of these cases might well have been examples of subclinical appendicitis which resolved spontaneously. One child admitted during the period under review illustrates this well. He received a penetrating abdominal wound in the left iliac fossa after falling on a pencil. At laparotomy the pencil was found to have caused only a small tear of the peritoneum on the left side. Further exploration on the right revealed an acutely inflamed appendix and this was confirmed histologically. The child and his parents are both adamant that he had no symptoms suggestive of appendicitis before the accident. This suggests that appendicitis may be productive of no symptoms at all on occasion and probably many cases present with a very mild illness.

The follow-up of this group of cases has proved difficult. Of the 76 cases, 12 have had further admissions. Ten of these were admitted with similar episodes and extensive investigation, including laparotomy in 3 instances, failed to reveal the diagnosis. In only 2 cases readmitted was a diagnosis established—appendicitis in one case and urinary tract infection secondary to bilharzial ureteric stricture in the other.

It might well be that more intensive investigation would enable the cases in this 'undiagnosed' group to be diagnosed more accurately. Though many children appear to suffer from the syndrome of recurrent abdominal pain of unknown origin, the majority have had only a single attack which cleared spontaneously. It would seem to be unnecessary to subject this latter group to prolonged hospitalization and unpleasant and possibly hazardous investigation in the interests of diagnostic perfection. Should the attacks recur then further investigation is indicated.

SUMMARY

Some observations on the acute abdomen in children are presented, based on a review of 285 children between the ages of 3 and 13.

Observations are made particularly on the diagnosis of the acute abdomen and some aspects of its management. The 'undiagnosed' case is also discussed.

I wish to thank Mr. J. Wolfowitz, under whom all the cases were admitted, and Prof. D. J. du Plessis for their encouragement and advice in the preparation of this paper.

REFERENCES

1. Mason Brown, J. J. (1956): *J. Roy. Coll. Surg. Edinb.*, **1**, 268.
2. Bruce, J. (1964): *Practitioner*, **192**, 731.
3. White, M. E. E., Lord, M. D. and Rogers, K. B. (1961): *Arch. Dis. Childh.*, **36**, 394.