

PLACENTAL BILHARZIASIS

REPORT OF A CASE

J. C. SUTHERLAND,* M.D. (MARQUETTE), ANN BERRY,† M.B., B.CH. (RAND), MARGARET HYND,* M.B., CH.B. (GLASGOW), AND N. S. F. PROCTOR,† M.B., B.CH. (RAND), D.A.B.P., M.C. PATH., *Johannesburg*

It is not a common procedure in medical practice to submit specimens of placenta for histopathological examination. Recently, however, a placenta was received by the Department of Pathology at the South African Institute for Medical Research from the Ethel Lucas Memorial Hospital at Acornhoek in the Eastern Transvaal. This placenta had been found to contain bilharzial ova on direct microscopic examination of crushed unstained tissue.

*Ethel Lucas Memorial Hospital, Acornhoek, E. Tvl.

†South African Institute for Medical Research, Johannesburg.

The presence of ova of *Schistosoma haematobium* was later confirmed in histopathological sections. It would appear to be worth while recording such a finding since no detailed pathological descriptions of placental bilharziasis have appeared in the literature up to date.

Case Report

M.M., a Shangaan primigravida of about 19 years, came to hospital at 10 p.m. on 19 September 1964, in early labour. We had not seen her previously although she lives at Acornhoek.

She was admitted by a student midwife who recorded a blood pressure of 200/120 mm.Hg. Then a staff midwife saw the patient and recorded a blood pressure of 180/120 mm.Hg. The temperature was normal. The patient was given pethidine, 75 mg., with levallorphan, 0.937 mg., intramuscularly. At midnight the urine was tested by a staff midwife and no protein was detected either by heating or by adding sulphosalicylic acid. No oedema was noted then or later. At 2 a.m. the student midwives reported a seizure lasting 7 minutes. The blood pressure just afterwards was 122/90 mm.Hg. Another seizure occurred at 3 a.m. and the patient was given morphine sulphate, 10 mg., intramuscularly. At 11 a.m., after an additional 5 seizures, 10 ounces of urine were removed per catheter. A trace of protein was detected with sulphosalicylic acid. We then gave magnesium sulphate, 1 G, and sodium phenobarbitone, 180 mg., intramuscularly. Later an intravenous infusion of 10% dextrose in distilled water was started but was discontinued when the needle was dislodged during another seizure. The patient received about 200 ml. Two further seizures occurred that morning and early afternoon for a total of at least 10 since admission. One of us (J.C.S.) saw one of the afternoon seizures. It consisted of tonic and clonic contractions of the entire body which lasted 1-2 minutes and was followed by a light stupor. Many blood pressure determinations were made after the onset of the seizures and they varied from 110/70 to 140/110 mm.Hg. The foetal heart rate remained normal.

The cervix at 2.50 p.m. was completely effaced but only 1 finger dilated. We ruptured the membranes at this time and noted that the amniotic fluid was stained with meconium. Promazine, 25 mg., and magnesium sulphate, 1 G, were given intramuscularly. Because of recurring seizures and possibly foetal distress we did a caesarean section at 5 p.m. under general anaesthesia with ether, oxygen and nitrous oxide and extracted a viable 5 lb. 14 oz. male infant through the lower segment.

A chance comment was made in theatre about possible calcifications in the placenta. This directed attention to this organ and a small piece of tissue was pinched from the maternal surface with an Allis forceps, crushed between two glass slides and examined microscopically. There were 4 or 5 ova of *Schistosoma haematobium* present. The placenta was then put into formalin and sent to the South African Institute for Medical Research in Johannesburg.

The early postoperative course was uneventful, except for fever during the first 4 days. The highest temperature was 101.6°F. The blood pressure varied from 140/110 to 130/96 mm.Hg for 2 days, and by the third postoperative day it was normal and remained so. Urine was tested on the fifth postoperative day by an orderly. No sugar or bile could be detected, but there was a 1+ reaction for protein with heating. Ova of *S. haematobium* were seen microscopically. The patient was given luanthone hydrochloride and received 2.5 G in a period of 54 hours. Her weight was 90 lb.

On the tenth postoperative day the patient suddenly exhibited fever, 102.4°F, and had another seizure. We could only find pulmonary rhonchi on examination. The blood pressure was not recorded nor was the urine tested. An X-ray film of the chest, taken the next day, showed clear lungs and a normal cardiac shadow. The blood pressure was then 110/64 mm.Hg. Neither fever nor seizures recurred and the patient was discharged from hospital on 5 October—the 15th postoperative day.

Samples of blood from mother and child were sent to the SAIMR where no bilharzial complement-fixing antibodies could be detected. One specimen of the infant's urine was tested in hospital and no ova were seen in the centrifuged deposit.

The mother denied having had seizures before this episode.

Histopathological Report

The specimen received was a full-term placenta, the size and weight of which were within normal limits. Macroscopic examination showed no significant abnormality. A portion of one cotyledon had been previously removed, and fragments of this were received in a separate container.

Microscopic examination of tissue (selected from random sites) showed the histological features of normal placental tissue at term. In several of the sections, however, bilharzia ova were seen to be present lying scattered both in decidual tissue (Fig. 1), and among and actually within the structure of chorionic villi (Figs. 2, 3, 4, and 5). Two ova were seen to have terminal spines indicating the presence of *Schistosoma haematobium* (Fig. 6). Some ova contained mature miracidia, and a mild inflammatory infiltrate was noted around a group of these. Further sections of the umbilical vessels and of tissue in the immediate vicinity of their insertion were examined for the possible presence of schistosome worms with a negative result.

DISCUSSION

Whole organ digests with caustic potash have shown a fairly high incidence of bilharziasis of the female genital tract.¹ In fact Gelfand¹ has stated that in cases of urinary bilharziasis in women owing to *S. haematobium*, ova will probably be present in some portion of the genital tract. In Africa bilharziasis of the female genital tract is usually due to *S. haematobium*.²⁻³ The vagina and cervix are most often involved, followed by the uterus and then by the adnexae.¹ In South America, on the other hand, where the infecting species is *S. mansoni*, the adnexae are involved more frequently than the cervix and vagina.⁶ *S. japonica* very rarely infects the female genitalia, although Carpenter *et al.*⁷ recently reported 1 case and collected 2 others.

The Ethel Lucas Memorial Hospital is in the lowveld of the Eastern Transvaal. We often see ova of both *S. haematobium* and *mansoni* in urine and stools. The female genital tract is also frequently involved as shown by a study we made in 1959 and 1960. Then we took superficial scrapings with a cervical biopsy forceps from the external os of the cervix in 50 Bantu women in the childbearing age. All except 8 patients were from the lowveld of the Pilgrim's Rest district. All were patients undergoing some other pelvic procedure such as a uterine curettage, tubal insufflation or a forceps delivery. Three biopsy specimens were taken in all cases except 3 in which 2 were taken. The tissue was crushed with the corner of a glass slide, pressed between 2 slides and examined microscopically. Ova of *S. haematobium* were found in 28 (56%) of the 50 cases (Table I).

TABLE I. CERVICAL BIOPSIES FOR BILHARZIA OVA

Primary disease	No. of cases	No. of positive cases
Primary sterility	15	10
Secondary sterility	12	8
Incomplete abortion	10	6
Postpartum perineal repair	6	2
Forceps delivery	3	1
Retained products of conception	2	1
Postpartum inverted uterus	1	0
Cervical erosion	1	0
Totals	50	28

Bilharziasis of the body of the uterus has been reported far less frequently than of the cervix, if studies based on caustic potash digestion are excluded. Probably the first South African cases were the 2 reported by Te Groen⁸ in 1939. In both cases ova were found in endometrial scrapings. The species was not given. As late as 1943 Gilbert⁹ stated that no cases of endometrial bilharziasis had yet been reported in Southern Rhodesia, but accu-

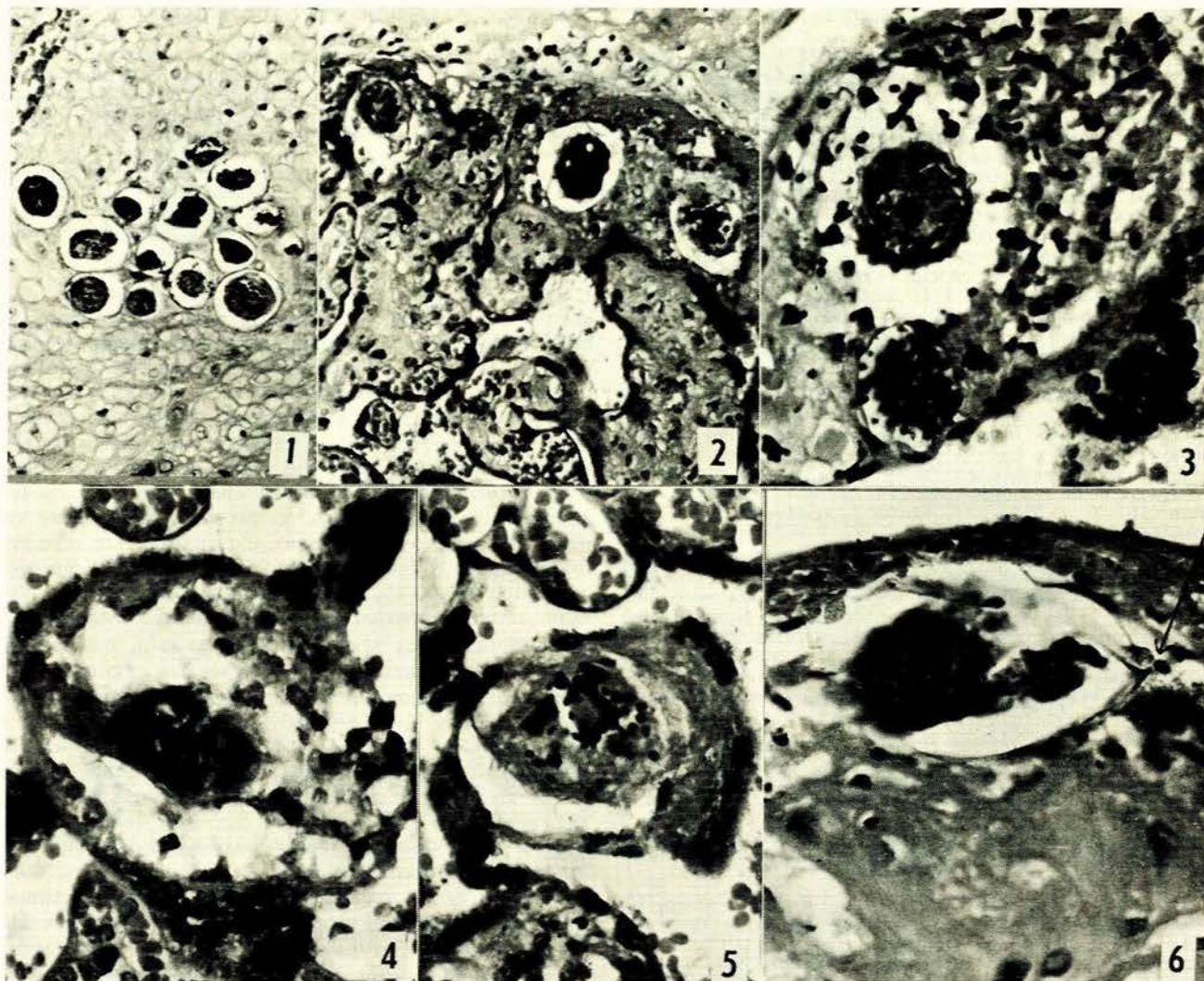


Fig. 1. Group of ova lying in decidual tissue (H & E x 400). Fig. 2. Five ova containing mature miracidia lying among chorionic tissue near maternal surface of the placenta (H & E x 200). Fig. 3. One group shown in Fig. 2 with cellular reaction round ova under a high-power lens (H & E x 480). Figs. 4 and 5. Ovum lying within the structure of a villus (H & E x 480). Fig. 6. Ovum with terminal spine in decidual tissue on maternal surface of placenta (H & E x 400).

rately predicted that such cases would be forthcoming when specimens were examined by the caustic potash digestion method. He also reported the finding of *S. haematobium* ova by digestion in the myometrium of 1 case and in a fibroid of another. Others since then have reported haematobia ova in fibroids^{5,9} and endometrium⁵ and ova, most likely haematobia, in the body of the uterus.³

A fair indication of the likely distribution of ova in human uteri can be had from Fairley's¹⁰ work with monkeys. After being in Egypt during World War I, Fairley artificially infected monkeys using cercariae of both species. No bilharziasis of the female genitalia was noted in the monkeys infected with *S. mansoni*. But in the haematobia group there was frequent involvement. Within the bodies of the uteri histologic changes were most prominent in the serosa and submucosa. Ova were described in the submucosal lesions, and adult worms in the vessels of the subserosa.

The paucity of ova in endometrial scrapings is probably due to its being shed with each menses.² Thus, one might expect more frequent involvement in the endometria of pregnant uteri with their increased vascularity and lack of shedding. At least 2 cases would suggest that this is true. Youssef and Abdine¹¹ found heavy concentrations of ova in the endometrium of a uterus which was studied during a caesarean section, and mentioned another case with ova in the cervix uteri. The species is not given. The placenta was not examined and there was no evidence that the foetus had been infected. Attia¹² has also described the finding of both bilharziasis of the pregnant uterus and cases of bilharzial endometritis. The species of schistosome was not stated. Schistosome worms have been found by previous workers in the cervix uteri,^{2,5,11} but no one has reported the finding of worms in any part of a pregnant uterus. It would have been of interest in this case to know whether the placental site was in the lower portion of the

uterus near the cervix where oviposition is known to take place.

In the placenta examined it would be difficult to judge from the microscopic findings how long the ova had been present—certainly long enough to cause a reaction in some areas, although ova are known to be present in tissues for considerable periods without related reactive changes. The majority of the ova were lying in the maternal decidual tissue or among villi immediately subjacent to it. Several ova were seen in the intervillous space between the chorionic villi, and 3 separate ova were seen actually within the structure of villi. The interesting point arises as to how they found their way to this position, and a possible explanation is that they had gained access to villi directly through the intervillous space by penetration of the thin outer covering of the villi. As ova are known to penetrate capillary walls, supporting connective tissue, and epithelium of bowel, bladder and female genital tract while gaining access to the exterior, the penetration of the wall of a villus would not seem to be an impossible feat. As pregnancy progresses and the placenta matures the structure of the villi changes.^{17,18} The syncytiotrophoblast is relatively thick during the first 4 months of pregnancy, but gradually becomes thinner as pregnancy advances until it forms a thin membrane in the later months. From the fourth month onwards the cytotrophoblast on the terminal villi dwindles, and eventually in the second half of pregnancy it is only exceptionally observed on thicker portions of the villi. As the capillaries in the stroma increase in size their walls eventually come into intimate relation with the syncytial membrane which itself becomes a thin layer with the nuclei gathered in irregular 'knots'. It is not difficult to envisage an ovum penetrating such a thin membrane, which in parts is known to be not more than 0.002 mm. thick and is the only barrier separating the maternal from the foetal blood (Fig. 7).

Another factor which could influence the passage of ova into the chorionic villi is the increased intra-uterine pressure during labour which must be transmitted through the blood in the intervillous space. One would expect the ova of *S. japonicum* to make such a passage more easily than the larger ova of *S. haematobium* and *S. mansoni*.

Ours is the first pathological description but not the first case of placental bilharziasis. Prates¹⁹ found ova in 5 placentas and, recently, *S. haematobium* ova in amniotic fluid.¹⁴ Transplacental infection of the foetus with *S. japonicum* has been reported¹⁵ (and from our findings would seem possible with *S. haematobium*). Prates,¹⁹ as long ago as 1948, drew attention to the fact that bilharzia could be a congenitally acquired disease. Early clinico-pathological studies would appear to be advisable on neonates in areas known to be heavily infested by bilharzia.

It seems that ova are not found in placentas because they are not looked for. Gelfand,¹⁶ for instance, admits not looking for ova in the placenta.

Caustic potash studies would probably be the method of choice for examining placentas as opposed to random sectioning of such a large organ which may well give false negative results.

The occurrence of epileptiform seizures in this case is of added interest. Occurring as they did for the first time

during labour and once after that on the 10th postpartum day, when the patient was pyrexial, 3 possible causes must be considered:

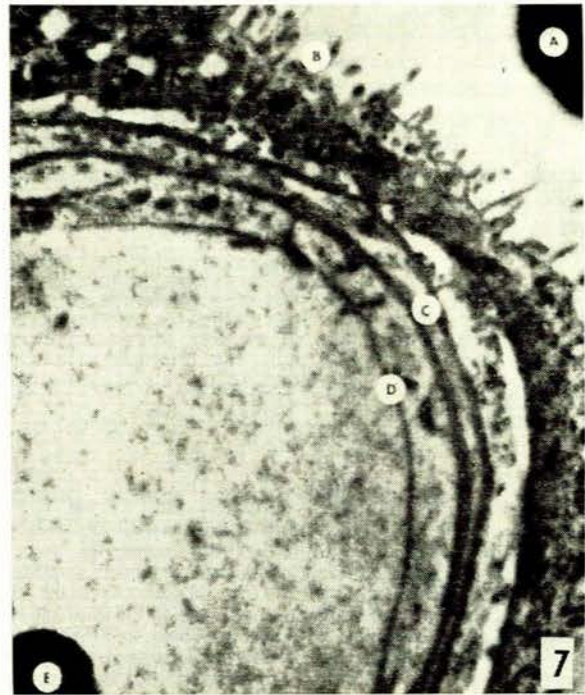

Fig. 7. Electron-microscopic study of tip of villus, at term. A = part of maternal red cell, B = brush border of syncytium, C = double layer of foetal connective tissue with fibrils between, D = endothelium of foetal capillary, E = part of foetal red cell (x 12,000) (Dr. E. W. Dempsey).

The first and most likely cause of the seizures is toxæmia of pregnancy with eclamptic fits. A second cause could be epilepsy *per se*, perhaps precipitated by the stress of labour. The fact that the patient gave no history of previous attacks is again not conclusive since the history given by such a patient is often unreliable. The presence of bilharzial ova or parasites in the brain should always be considered in a patient exhibiting epileptiform seizures when living in a heavily infested area and known to be passing ova in stools or urine. The relatively large size of uterine vessels during pregnancy approaching term and the mechanical effect of uterine contractions during labour could both be factors facilitating the passage of ova into unusual channels. Schistosomal involvement of the central nervous system with all 3 species is known to occur. Gelfand¹ has demonstrated ova of *S. haematobium* and less frequently of *S. mansoni* in digests of brain tissue of Africans known to have had bilharziasis. Marcial-Rojas *et al.*²⁰ review the world literature regarding bilharziasis of the central nervous system. They collected 60 cases from the literature of central nervous system lesions owing to *S. japonicum*, 25 of these with histologic proof. In 58 of these the symptoms were cerebral and in 13 there were epileptiform seizures. Eleven cases are reported caused by *S. haematobium*; 4 had cerebral symptoms, but no epileptiform seizures are reported and no histologic

proof is available. Twenty-eight cases of *S. mansoni* involvement are reported. Eleven of these had cerebral symptoms. In one patient complaining of vertigo, ova were found in brain sections at autopsy, and in another complaining of dizziness, ova were found in brain sections and adult parasites in the meninges. Another 3 had epilepsy, but no histologic proof was reported of the presence of schistosomal parasites or eggs.

These central nervous system cases illustrate the fact that bilharzia ova and even worms can be transported to areas far outside the portal caval venous circulation. And the present placental case reminds us that ova may be found in some unusual parts of the body.

SUMMARY

A case of placental bilharziasis has been described.

Further histopathological examination or caustic potash digestion studies of specimens of placenta from areas heavily infested by bilharzia is indicated. The question of possible intra-uterine infection of the foetus should also be considered and investigated.

The possibility of epileptiform seizures being caused by bilharziasis in this case is discussed.

We wish to record our thanks to the Director of the South African Institute for Medical Research and to Dr. T. H. Jones, Superintendent of the Ethel Lucas Memorial Hospital, Acornhoek, for permission to publish this paper. We wish to thank Mr. M. Ulrich, of the South African Institute for Medical Research Photographic Unit, for the photographs. The valuable assistance of Miss Frances Beckwith of the Medical School library at Marquette University, Milwaukee, Wisconsin, and Mrs. S. Hébert, of the South African Institute for Medical Research library, was gratefully appreciated.

ADDENDUM

Since this case one of us (J.C.S.) has been examining placentas by sodium hydroxide digestion for bilharzia ova. All placentas came from patients living in the lowveld. The usual procedure has been to take 5 cotyledons, 4 from points equidistant from each other at the margin of the placenta and 1 from the centre, and to digest these in 10% sodium hydroxide at approximately 37.5°C. The remainder of the placenta was then put into formalin. The time of digestion varied from 5 to 43 hours. From 1 to 35 ova were found in tissue from 7 placentas out of 21. *S. haematobium* ova were found in 5, *S. mansoni* ovum in 1 and ova of both species in 1. Usually there were only 1-6 ova identified, but in 1 case there were 27 ova of *S. haematobium* and 8 of *S. mansoni*. Most of the ova were light in appearance but a few were dark and obviously dead. Seventeen of the placentas came from normal deliveries. Two were placenta praevia, 1 marginal and 1 central, and no ova

were found in either. Another, also with no ova, came from a patient delivered by caesarean section because of accidental haemorrhage. The last placenta came from the only one of the group that exhibited any signs of pre-eclampsia. She had mild proteinuria and moderate oedema of her legs but no elevation of her blood pressure. Two *S. haematobium* ova, 1 light and 1 dark, were found in digests of her placental tissue.

Placentas from which ova were found by the digestion method were sent to the SAIMR, Johannesburg for histological section. Numerous sections were taken in each case (30 blocks) and were examined diligently (A.B.) but ova were found to be present in only 1 case further to the one reported, this case being one in which numerous ova of *S. haematobium* and a few ova of *S. mansoni* had been found previously on digestion. Again the ova were seen to be present in both decidua and within the structure of chorionic villi, and 3 ova present had terminal spines indicating the presence of *S. haematobium*. Mature miracidia were not seen in any of the ova and there was no associated reaction in these sections. The difficulty in demonstrating ova histologically indicates the superiority of the digestion method over the histologic method for practical purposes. On the other hand, especially where only 1 or 2 ova were present in the digestion fluid, one cannot exclude the possibility that these may have been extruded from the mucosa of the endocervix and merely adhered to the placenta as it passed through. To investigate this possibility the formalin in which the placental tissue was submitted was centrifuged and the entire deposit examined for ova in all such cases with a negative result.

The possibility of doing whole organ sections is at present being investigated, but the value of this method is uncertain as ova have frequently been found with no associated macroscopical or microscopical reaction.

REFERENCES

- Gelfand, M. (1950): *Schistosomiasis in South Central Africa*, p. 203. Cape Town: Juta & Co.
- Idem* (1949): *S. Afr. Med. J.*, **23**, 255
- Badawy, A. H. (1962): *Brit. Med. J.*, **1**, 369.
- Gilbert, B. (1943): *J. Obstet. Gynaec. Brit. Emp.*, **50**, 317.
- Charlewood, G. P., Shippel, S. and Renton, H. (1949): *Ibid.*, **56**, 367.
- Arean, V. M. (1956): *Amer. J. Obstet. Gynec.*, **72**, 1038.
- Carpenter, C. B., Mozley, P. D. and Lewis, N. G. (1964): *J. Amer. Med. Assoc.*, **188**, 647.
- Te Groen, L. J. (1939): *S. Afr. Med. J.*, **13**, 138.
- Mahfouz, N. (1949): *Op. cit.*¹¹
- Fairley, N. H. (1920): *J. Path. Bact.*, **23**, 289.
- Youssef, A. F. and Abdine, F. H. (1958): *J. Obstet. Gynaec. Brit. Emp.*, **65**, 991.
- Attia, O. M. (1962): *J. Obstet. Gynaec. Brit. Cweth.*, **69**, 334.
- Prates, M. (1948): *An. Inst. Med. trop. (Lisboa)*, **5**, 149.
- Idem* (1965): Personal communication.
- Narabayashi (1914): *Op. cit.*¹²
- Gelfand, M. (1965): Personal communication.
- Hamilton, W. J., Boyd, J. D. and Mossman, H. W., eds. (1962): *Human Embryology*, chapt. 5. Cambridge: Hetter.
- Novak, E. (1962): *Gynaecology and Obstetric Pathology*, 5th ed., chapt. 32. Philadelphia: W. B. Saunders.
- Marcial-Rojas, Rayl, A. and Fiol, R. E. (1963): *Ann. Intern. Med.*, **59**, 215.
- Ariizumi, M. (1963): *Amer. J. Trop. Med. Hyg.*, **12**, 40.