

## PROGRESS IN THE DIAGNOSIS OF PAINFUL LIMB SYNDROMES

H. ISAACS, M.B., B.CH., DIP. MED. (RAND), M.R.C.P. (EDIN.), *Lecturer, Department of Physiology; Research Assistant, Department of Medicine, University of the Witwatersrand Medical School; Part-time Physician, South Rand Hospital, Johannesburg*

This paper is concerned mainly with the syndromes of nerve compression, irritation or ischaemia. There have evolved, particularly over the last 30 years, 4 major aetiologies, the commonest condition at present being the carpal-tunnel syndrome in which the median nerve is compressed at the wrist.

### EVOLUTION

Putnam<sup>1</sup> recorded 31 cases with complaints of nocturnal paraesthesia in the distribution of the median nerves. Schultze<sup>2</sup> coined the term acroparaesthesia, describing pains and paraesthesia in the hands, mainly affecting middle-aged women. Gowers<sup>3</sup> spoke of inflammation of the brachial plexus; a spreading neuritis often originating in the intramuscular-septae of the neck and shoulder, with gout and rheumatism as predisposing causes. Kinnier-Wilson<sup>4</sup> thought that the paraesthesia resulted from nerve involvement at the thoracic outlet and described 2 syndromes:

- (a) Local wasting of the thenar eminence with radial side paraesthesia.
- (b) Generalized wasting in the small muscles of the hand. Vasomotor and trophic changes were also noted.

This period marked the start of the cervical rib witch-hunt.

Ochsner<sup>5</sup> introduced the concept of scalenus anticus spasm and this was further elaborated by Naffziger and Grant.<sup>6</sup> Eden<sup>7</sup> described compression of the neurovascular bundle between the clavicle and rib. Falconer and Weddell<sup>8</sup> described compression of the lower part of the brachial plexus by fibrous bands. Walshe *et al.*<sup>9</sup> doggedly pursued the cervical-rib clavicular syndromes and involved the subclavian artery as a contributing source of pressure on the outer fasciculi of the median nerve. In 1945 he wrote on the 'sagging of the shoulder girdle' as a cause of frequent brachial neuritis seen in women taking up manual work during the war years.

Stookey<sup>10</sup> broke new ground in 1940 by describing nerve root compression in the cervical region by herniation of the nucleus pulposus. Semmes and Murphy<sup>11</sup> postulated that lateral disc protrusion may account for many cases unsatisfactorily diagnosed as thoracic inlet syndromes. Frykholm<sup>12</sup> concluded that most cases of brachial neuralgia were of radicular origin and that compression was due to bony or cartilaginous masses as well as nuclear herniation. Brain *et al.*<sup>13</sup> made their contribution in 1947 and described the carpal-tunnel syndrome as we understand it today. Lindbloom<sup>14</sup> advanced our knowledge of sciatica by puncturing the intervertebral discs in the lumbar region.

Cloward<sup>15</sup> used cervical discography in 1958 in the diagnosis of ruptured discs and in 1959<sup>16</sup> demonstrated that the discs themselves were pain-sensitive and a major cause of pain in the neck, shoulders and upper arms.

### DIFFERENTIAL DIAGNOSIS

#### *Brachial Neuropathies*

The thoracic inlet syndromes have symptoms in common and often present with Raynaud's phenomenon. The muscular wasting found in long-standing cases involves all the small muscles of the hand since it is the C8 contribution to the brachial plexus which is commonly affected. Similarly the subjective sensory disturbance occurs frequently in the C8 dermatome. Objective evidence, on the other hand, is found most commonly over the area of skin supplied by T1, the altered sensation being usually a diminished appreciation of pinprick. The pain is relieved by rest and especially lying down so that the condition is not troublesome at night, an important feature when compared with carpal-tunnel compression. The pain of brachial neuralgia is frequently aggravated or precipitated by carrying a load such as a suitcase which pulls the shoulder down. Backward or downward movement of the shoulder, especially with deep inspiration, may obliterate the pulse at the wrist. This is an inconstant sign and occurs in a fair percentage of otherwise normal people. The pulse in other cases is obliterated by elevating the arm above the head to full extension. Tenderness over the insertion of the scalenus anticus is not an important diagnostic feature since it occurs in other conditions but has invariably been present in retrospective studies on successfully operated cases.

#### *Spinal Causes*

Nerve root involvement by any of the numerous causes, either by direct pressure or interference with blood supply or both, is characterized by pain, paraesthesia and muscular atrophy. In some cases the atrophy is early and marked, while in others it may be completely absent. Pain is the most constant feature, often severe and of root distribution. In the upper limb there is usually associated pain and stiffness in the muscles of the neck and shoulder region. The range of neck movement is often limited by muscle spasm, while movement and increased intraspinal pressure brought on, for example, by sneezing, may aggravate the pain. This aggravation by coughing, sneezing or straining is helpful when present but has unfortunately been absent in a high percentage of proven cases.

The myotatic responses are a most useful guide to localization, the reflex often being reduced or absent over the affected segment. More care and time should be paid to the eliciting of tendon jerks. The additional care will be rewarding and the haphazard sledge-hammer approach so widely practised is to be deplored.

In advanced cases or in those where the motor fibres bear the brunt of the pressure, muscle fasciculation, weakness and atrophy become prominent. The atrophy in such cases can usually be explained by single root involvement such as the universal wasting of the small muscles of the hand in C8 lesions.



An interesting sign present in a few cases with disc rupture and spinal compression is the shock-like sensation spreading down the spine following on acute neck flexion. This was originally described by Lhermitte in patients suffering from multiple sclerosis.

In addition to the presence of root pains where the cause is intraspinal, a careful search may show long tract signs such as loss of vibration, joint position sense and increased tone below the level of compression.

In recent years, following largely on the work of Cloward,<sup>15,16</sup> it has become obvious that the nucleus pulposus and related ligaments are in themselves pain-sensitive structures. In the case of the cervical region, irritation or stimulation of different parts of the disc causes pain to be referred to different muscles of the shoulder, scapula and upper arm regions. The pain under these circumstances is brought about by excessive involuntary muscular spasm and can usually be demonstrated by electromyography. The pain in such cases is brought about as a motor phenomenon; the afferent pathway of this abnormal response appears to be served by the sinu-vertebral nerve as demonstrated by Herlihy.<sup>17</sup> The progress in recognition of this previously overlooked aspect of disc pathology has gone hand in hand with the improved techniques for discography. The cervical spine is eminently accessible to discography and the technique has been described in detail by Cloward. Cervical muscle spasm is notoriously associated with intractable headache and already many such patients have found relief only after removal of the offending disc, as shown by Reitz and Joubert.<sup>18</sup>

#### CARPAL-TUNNEL SYNDROME

##### *Aetiological Considerations*

That the median nerve can be damaged by closed injuries at the wrists is well known, and going back in the literature it is noted that Paget,<sup>19</sup> in 1863, referred to a case with excessive new-bone formation following a fracture at the lower end of the radius. The compression resulted in paralysis of the thenar muscles and ulceration of the 2nd and 3rd fingertips.

The usual onset of compression at the wrist is quite insidious and occurs in one or all three of the following ways:

- (a) The tunnel gets smaller, e.g. arthritis, oedema or myxoedema.
- (b) The nerve swells, e.g. oedema or myxoedema.
- (c) The blood supply is interfered with.

Sunderland<sup>20</sup> described the topography of the median nerve in great detail, while Blunt<sup>21</sup> demonstrated the blood supply of the median nerve and describes the supply from 3 sources: (1) proximally from the median artery; (2) from a branch of the ulnar artery just proximal to the flexor retinaculum; and (3) distal to the flexor retinaculum from the superficial palmar arch. These branches ascend and are found lying over the anterior aspect of the nerve. The venous drainage follows the arterial supply.

Blunt points out that there is nothing in the local vascular architecture to suggest that the median nerve is particularly liable to ischaemia at the wrist. The nerve itself in the terminal 3 inches is largely fascicular and resistant to compression.

Bently and Schlap<sup>22</sup> demonstrated that peripheral nerves may obtain oxygen by diffusion from the surrounding tissues. In this respect the avascularity of the carpal-tunnel becomes an important issue since pressure on the nerve caused by dorsiflexion of the wrist, together with tension of the palmar and flexor tendons above or pressure from below occasioned by pressure on the palm of the hand, predispose towards ischaemia of the median nerve by occluding the arterial supply in these respective sites.

Carpal-tunnel syndrome occurs commonly between the ages of 40-60 years. This age group accounts for approximately 63% of the cases. The sex distribution is such that about 94% of cases occur in women, while in 30% the condition is bilateral. The dominant hand is most frequently affected.

##### *Associated Conditions*

1. *Pregnancy* predisposes only in so far that women knit more at this time, gain weight, sometimes excessively, and occasionally develop oedema.

2. *Acromegaly*. Acroparaesthesiae are common in acromegaly as shown by Woltman in 1941. The cause has frequently been found to be due to carpal-tunnel compression of the median nerve.

3. *Myxoedema*. Carpal-tunnel syndrome occurs frequently in myxoedema, as shown by Murray and Simson,<sup>23</sup> who found carpal compression in 26 out of 28 myxoedematous patients. One must be careful about interpreting results here based on nerve conduction at the wrist, since nerve conduction generally becomes very slow in this condition.

##### *Misleading Features*

Pain may be felt in all 5 fingers and often extends up to the elbow and even the shoulder region. This has in the past often led to an erroneous diagnosis of thoracic inlet compression.

This problem of the bizarre pain distribution has been studied by various people including Brain,<sup>24</sup> who suggested that oedema of the cord was the underlying mechanism, and emphasized that dermatomes and myotomes do not overlap and in this way may widen the area of pain appreciation. My feeling is that the mechanism is probably simpler than this, as certainly is the case in patients where the cause is away from the spine itself; oedema of the cord is difficult to imagine. It is likely that the basis of poor localization is based on local spinal interneuronal effect whereby the excitability of adjacent levels of the cord is enhanced. This area of low threshold then reacts abnormally to normal afferent impulses and gives rise to pain. An analogous situation is seen in the Schiff-Sherrington phenomenon.

The relative frequency of various causes of upper limb pain of nerve compression-irritation origin are as follows: carpal-tunnel 51%, spinal group 30%, brachial plexus 4%, and miscellaneous group 15%. A large proportion of the miscellaneous group, however, will, as discography becomes more frequently used, fall into the spinal group while others become obvious cases of disseminated sclerosis.

*Multiple sclerosis*. It is opportune to stress that this is by no means a rare condition in this country and may present for the first time as pain in one or more limbs. The



multiplicity of symptoms at the onset and the passage of time show the true nature of this disease.

#### ELECTRODIAGNOSTIC AIDS

##### Electromyography

By these methods the electrical accompaniment of muscular activity is both visualized, photographed, heard and recorded on tape, if necessary. In few other fields of investigation does the interpretation of the results depend so much upon the experience of the examiner. There is no place for the occasional operator and experimenter. Their opinions confuse difficult issues and may lead to scepticism as to the value of the procedures.

Concentric needle electrodes are inserted into the muscles in one or more places. Often the muscle has to be explored with the needle before an inflammatory myositic patch or denervated bundle of fibres is located. Electromyography helps to distinguish the painful dystrophies<sup>25</sup> with short duration low-voltage motor unit activity, from the rapidly fatiguing muscle of polymyositis,<sup>25</sup> from denervation characterized by depletion of motor unit activity on contraction, and from spontaneous denervation activity at rest. Abnormalities will frequently be found well in advance of abnormal histology and in most cases the interpretation is less confusing.

##### Nerve Conduction Studies

1. *Velocity.* Both motor and sensory conduction can be calculated over measured lengths wherever the nerve becomes superficial for part of its course. In the upper limb, conduction can be measured from the supra-clavicular region to the level of the wrist. Compression of the nerve causes a slowing or holdup over the area of compression and, if severe, nerve conduction in the distal part of the nerve will be slowed down. This last feature is seldom found since all that is needed are a few surviving fast fibres to keep conduction in the distal segment at normal velocity. One of the present limitations of measuring conduction velocity is the fact that only the fast conducting fibres are studied (Fig. 1).

The observation of slowing of conduction over the region of compression has been particularly useful in studying and confirming the carpal-tunnel syndrome. With the aid of various additional techniques, such as examining conduction in an experimentally produced ischaemic limb<sup>26</sup> and limiting the voltage of the stimulus to threshold level,<sup>27</sup> a positive objective diagnosis can be made in more than 80% of the patients with carpal-tunnel compression. It has been my policy to regard such objective evidence as an indication for operation. Operation is seldom necessary in the remainder since the majority respond rapidly and often permanently to splinting.

2. *Amplitude.* Studying the amplitude of the nerve potential is yet another approach to confirm or deny the integrity of the peripheral nerve, and this technique is yielding interesting information in various forms of peripheral neuropathy.<sup>28</sup>

3. *Strength duration curves.* These are graphs plotted of the threshold depolarizing stimuli of the nerve at the motor end point using usually a square pulse plotted against varying durations of this pulse. This is a time-honoured technique within the capability of all physio-

therapists, and the apparatus is inexpensive. As the muscle becomes slowly denervated the voltage required to depolarize the nerve, especially with a short duration pulse, becomes much greater. This is a useful way of following the denervation and recovery of a muscle.

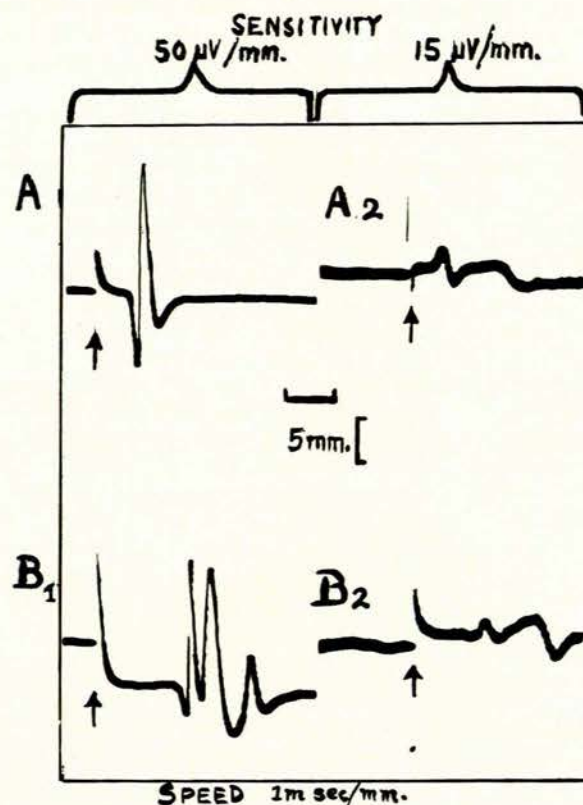


Fig. 1. A1 and 2 represent the motor unit activity of the flexor pollicis brevis and sensory nerve potentials recorded from the middle finger respectively. These responses were obtained following stimulation of the median nerve at the wrist while B1 and 2 follow stimulation of the same nerve at the elbow. Arrows indicate the stimulus artifact.

#### SUMMARY

The evolution of the understanding of painful limb syndromes has been followed up to the present time.

In many cases the cause may be clear-cut, but an unfortunately large group remains where the diagnosis is obscure. Four main aetiological groups have been suggested and discussed. It is hoped that with acceptance of discography to the radiological equipment and the intelligent use of the various electrodiagnostic techniques, diagnostic confusion will be greatly reduced and unnecessary surgery avoided. It is stressed that all these techniques, taken in conjunction with histology, have their limitations. It is only by studying each patient as an individual with a special problem, using the diagnostic aids as a guide, that we come closest to the truth most frequently in the greatest number of patients.

#### REFERENCES

- Putnam, J. J. (1880): Arch. Med. (N.Y.), 4, 147.
- Schultze, F. (1893): Dtsch. Z. Nervenheilk., 3, 300.
- Gowers, W. R. (1899): *A Manual of Diseases of the Nervous System.* London: Churchill.
- Kinnier-Wilson, S. A. (1913): Proc. Roy. Soc. Med., 6, 133.
- Ochsner, A., Gage, M. and De Bakey, M. (1935): Amer. J. Surg., 28, 669.
- Naffziger, H. C. and Grant, W. T. (1938): Surg. Gynec. Obstet., 67, 722.
- Eden, K. C. (1939): Brit. J. Surg., 27, 111.
- Falconer, M. A. and Weddell, G. (1943): Lancet, 2, 539.
- Walshe, F. M. R. et al. (1944): Brain, 67, 141.

10. Stookey, B. (1940): Arch. Surg., **40**, 417.
11. Semmes, R. E. and Murphy, F. (1943): J. Amer. Med. Assoc., **121**, 1209.
12. Frykholm, R. (1951): Acta chir. scand., Suppl. 160.
13. Brain, W. R., Wright, D. and Wilkinson, M. (1947): Lancet, **1**, 277.
14. Lindbloom, K. (1948): Acta orthop. scand., **17**, 231.
15. Cloward, R. B. (1958): Amer. J. Roentgenol., **79**, 563.
16. *Idem* (1959): Ann. Surg., **150**, 1052.
17. Herlihy, W. F. (1949): N.Z. Med. J., **48**, 214.
18. Reitz, H. and Joubert, M. J. (1964): S. Afr. Med. J., **38**, 881.
19. Paget, J. (1863): *Op. cit.*<sup>29</sup>
20. Sunderland, S. (1945): Brain, **68**, 23.
21. Blunt, M. J. (1959): J. Anat. (Lond.), **93**, 15.
22. Bently, F. H. and Schlapp, W. (1943): J. Physiol. (Lond.), **102**, 62.
23. Murray, I. P. C. and Simson, J. A. (1958): Lancet, **1**, 1361.
24. Brain, W. R. (1948): Proc. Roy. Soc. Med., **41**, 509.
25. Isaacs, H. (1965): In preparation.
26. Fullerton, P. M. (1963): J. Neurol. Psychiat., **26**, 385.
27. Preswick, G. (1963): *Ibid.*, **26**, 398.
28. Gilliatt, R. W. and Wilson, R. G. (1962): *Ibid.*, **25**, 11.
29. Kendall, D. (1960): Brit. Med. J., **2**, 1633.
30. Woltman, H. W. (1941): Arch. Neurol. Psychiat. (Chic.), **45**, 680.