

## INTRA-UTERINE SYNECHIA

J. ADNO, M.B., B.CH., DIP. O. & G. (RAND), *Department of Obstetrics and Gynaecology, University of the Witwatersrand*

Traumatic intra-uterine lesions were described as far back as 1894.<sup>7</sup> Since then sporadic accounts have occurred in the literature, and lately the condition has become more prominent, most probably because of the more thorough investigation in the cases of infertility.

Trauma to tissues, either of mechanical or of inflammatory nature, is likely to cause scarring and agglutination of surfaces. This might be in the form of a very fine fibrinous adhesion or gross fibrotic tissue formation.

Damage to the lining of the female genital tract can cause adhesions, e.g. closure of the tubes as a result of salpingitis; conglutination of the cervix after electrical coagulation; and stenosis of the vagina with formation of severe keloid and cartilaginous scarring as seen in the Bantu. It has been a custom for women in Arabia to apply corrosives to the vagina after delivery in order to reduce it to its previous size.<sup>8,18</sup>

It is thus not surprising to note that intra-uterine adhesions, if looked for, are a fairly common entity. Nevertheless Moore-White and Green-Armytage<sup>21</sup> state that this condition is rare.

Post-traumatic intra-uterine lesions were first described by Fritsch<sup>7</sup> in 1894. The patient developed amenorrhoea after postpartum curettage, and at hysterectomy the uterine cavity was found to be occluded.

The following year Veit<sup>20</sup> published a similar case. Bass<sup>4</sup> in 1927 described a series of 20 women with stenosis of the isthmus, found among a total of 1,500 Russian women in whom abortion had been induced. This series dates from the time when induction of abortion was legal in Russia.

Since then a few series of cases have been published—Stamer<sup>15</sup> 24 cases; Hald<sup>10</sup> 22 cases; and Netter<sup>18</sup> 50 cases. In 1948 Asherman<sup>1</sup> coined the term amenorrhoea traumatica (atretica) in cases of severe cervical stenosis following on trauma by either childbirth, abortion or curettage.

In 1957 Asherman<sup>3</sup> published a series of 150 cases. This is the largest series to date and the syndrome associated with intra-uterine adhesions (synechiae) is often referred to by his name. A further 57 cases were published by Bergman<sup>5</sup> in 1961. Rabau and David<sup>14</sup> stated recently that they had seen 30 cases comprising 5% of the hysterographies done for repeated and habitual abortion.

*Aetiology of the Condition*

The operation carrying the greatest risk and causing the most severe injuries was curettage after delivery.<sup>3</sup> Asherman<sup>2</sup> states that the incidence of synechiae following curettage for missed or septic abortion is much greater than when done for a fresh abortion. The curettage of old, organized placental tissue, usually infected, injures the uterine wall to a much greater extent.

In the present series 5 cases followed on curettage for secondary postpartum haemorrhage, 1-21 days respectively, after delivery. The other cases were those following repeated curettage done for recurrent abortions and in 1 case for recurrent menorrhagia. Case 10 could not be explained satisfactorily.

*Pathology*

Tissue bridges produce defects in the uterine cavity. The more severe the trauma the thicker and more dense the tissue. This tissue usually consists of fibromuscular elements.

In Bergman's series the majority of the patients with amenorrhoea had an inactive endometrium. The endometrial picture varies considerably from an inactive, atrophic glandular pattern to that of a normal tissue.

In case 1, at commencement of treatment, no glandular tissue was obtained at curettage or subsequently at endometrial biopsy. Fragments of fibromuscular tissue were seen on microscopy.

On cyclical therapy the picture gradually improved and the patient ovulated twice before conception. Most of the other patients showed atrophic or poorly developed endometrial glands and poorly differentiated stroma.

*Symptomatology*

The symptomatology varies with the degree of trauma. In mild cases there may be no symptoms at all, and the condition is diagnosed accidentally while investigating infertility or recurrent abortion.

In the severe cases amenorrhoea is common. This is understandable as the uterine cavity may be completely occluded as in case 1, or the remaining endometrium becomes inactive.

Asherman described the term amenorrhoea traumatica where the cervical canal was occluded completely. This is

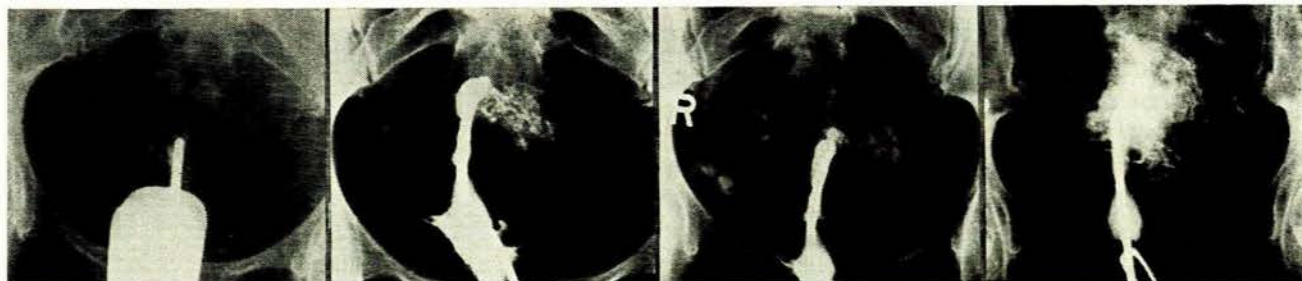


Fig. 1. Case 1. The minute uterine cavity before dilatation is shown.

Figs. 2-4. Case 1. The larger cavity after dilatation with extravasation of dye is shown.

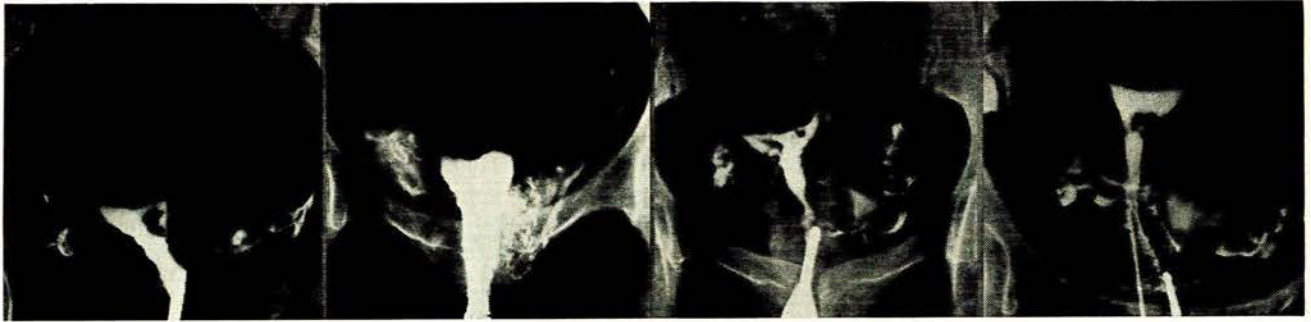


Fig. 5. Case 2. Before dilata-  
tion.

Fig. 6. Case 2. After dilata-  
tion.

Fig. 7. Case 3. See Table I. Fig. 8. Case 5. See Table I.

nearly always associated with atrophic endometrium and, of course, amenorrhoea.

Infertility may be due to the mechanical obstruction of the cervical canal or the uterine cavity, or the associated anovulation which is encountered.

Oligomenorrhoea is frequently complained of. Dysmenorrhoea was described in 15 of Bergman's cases. Some of these were associated with adenomyosis. In the present series only 2 patients had painful menstruation.

#### Diagnosis

The diagnosis may be suggested by the history, e.g. amenorrhoea, hypo- or oligomenorrhoea. History of recurrent curettage or curettage following an advanced pregnancy, especially after a secondary postpartum haemorrhage, may be predisposing factors.

Stenosis or conglutination of the cervical canal can be detected by instrumental exploration.

The confirmation is by hystero-gram. The condition is sometimes diagnosed on routine hystero-graphic examination for sterility or habitual abortion. The hystero-gram shows filling defects and deformation of the outline of the uterine cavity (Figs. 1-11).

Submucous myomata or polyps may produce a similar picture. Endometritis may also complicate the picture. Bicornuate uterus or subseptate uterus may be simulated, but one usually finds that the defect spreads down asymmetrically and is bizarre as compared with the average septum found in these conditions. Air or mucus in the uterine cavity can simulate a filling defect but then this is not usually a constant shadow as in the abnormality caused by the adhesion.

#### TREATMENT

##### Conservative

Two forms of treatment can be adopted. The first, or more conservative form of treatment, is that of dilating the stenosed canal from below. If the canal is not affected it should still be gently dilated and the uterine cavity is gradually dilated by using sweeping movements of a dilator.

Case 1, where no real uterine cavity was demonstrated,

was treated in this way (Figs. 1-4). The patient subsequently conceived but threatened to abort at 14 weeks. She was treated conservatively and then at 31 weeks her membranes ruptured, and a caesarean section was done 1 week later because of a transverse lie. At the operation it was found that the infant was lying in the transverse position and the lower portion of the uterine cavity was obstructed by a large bar of fibromuscular tissue. By placing the finger behind this bar the cervix could be detected below it. She made an uneventful recovery and the infant did very well. She has subsequently menstruated normally.

Asherman<sup>3</sup> states that curettage is ineffective and claims that the best and safest approach is by laparotomy. He says that the vaginal approach may be used but that the danger of perforating the uterus exists.

I suggest that the abdominal approach may be used as a last resort and only after the more conservative vaginal approach has failed. After operation the routine use of antibiotics, proteolytic enzymes and oestrogen therapy are suggested.

*Strassmann operation for intra-uterine synechiae.* Strassmann,<sup>16</sup> in 1930, performed the operation *per vaginam*. He made a transverse incision in the fundus through which he subsequently drew the fallopian tube, severed at the isthmus but still attached to its mesosalpinx. Then, after making a long, vertical incision in the fundus and the cervix anteriorly, and by excising the synechiae he formed a tunnel through which to draw the tube, which was then secured by catgut stitches both to the cervix and the fundus. All 6 of his operations were successful in that regular menstruation was established. One woman who tried to become pregnant, successfully conceived and carried to term.

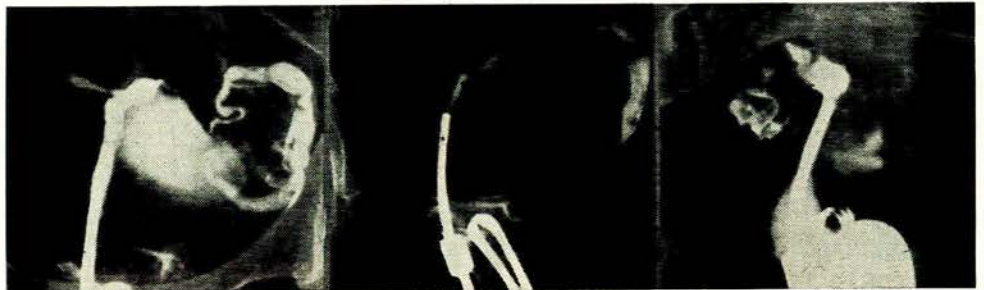

Fig. 9. Case 6. See Table I. Fig. 10. Case 6. Lateral view. Fig. 11. Case 7. Anteroposterior view.

*Laparotomy*

The second method of treatment which is advocated is by laparotomy. Strassmann jnr.,<sup>17</sup> in 1961, first used an abdominal approach. A vertical incision is made in the anterior aspect of the uterus extending to and into the internal os. The synechiae are excised. The fallopian tube is excised at the cornu and then reimplanted into the uterine wall. The degree of success after such an operation is not very great, although Von Mikulicz-Radecki<sup>18</sup> and Frommolt<sup>9</sup> report the birth of a live baby, following this procedure.

## PROGNOSIS

This depends upon the severity of the case. When minor adhesions are present the prognosis is good even without therapy. With severe lesions the prognosis is less favourable, although case 1 demonstrates that no case is too advanced to be treated *per vaginam*.

The cases treated up to the present are summarized in Table I.

## DISCUSSION

Traumatic intra-uterine lesions, though relatively rare, occur more commonly than is thought.

The lesions may cause sterility, abortion, decreased menstrual bleeding and painful menses. Retained placenta and placenta accreta following on delivery have been shown to occur by Manning and Pavey<sup>21</sup> and by Delforge.<sup>6</sup>

The possibility of helping these patients depends upon the severity of the condition and of the underlying original pathological state responsible for the aetiology. It is, however, agreed that prophylaxis is of greater benefit than therapeutic measures can be. Full-term pregnancies can occur in spite of severe deformities of the uterus, but the incidence of unfavourable presentations and caesarean section is high. Correction of malpresentation should be strictly prohibited.

## SUMMARY

A review of the literature regarding intra-uterine adhesions is recorded. Eleven cases of intra-uterine traumatic lesions are summarized in Table I. The aetiology, pathology, treatment and prognosis are discussed.

## ADDENDUM

Since this article was submitted to the *Journal* for publication, the patients reported on as cases 2, 3 and 6 have had the following subsequent histories: Case 2: The patient has had

TABLE I. DETAILS OF PATIENTS TREATED FOR INTRA-UTERINE SYNECHIA

Case no.	Age	Pregnancies	Complaints	Aetiology	Treatment
1	30	Para 2, gravida 2	Periods of amenorrhoea and oligomenorrhoea	D. & C. 10th day postpartum and then amenorrhoea for 9 months. On investigation no real uterine cavity (Figs. 1-4)	Canal and uterus dilated from below. Cyclical therapy of oestrogen and progesterone. Pregnancy. Threatened to abort at 14 weeks. Premature ruptured membranes at 31 weeks. Transverse lie. Band of muscle in lower segment. Infant 3 lb. 12 oz. Survived. Subsequent normal menses
2	30	Para 1, gravida 4	One traumatic abortion with 3 repeated abortions D. & C.'s	3 D. & C.'s	Dilated from below. Ovulatory endometrium. Successful pregnancy. Caesarean section at term for antepartum haemorrhage, placenta praevia and foetal distress. Infant 8 lb. 6 oz. Placenta membranacea. Uterus normal. Normal periods. Again pregnant
3	22	Gravida 2	Two abortions and D. & C.'s at 11-12 weeks	2 D. & C.'s	Dilated from below. Subsequently 2 normal deliveries at term. Normal placentas
4	31	Para 2, gravida 5	Oligomenorrhoea	3 induced abortions before birth of children. D. & C. 1959 for retained cotyledon after normal delivery. D. & C. June 1961, retained cotyledon 3 weeks postpartum	Dilated from below and now has normal periods with normal loss. Ovulatory endometrium
5	43	Para 2, gravida 5	Repeated abortions	Two D. & C.'s	Hypoplastic endometrium. Dilated from below. No further pregnancies
6	25	Para 2, gravida 2	Oligomenorrhoea and dysmenorrhoea	Postpartum haemorrhage first delivery with D. & C. Postpartum haemorrhage second delivery. D. & C. 3 weeks later	Dilated from below. Normal periods and pain gone. Normal ovulation. Again pregnant
7	31	Para 1, gravida 1	Oligomenorrhoea and dysmenorrhoea	Postpartum haemorrhage and secondary postpartum haemorrhage on 21st day. D. & C. done	Dilated from below. Not a very good result. Periods still scanty and a little painful. Hypoplastic endometrium
8	27	Para 2, gravida 2	Infertility and oligomenorrhoea	Postpartum haemorrhage. D. & C. on 22nd day	Dilated from below. Ovulatory endometrium. Obtained subsequent normal menses
9	21	Gravida 3	Recurrent abortions	Three D. & C.'s	No treatment
10	25	Gravida 0	Infertility	?	D. & C.
11	32	Para 2, gravida 2	Menorrhagia	?	Accidental finding at hysterectomy

a full-time, normal delivery with a normal placenta and third stage. Case 3: The patient aborted at about 8 weeks and required a curettage. Case 6: The patient had a full-term, normal delivery, but the third stage was complicated by placenta accreta, and this had to be removed manually.

I should like to thank the Photographic Unit, Department of Medicine, University of the Witwatersrand, for the photographs.

## REFERENCES

1. Asherman, J. G. J. (1948): *J. Obstet. Gynaec. Brit. Emp.*, **55**, 23.
2. *Idem* (1950): *Ibid.*, **57**, 892.
3. *Idem* (1957): *J. Reprod. Fertil.*, **2**, 49.
4. Bass, B. (1927): *Zbl. Gynäk.*, **51**, 227.
5. Bergman, P. (1961): *Acta obstet. gynec. scand.*, suppl. **4**, 40.
6. Delforge, A. (1959): *Bull. Soc. roy. belg. Gynec. Obstét.*, **29**, 282.
7. Fritsch, H. (1894): *Zbl. Gynäk.*, **12**, 1337.
8. Frith, K. J. (1960): *J. Obstet. Gynaec. Brit. Emp.*, **67**, 82.
9. Frommolt, G. (1959): *Zbl. Gynäk.*, **81**, 1025.
10. Hald, H. (1949): *Acta obstet. gynec. scand.*, **28**, 169.
11. Manning, R. E. and Pavey, C. W. (1959): *Obstet and Gynec.*, **14**, 793.
12. Moore-White, M. and Green-Armytage, V. B. (1962): *The Management of Impaired Fertility*, p. 168. London: Oxford University Press.
13. Netter, A. (1956): *Amer. J. Obstet. Gynec.*, **71**, 368.
14. Rabau, E. and David, A. (1963): *Obstet and Gynec.*, **22**, 626.
15. Stamer, S. (1946): *Acta obstet. gynec. scand.*, **26**, 263.
16. Strassmann, P. (1930): *Zbl. Gynäk.*, **52**, 2626.
17. Strassmann, E. O. (1961): *Clin. Obstet. Gynec.*, **4**, 240.
18. Underhill, B. M. L. (1964): *J. Obstet Gynaec. Brit. Cwlth.*, **71**, 293.
19. Von Mikulicz-Radecki, R. (1959): *Zbl. Gynäk.*, **81**, 1838.
20. Veit, J. (1895): *Zbl. Gynäk.*, **13**, 968.