

# ACUTE PEPTIC ULCERATION ASSOCIATED WITH ACUTE HAEMATOGENOUS OSTEOMYELITIS

D. R. DE VILLIERS, M.Sc.(PHYSIOL.), CH.M., *Department of Surgery, University of Cape Town and Grootte Schuur Hospital, Cape Town*

'The stomach is affected by injuries in parts of the body which have no connection with nutrition.'

John Hunter (1728-1793)  
*Principles of Surgery*, chapt. V.

Acute peptic ulceration has been recorded in a wide variety of circumstances, such as accidental and operative trauma, burns ('Curling's ulcer'), central nervous system lesions ('Cushing's ulcer'), shock, anoxia, massive infections, severe temperature changes, fractures, myocardial infarction, hypertensive heart disease, severe muscular exertion and fatigue, X-radiation and the use of certain drugs. In most of these circumstances, stress appears to be a common factor in acute ulcer formation.

Although it has been noted that acute ulceration can occur in conjunction with massive infections, a review of the literature failed to produce any recorded evidence of such ulceration complicating acute haematogenous osteomyelitis. It is the purpose of this paper to record 3 such cases of acute ulcerations occurring in conjunction with acute osteitis, presenting either with massive gastrointestinal bleeding and/or acute free perforation.

## CASE REPORTS

### Case 1

A.C., Coloured male, 15 years. Six days before admission the patient had eaten tinned crayfish, which was followed by the appearance of a generalized urticarial rash. The next day he developed 'lameness' in the left upper thigh, later experiencing pain in this region. On the following day the pain increased in intensity and was associated with hip flexion. On the morning of this day abdominal pain ensued, initially sited in the left iliac fossa, and gradually radiating over the entire abdomen. That evening the pain became especially severe, and was sited maximally in the right upper quadrant. Initially intermittent and stabbing in nature, the pain became continuous, aggravated by ingestion of food and was associated with vomiting in the evening. The vomitus consisted of ingested food and bile-stained material. Vomiting occurred on 2 subsequent occasions over the course of the next day, associated with complete anorexia. Micturition at this stage was associated with dysuria. On the 2nd day before admission abdominal pain, pyrexia, rigors and left hip pain persisted. On the day before admission the doctor was called who, on examination, found him to be pyrexial (102° F) and toxic, and also noted a generalized giant urticarial rash. On abdominal examination, distension, absent bowel sounds and the features of generalized peritonitis were recorded. Restricted movement was noted in the left hip. Subcutaneous adrenaline and an antihistaminic drug were administered, combined with oral broad-spectrum antibiotic. The next day his condition was unchanged except for complete disappearance of the urticarial wheals; admission to hospital was arranged.

On examination in the ward the patient was found to be extremely ill and toxic, markedly dehydrated, and an erythematous rash was noted covering the whole body. Generalized lymphadenopathy was noted and the temperature was recorded at 104° F. Tachycardia (140/min.) and tachypnoea were also obvious. On chest auscultation, the presence of bilateral pleural friction rubs were noted. Examination of the abdomen showed distension, diffuse tenderness with positive release sign, some rigidity and the presence of an enlarged liver, combined with the presence of free intraperitoneal fluid. Rectal examination confirmed tenderness maximal on the left side, deep to levator ani, but no definite palpable mass could be determined. Tenderness was also noted over sacrospinous and sacrotuberous ligamentous origins. Local examination of the left hip joint showed the presence of hip flexion, minimal range of movement with extreme pain experienced on rotation, especially on stretching of the external rotators.

*Side-room investigations.* Moderate anaemia (Hb. 9.6 G/100 ml.); ESR 27 and 30 mm./1st hour (Westergren) — 2 readings; WBC count 10,400 and 11,200/cu.mm. — 2 readings; differential count 88% neutrophils, 7% lymphocytes, 3% eosinophils and 2% monocytes. On blood smear examination, polymorph toxic granulations were noted with 10% of these being staff cells. The platelet count was 81,000 and 11,500/cu.mm. on 2 occasions.

*X-ray left hip joint.* 'No abnormality noted'; X-ray chest: 'Cardiac contour normal. Compression atelectasis right lower lobe'; X-ray abdomen (Fig. 1): 'Free air under the right diaphragm and some free fluid in the abdomen. The stomach is dilated but the rest of the bowel pattern, except for some dilatation of the colon, appears within normal limits.'

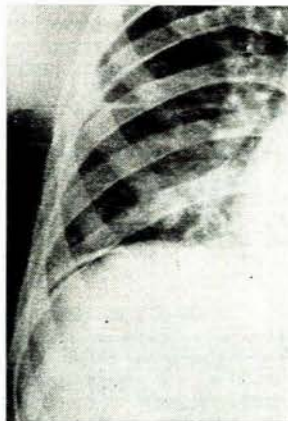


Fig. 1. X-ray photo of abdomen and chest (case 1) shows: right basal pulmonary compression atelectasis; free air under the right diaphragm; oedematous thickening of diaphragm; and intraperitoneal free fluid.

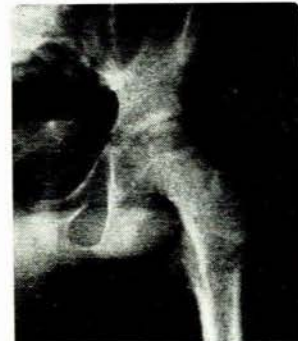

Fig. 2. X-ray photo of pelvis and left hip joint (case 1). Note marked ischial erosion and cortical destruction with breakthrough at the iliopectineal line and erosion also of the lateral border of the ileum. The left hip joint space is markedly narrowed with subluxation and destruction of the acetabulum. Note also the intrapelvic soft tissue swelling adjacent to the iliopectineal line.

**Other examinations.** No gross abnormality was detectable on chemical analysis of the blood, apart from a slightly raised BUN (116 mg./100 ml.). Urine microscopy and culture gave negative results. Microscopic examination of peritoneal effusion, obtained on diagnostic paracentesis, showed the presence of a moderate number of pus cells but no growth was obtained on culture. Stool examination was negative both for salmonellae and for shigellae, also both Widal and Weil-Felix tests were negative. Blood culture yielded an early positive culture of *Staph. aureus* sensitive to all antibiotics.

**Treatment.** In view of his extremely poor condition, initial treatment was conservative: by nasogastric suction and venoclysis combined with parenteral broad-spectrum antibiotics. On the next day, under local anaesthesia, aspiration of the left hip joint was performed and several ml. of thick, yellow pus obtained which, on culture, gave a heavy growth of *Staph. aureus* sensitive to all antibiotics. At this stage it was considered safe to subject the patient to general anaesthesia for exploration of the involved hip region.

At operation, suppurative arthritis of the hip joint was confirmed, and osteitis of the ischium and of the neck of the femur defined. Exploration of the ischial region showed the presence of pus tracking laterally via the obturator foramen along the outside of the ischium subperiosteally. Biopsy of the involved bone was performed and histological examination confirmed the presence of necrosis and evidence of long-standing osteitis. Suitable drains were placed and the patient was put onto Pugh's traction. About 12 hours after this operation, the patient suddenly collapsed with repeated massive haematemesis and the passage of melaena stools. Initial resuscitation by blood transfusions was adequate in maintaining his circulatory state. At this stage abdominal examination showed no distension or tenderness. After a further 4 hours, however, palpation of the abdomen showed gross distension and rigidity, and further gastro-intestinal haemorrhage occurred. It was then considered that the patient had re-perforated an acute ulcer in addition to the massive bleeding, thus rendering surgical intervention obligatory.

**Laparotomy.** At emergency laparotomy, free intraperitoneal blood was found together with filling of the entire gastro-intestinal tract with fluid and clotted blood. A large, free perforation was found involving the anterior wall of the first part of the duodenum with brisk haemorrhage from the edges of the perforation. A Polya-type subtotal gastrectomy was performed with closure of the duodenal stump and tube drainage to the blind end. Postoperatively the patient developed a duodenal fistula but this closed spontaneously within a week. Histologic examination of the resected specimen showed the presence of a peptic ulcer at the extreme end of the section. Further postoperative course was uneventful and he was placed in a plaster-of-paris spica about 1 month after admission. Repeat X-ray examination of the pelvis showed marked periosteal reaction, mainly in the ischium but also in the femur (Fig. 2). The essential clinical parameters monitored during his stay in hospital and convalescent home are recorded in Fig. 3.

An unusual feature in this case was the relatively low ESR-readings obtained on first admission, in spite of the extensive bone and joint involvement and generalized septicaemia, as evidenced by positive blood culture. In Shandling's series,<sup>24</sup> the majority of cases presented with ESR-readings well in excess of 30 mm./1st hour (Westergren). However, the initial reading, he points out, does not seem 'to be of any prognostic import'.

#### Case 2

N. de F., White male, 4 years. Ten days before admission the patient developed a boil on the right knee which was poulticed and discharged purulent material. In the morning, 3 days before admission, he complained of pain in his right thigh on movement and especially on walking. In the afternoon he cried, asked for water and, when his mother lifted him up, he vomited a large amount of fresh blood. This was followed by loss of consciousness and the passage of a melaena stool. He had been given a proprietary aspirin preparation orally 4-hourly for 4 days before admission and had also been feverish for 5 days before admission.

**Examination.** On admission to hospital, pyrexia (100.4°F), tachycardia (200/min.), tachypnoea (30/min.) and pallor of mucous membranes were noted. Examination showed marked cardiovascular activity with the presence of a systolic-flow murmur in all areas. The abdomen and respiratory systems were normal. Local examination showed the small scar on the right knee joint anteriorly, where the boil had been. The right hip was held in slight flexion and external rotation. The right thigh was swollen, warm and extremely tender, both on movement and on direct palpation. No external inguinal adenopathy was noted.

**Side-room examinations** showed the Hb. to be 6 G/100 ml.; WBC count 24,000 cu.mm. and the ESR 89 mm./1st hour (Westergren).

**X-ray examinations.** Chest—'heart and lungs have normal appearance'; femora—'there is soft-tissue swelling of the right thigh, compared to the left. No underlying joint or bone lesion can be seen'.

**Treatment.** Blood transfusion was commenced immediately on admission with satisfactory response and without further evidence of gastro-intestinal bleeding. Parenteral antibiotics was commenced and on the subsequent day the right femur was explored, acute bone inflammation confirmed in the lower third and the bone drilled to evacuate pus. Pus culture showed a growth of *Staph. aureus* sensitive to all broad-spectrum antibiotics tested. His further course was satisfactory with gradual decline in ESR and WBC (Fig. 3), confirmed by

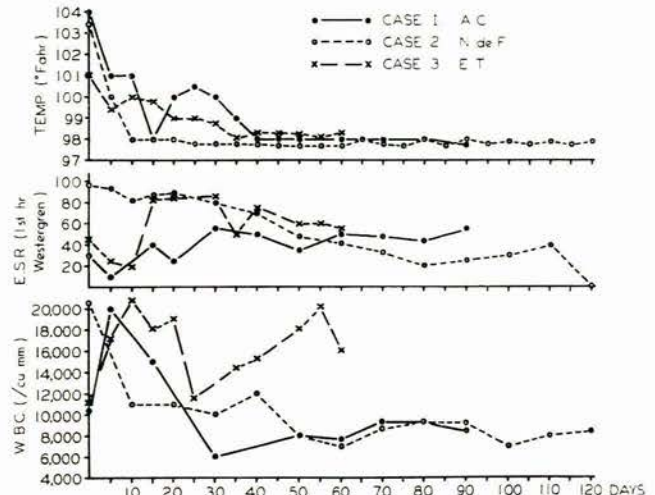


Fig. 3. Graphic depiction of the temperature, ESR and WBC readings of the patients as recorded during hospitalization.

satisfactory resolution on X-ray examination (Fig. 4). He was discharged in a spica after 121 days in hospital and, when last seen in outpatient department, a satisfactory result was recorded.

#### Case 3

E.T., Bantu male, 4½ years. This child was admitted with a history of pain in the left thigh for a few days, with inability to use the leg and an associated pyrexia.

**Clinical examination** on admission showed dehydration and signs of bilateral bronchopneumonia. Local examination showed swelling and tenderness involving the left thigh maximal over the upper end of the femur. Side-room investigations showed a Hb.-level of 12.0 G/100 ml.; WBC count 11,000/cu.mm. and ESR 45 mm./1st hour (Westergren).

**Treatment.** Initial conservative resuscitative measures were instituted and parenteral antibiotics commenced. On the following day surgical exploration of the left femur was performed and extensive drilling and drainage of the bone effected. Pus obtained yielded a heavy growth of *Staph. aureus* sensitive to all antibiotics.

On the 3rd postoperative-day, the patient suddenly collapsed and was found unconscious and pulseless. Blood transfusion

was commenced and a nasogastric tube passed, copious blood being aspirated. Shortly afterwards the patient passed several large melaena stools. Blood replacement was required and more than his calculated blood volume was transfused before clinical parameters returned to normal values. On 3 subsequent occasions over the next 2 weeks, unexplained episodes of acute intestinal obstruction occurred, responding rapidly to conservative therapy.

Further course was uneventful and he was discharged to a convalescent home in a plaster-of-paris spica after a 2-month stay in hospital. ESR and WBC count determinations showed that at this stage the osteitic process was still in a progressive phase (Fig. 3). On recent re-attendance at the outpatient department, he was recorded as a satisfactory result. Serial radiographs of the involved limb are shown in Fig. 5.

#### Considerations

In the last 2 cases it may be argued that the acute ulceration causing gastro-intestinal bleeding was possibly related to other factors. In case 3 the bleeding episode followed the event of surgical trauma, which might well have been the final precipitant cause. In case 2 there was a history of oral aspirin medication before admission, and this drug — a well-known aetiological factor in acute ulceration — might also be implicated in the pathogenesis of the

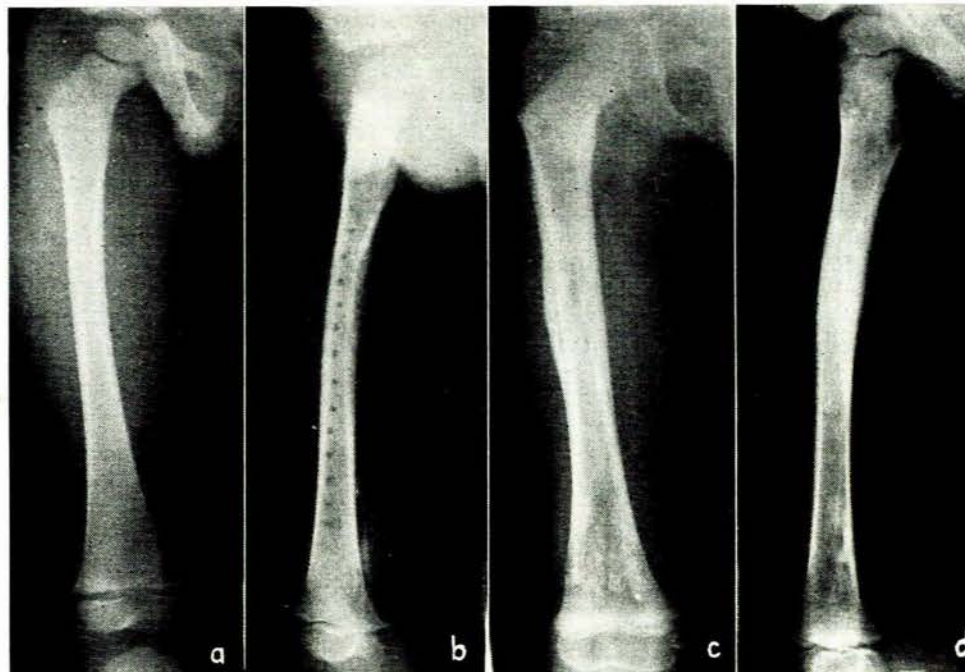


Fig. 4. X-ray photo of right femur (case 2). (a) On admission. Note soft tissue swelling and oedema of right thigh. (b) 2 weeks later. Cortical erosion and destruction seen involving the entire shaft with periosteal reaction of similar extent. Drill holes are clearly visible. Also note extensive soft-tissue swelling persisting. (c) 5 months after admission. No bone erosion detectable with further consolidation of periosteal reaction. (d) 9 months after admission. Progressive healing noted with adequate new-bone formation.

gastro-intestinal lesion. In case 1, however, historical review shows that perforation of an acute peptic ulcer presumably occurred 30-36 hours after onset of the bone and joint disease, unrelated to medication or operative treatment. Again, the haemorrhage and re-perforation followed surgical intervention, which probably constituted the immediate precipitant factor. In this case also, the pleuropulmonary manifestations and hepatomegaly could be explained on the basis of septicaemia. The dermatologic features on the other hand were two-fold in nature: initially a giant urticaria and later an erythema. The latter can be accounted for again as a toxi-allergic eruption, on a basis of septicaemia, but the former is not as easily explained. The urticaria was either an unrelated allergic phenomenon related to the ingestion of crayfish, or may have been related solely to the septicaemia. Indeed, a generalized urticarial rash occurring in cases of acute osteitis has been recorded.

The time interval between onset of infection and advent of acute perforation in this case may seem unduly short, but Dalgaard,<sup>5</sup> in reviewing cases of acute cerebral lesion associated with acute peptic ulceration, states that this usually amounts to 1-4 days with a minimum of only 6 hours in 2 cases of gastromalacia, thus confirming experimental evidence that acute ulceration may occur with extreme rapidity.

Weigel *et al.*,<sup>27</sup> on the other hand, in reviewing 24 cases of Curling's ulcer, pointed out that haemorrhage usually occurs on the 8th-10th day and perforation on the 30th day. In considering the possible pathogenesis of acute ulceration in acute osteitis, therefore, it seems that these

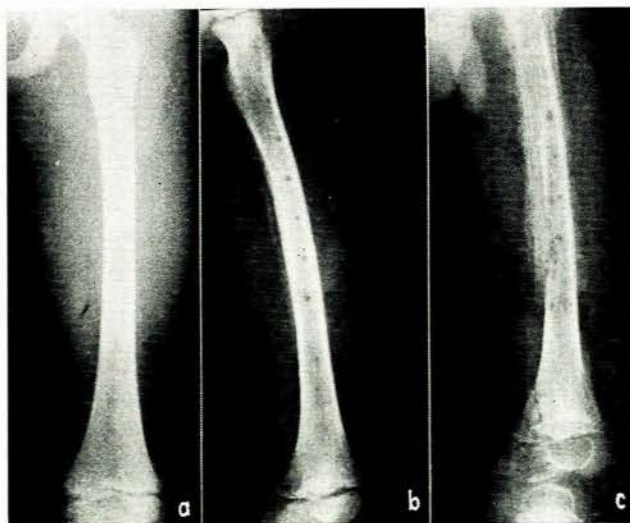


Fig. 5. X-ray photo of left femur (case 3). (a) On admission. No bone pathology detectable but subperiosteal mass with extensive soft tissue swelling and oedema noted. (b) 2 weeks later. Note drill holes. Marked cortical bone destruction with periosteal new bone formation. (c) 2 months after admission. Marked osteoporosis with fracture and destruction of femoral metaphysis. Complete sequestration of femoral cortex. Note also periosteal reaction of ischial ramus.

cases should be grouped with the former and hypothalamic-parasympathetic activity be invoked, rather than abnormal gastro-intestinal mucosal changes, as the initiating factor in acute ulceration (see below).

#### DISCUSSION

Acute ulcer denotes a 'superficial relatively non-inflammatory mucosal and submucosal erosion of short duration, accompanied by minimal symptoms but fraught with potential haemorrhage, perforation and chronicity'.<sup>20</sup> The most common and classically known types of acute peptic ulceration are those occurring in association with burns—'Curling's ulcer'<sup>2</sup>—and with hypothalamic lesions—'Cushing's ulcer'.<sup>3</sup> It must also be recorded that acute ulcers were described occurring in burn cases before Curling's report in 1842.

#### *Aetiology and Pathogenesis*

It is now recognized that all acute ulcerations occurring in a wide variety of circumstances are in some way related to stress. Unfortunately, the evidence concerned with the mechanisms which mediate the pathologic change is indefinite and inconclusive, despite long-continued intensive investigations. Review of the literature shows that apparently the gastric (antral) and the intestinal phases of gastric secretion are not important; instead, the vagal and pituitary-adrenal phases of gastric secretion are the main foci of attention.

Exhaustive reviews on the aetiology of acute peptic ulcer have been published by Harkins,<sup>14</sup> Friesen,<sup>11</sup> Mears<sup>21</sup> and Fletcher and Harkins.<sup>10</sup> Kanar<sup>16</sup> has brought current theories and thought on the aetiology of acute peptic ulcer up to date in a recent excellent chapter on the subject.

Several theories have been expounded and much experimentation conducted to expiate a neurogenic (hypothalamic-parasympathetic) origin of acute ulceration. In his original paper, Cushing<sup>3</sup> drew attention to hypothalamic involvement in acute peptic ulceration. Since then, however, it has been shown that a hypothalamic lesion is not essential to the formation of upper gastro-intestinal lesions<sup>12</sup> and no definite cerebral area is implicated in the production of acute ulceration.<sup>15</sup> Recent studies by Zukoski *et al.*<sup>29</sup> also substantiate the belief that anterior and posterior hypothalamic stimulation have no effect upon gastric secretion. Thus, Kanar<sup>16</sup> states that 'gastro-intestinal ulceration and haemorrhage represent an extreme pathophysiologic response to physical stress of (neuro-) surgery whatever its location'.

Gray<sup>13</sup> relates stress ulceration to anterior hypothalamic stimulation, causing discharge into the vagal nuclear centres, thus evoking vagal stimulation of the stomach with immediate hypersecretion of hydrochloric acid and pepsin. Dragstedt *et al.*<sup>5</sup> also found that stress does not increase secretion in the vagus-denervated stomach.

At present the most fashionable theory in the aetiology of acute peptic ulceration is that of pituitary-adrenal hyperactivity. Shay<sup>25</sup> has postulated an action sequence in ulcer formation whereby the stress-stimulated posterior hypothalamus, via the posterior pituitary gland, acts on the adrenal medulla to release epinephrine. This hormone, via the anterior pituitary, activates the production of cor-

ticotropin which again stimulates the adrenal cortex into releasing cortisone. These excessive levels of adrenal steroids may act on the stomach in 2 ways.<sup>13</sup> Firstly, the stomach becomes sensitized to noxious influences, and, secondly, adrenal hyperactivity may permit increase of gastric secretion to ulcer-producing levels.

Contrary evidence was obtained by Dragstedt *et al.*,<sup>6</sup> who did not find increased hydrochloric acid production from Haidenhain pouches in dogs given ACTH, cortisone and epinephrine. Also, increased secretion in Haidenhain pouch was not produced by extensive experimental burns and these authors conclude that 'if ulcerations are due to adreno-corticoid hormones released by injury, the effect is brought about by some mechanism other than simple hypersecretion of gastric juice'. Drye and Schoen<sup>8</sup> also believe that the post-traumatic peptic ulcer 'may be due, not to hypersecretion, but to unbuffered normal or elevated concentration of gastric juices acting on the gastric or duodenal mucosa'.

The latter observation fits in with the last group of theories, which postulate abnormal local gastro-intestinal pathologic changes as being the aetiological factors in acute ulceration. This is not a new concept as, in 1842, Curling<sup>2</sup> believed that Brunner's glands sympathized and compensated for the suppression of skin exhalation by an increased activity—this in turn leading to irritation, resulting in inflammation and ulceration. Kapsinow<sup>17</sup> was the first to relate acute peptic ulceration following burns to focal hypoxia of the mucous membrane, brought about by rupture of mucosal capillaries secondary to stasis of blood. However, it remained for Friesen,<sup>11</sup> in a series of excellent experimental studies, to identify the role of post-burn haemoconcentration with its resultant mucosal congestion in the aetiology of such acute ulcers. He states: 'This loss of plasma from the vascular space (by transudation of plasma-like fluid through capillaries at the time of burn and subsequent to it) results in increased concentration of the blood which, with its resultant stasis and increased viscosity, produces mucosal congestion (due to general capillary engorgement), extravasation and, occasionally, superficial necrosis. The mucosa, lacking an adequate supply of oxygen, is increasingly susceptible to the erosive action of gastric acid-peptic secretions which are not necessarily increased in degree.'

Confirmatory experimental evidence was obtained by Dahl *et al.*,<sup>4</sup> who showed that simple haemoconcentration by overtransfusion in rats results in acute ulceration in almost 90% of the animals. These authors suggest that haemoconcentration leads to relative circulatory stasis, causing decreased tissue resistance. Lillehei *et al.*<sup>19</sup> also suggest, in experimental observations of acute ulceration in a vagotomized dog subjected to severe emotional stress, that 'fluctuations in the resistance of the mucosa might be a more important determinant for ulcer occurrence than are fluctuations in gastric pouch acidity; although some acid must, of course, be present if peptic ulcers are to form'.

Wangensteen<sup>26</sup> reported 4 cases of fracture in which haematemesis and melaena occurred as a complication, with clinical and radiographic confirmation in 2 and post-mortem proof in 2. Experimentally, it has been demon-

strated that gastric and duodenal erosion and ulcer can be produced by fracture and that such lesions are associated with fat emboli in the smaller gastroduodenal vessels.<sup>1, 22</sup> Thus, fat emboli released into the bloodstream following fracture may occlude the end vessels in the gastric and duodenal mucosa, causing areas of local ischaemia which are less resistant to the acid-peptic secretions.

The relationship of mucosal and submucosal vascular channels to gastric secretion and the integrity of the gastric mucous membrane are considered by Palmer and Sherman<sup>23</sup> in the hypoxic theory of gastroduodenal ulcer genesis. These authors state that local arteriovenous shunts produce an area of mucosal hypoxia with decreased resistance to the autodigestive action of gastric juice. Also, that vagal stimulation increases mucosal engorgement by controlling these submucosal arteriovenous shunts. This engorgement is associated with gastric hypersecretion and decreased mucosal regeneration. Furthermore, these arteriovenous shunts are apparently under humoral and nervous control. Experimentally, Womack and Peters<sup>28</sup> confirmed the presence of such submucosal arteriovenous shunts and demonstrated that increased hydrochloric acid secretion is associated with increased flow through the mucosal capillary bed, while decreased gastric secretion is observed when flow from the submucosal capillary bed is diminished by the opening of submucosal arteriovenous shunts.

Despite the apparent plausibility of all these theories and the supportive investigations concerning the decreased resistance of the gastroduodenal mucosa, Dragstedt<sup>7</sup> states: 'the idea that peptic ulcers are due to a local decrease in the resistance of the mucosa to the digestive action of the gastric content has failed to receive either clinical or experimental support'.

From the foregoing, therefore, it is evident that a unitarian view of the pathogenesis of acute peptic ulcer is not applicable in the light of presently available information. These factors should be regarded as the basis for acute ulceration, but it is essential to consider the individual patient's capacity and sensitivity of response to a given type and magnitude of acute environment change, either internal or external.

#### Incidence

Curling's ulcer occurring in association with burns has variously been reported at 3.8%<sup>21</sup> and 2-5%.<sup>15</sup> Acute peptic ulceration incidence in cases of intracranial tumours was reported at 4.8% by Dalgaard,<sup>5</sup> who also, in a review of 5,000 autopsies, reported an 18.3% incidence of acute ulceration in patients with intracranial infection, noting that children are more prone than adults to develop acute ulceration with intracranial infections. Acute peptic ulceration was detected in 8 cases in a series of 375 autopsies performed on persons who died with fractures of the long bones, constituting an incidence of 2.16%.<sup>21</sup> In a review of 33 cases of acute osteitis admitted to Groote Schuur Hospital,<sup>9</sup> no instances of acute peptic ulceration were recorded. Similarly, the last review<sup>24</sup> of 300 cases of acute haematogenous osteomyelitis from the University of Cape Town Teaching Hospitals recorded no instances

of acute peptic ulceration occurring in conjunction with acute osteitis. A further statistical review shows that, from 1952 until September 1964, a total number of 670 cases of acute haematogenous osteomyelitis had been admitted to these hospitals and the presently recorded 3 cases are the only instances of acute ulceration occurring concomitantly.

#### Treatment

Since there is no fixed guide to therapy, each case must be treated on its own merits. Conservative resuscitative measures should obviously be favoured initially and must be persisted in for as long as is practically possible. If successful, further medical regimen for treating the ulcer is continued. Should the clinical condition escape control, however, then surgical measures must be adopted without delay.

#### SUMMARY

Three cases of acute haematogenous osteomyelitis are described in which associated acute peptic ulceration occurred. In 2 of these cases other factors may be considered in the aetiology of the acute ulceration. In the third case, however, perforation had occurred before either medication or surgery, and the peptic ulceration must therefore be considered a direct complication of acute haematogenous osteomyelitis.

Statistical review shows that this association of acute peptic ulceration with acute haematogenous osteomyelitis occurred in 3 out of 670 admissions.

Current theories on the causation of such acute stress ulcers are reviewed.

I am indebted to Prof. J. H. Louw for encouragement and criticism. Thanks are due to the Medical Superintendents of Groote Schuur Hospital and Red Cross War Memorial Children's Hospital for permission to publish details of these cases. I would also like to thank Dr. W. G. Schulze, in whose surgical firm case 1 was treated; Dr. K. G. Kling, who managed the orthopaedic aspects of this case; and Mr. G. McManus of the Department of Surgery, for the photography.

#### REFERENCES

1. Baronofsky, I. and Wangenstein, O. H. (1945): *Bull. Amer. Coll. Surg.*, **30**, 59.
2. Curling, T. B. (1842): *Medico-Chir. Trans.* (London), **25**, 260.
3. Cushing, H. (1932): *Surg. Gynec. Obstet.*, **55**, 1.
4. Dahl, J. R., Blaisdell, R. K. and Bentler, E. (1959): *Proc. Soc. Exp. Biol. (N.Y.)*, **101**, 622.
5. Dalgaard, J. B. (1958): *Acta path. microbiol. scand.*, **42**, 313.
6. Dragstedt, L. R., Ragins, H., Dragstedt, L. R. jr. and Evans, S. O. jr. (1956): *Ann. Surg.*, **144**, 450.
7. Dragstedt, L. R. (1959): *J. Amer. Med. Assoc.*, **169**, 203.
8. Dnye, J. C. and Schoen, A. M. (1958): *Ann. Surg.*, **147**, 738.
9. Du Plessis, D. J. (1953): *S. Afr. Med. J.*, **27**, 584.
10. Fletcher, D. G. and Harkins, H. N. (1954): *Surgerv.*, **36**, 212.
11. Friesen, S. R. (1950): *Ibid.*, **28**, 123.
12. Globus, J. H. and Ralston, B. L. (1951): *J. Mt Sinai Hosp.*, **17**, 817.
13. Gray, S. J. (1951): *Med. Clin. N. Amer.*, **41**, 1471.
14. Harkins, H. N. (1938): *Surgerv.*, **3**, 608.
15. Hummel, R. P., Lanchantin, G. F. and Artz, C. P. (1957): *J. Amer. Med. Assoc.*, **164**, 141.
16. Kanar, E. A. in Harkins, H. N. and Nyhus, L. M., eds. (1962): *In Surgery of the Stomach and Duodenum*. Boston: Little Brown & Co.
17. Kapsinow, R. (1934): *Sth. Med. J.* (Bgham, Ala.), **27**, 500.
18. King, A. B. and Reagan, J. C. (1953): *Ann. Surg.*, **137**, 236.
19. Lillehei, C. W., Roth, F. E. and Wangenstein, O. H. (1951): *Surg. Forum*, **2**, 43.
20. McHardy, G., McHardy, R. J. and Browne, D. (1959): *Postgrad. Med. J.*, **25**, 668.
21. Mears, F. B. (1953): *Surgerv.*, **34**, 640.
22. Merendino, K. A., Litow, S. S., Armstrong, W. D. and Wangenstein, O. H. (1945): *Bull. Amer. Coll. Surg.*, **30**, 58.
23. Palmer, E. D. and Sherman, J. L. jr. (1958): *Arch. Intern. Med.*, **101**, 1106.
24. Shandling, B. (1960): *S. Afr. Med. J.*, **34**, 520.
25. Shay, H. (1954): *Gastroenterology*, **26**, 316.
26. Wangenstein, O. H. (1945): *Canad. Med. Assoc. J.*, **53**, 309.
27. Weigel, A. E., Artz, C. P., Reiss, E., Davis, J. H. and Amspacher, W. H. (1953): *Surgery*, **34**, 826.
28. Womack, N. A. and Peters, R. M. (1958): *Ann. Surg.*, **148**, 537.
29. Zukoski, C. F., Lee, H. M. and Hume, D. M. (1961): *Surg. Forum*, **12**, 282.