

A CASE OF CERVICAL PREGNANCY

A. M. DHOODHAT, M.B., CH.B., *Department of Obstetrics and Gynaecology, Somerset Hospital*

A cervical pregnancy is an extremely rare form of ectopic pregnancy in which the fertilized ovum becomes implanted in the cervical canal, distending it as it grows.^{1,2} It is a dangerous form of pregnancy, fraught with serious complications, and often requiring urgent treatment. The subject has been well reviewed by Resnick.³ The following is a case report of such a pregnancy which was only diagnosed at laparotomy.

CASE REPORT

History

An African woman, aged 30, was admitted to the New Somerset Hospital on 12 September 1964 because of intermittent vaginal bleeding for the preceding 3 weeks. She also had lower abdominal pains for the same period. Her menstrual pattern was irregular but she gave no history of having missed a period.

She had 1 live child, delivered by lower-segment caesarean section, the reason for the section being unknown. She had not had any abortions.

General Examination

The patient was extremely anaemic with a haemoglobin of 6 G/100 ml. She had a tachycardia and a blood pressure of 110/70 mm.Hg.

Abdominal examination elicited tenderness in the left side of the lower abdomen.

Vaginal Examination

There was slight bleeding. The cervix was soft, enlarged and drawn upwards, lying almost flush with the vaginal vault. The external os was just open. The uterus was enlarged to the size of an 8-week pregnancy with a firm, round swelling, thought to be a fibroid, on the right side of the fundus.

A diagnosis of inevitable abortion was made. She was transfused with 3 pints of blood and it was decided to evacuate the retained products of conception as soon as her condition permitted.

The next day (13 September) she had a sudden, profuse, painless vaginal haemorrhage, losing about 1½ pints of blood. She was given a further blood transfusion and sedated. An intravenous drip of oxytocin was set up, which controlled the bleeding.

On the following day at 8 a.m. the patient was taken to theatre and examined under anaesthesia. The uterus was found to be enlarged and was thought to contain a fibromyoma situated at the fundus. Products of conception were found inside the uterus. A soft boggy mass was palpable in the left fornix.

The cervix was grasped with great difficulty because it was drawn upwards. As the retained products were being digitally separated, profuse bleeding started. Intravenous ergometrine (0.5 mg.) was given to control the bleeding.

At this stage, the vaginal bleeding was very profuse and bimanual compression was applied to control it, while attempts were made to set up an intravenous infusion. Her blood pressure was now unrecordable and the veins were collapsed. After considerable difficulty an intravenous infusion was achieved after a cut-down procedure. Two pints of un-crossmatched blood were pumped in, raising her blood pressure to 100/60 mm.Hg. This rise in blood pressure re-started the bleeding, which had ceased while the blood pressure had fallen.

A decision was taken to perform an emergency laparotomy to exclude the possibility of a perforation of the uterus.

Laparotomy

At operation a small amount of blood was found in the pelvic cavity. The body of the uterus was intact, but the cervix was ballooned out, thin and soft. A haematoma was present in the left broad ligament alongside the cervix. The body of the uterus was opened and found to be normal. Through the endometrial cavity a finger was inserted into the cervix and the products of gestation were then felt. A diagnosis of cervical pregnancy was made and because of the profuse vaginal bleeding, a total hysterectomy was performed. Nevertheless persistent oozing continued from the area around the haematoma in the broad ligament and in spite of several haemostatic stitches, complete haemostasis was not obtained. This area was packed with haemostatic foam and the abdomen was closed.

In the ward her blood pressure remained at about 110/70 mm.Hg and her general condition was fair. That same evening at about 10 p.m. her systolic blood pressure fell to 80 mm.Hg but this was raised by a further blood transfusion of 2 pints of blood. There was no vaginal bleeding. A similar drop in blood pressure recurred at 4 a.m.; by then there was an associated increase in her abdominal girth with evidence of free fluid in the abdomen. It was decided to re-open the abdomen to procure satisfactory haemostasis.

The abdomen was re-opened and found to contain about 2 pints of blood and clots. No active bleeding was found but there was a persistent oozing from the left supra-vaginal angle and the area around the haematoma in the broad ligament.

The left ureter was found to be dilated and caught in 2 haemostatic stitches which had been previously inserted near the haematoma. The ureter, which was freed by cutting the stitches, was found to be intact. As the oozing could not be controlled, the left internal iliac artery was dissected free and tied off just below the bifurcation of the common iliac artery. This controlled the bleeding satisfactorily. The abdomen was then closed, leaving a corrugated rubber drain to drain the area around the left ureter and haematoma. Following this the patient made an uneventful recovery.

She received a total of 19 pints of blood of which 14 pints were un-crossmatched and group O positive in type.

Two weeks after her operation an intravenous pyelogram was performed and both ureters were found to be functioning normally. She was discharged on the 18th day.

Pathological Examination

The specimen consisted of a uterus and cervix without adnexa (Fig. 1). The cervical os had been pushed to one side and the cervix itself was considerably enlarged. A perforation was present in the left anterior wall. On section it was dilated and the inner surface was markedly ragged. The wall of the cervix contained numerous small haemorrhagic foci scattered throughout. The body of the uterus was apparently normal.

Histological examination showed normal placental tissue infiltrating the cervix, which contained large, unduly prominent

vessels, some of which possessed eccentric intimal thickenings. An area of calcification was present in the myometrium.

DISCUSSION

The above case adequately illustrates most of the clinical features and complications of a cervical pregnancy.

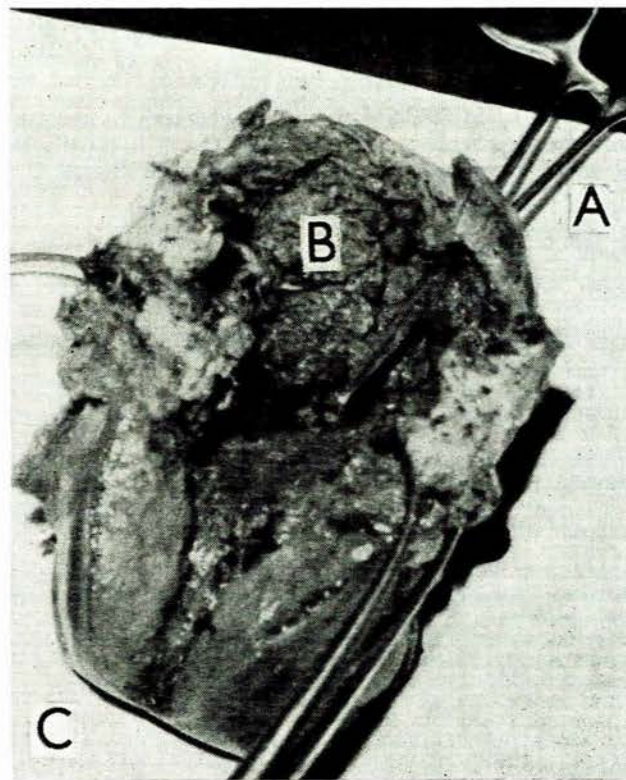


Fig. 1. A = Artery forceps inserted through external os into ballooned-out cervix. B = Cervix containing ragged products of gestation. C = Body of uterus.

Characteristic Symptoms

Amenorrhoea. Although in this patient there was no definite history of amenorrhoea, the majority of cases described in the literature had missed 1 or 2 periods, but very few go beyond the 12th week without giving rise to symptoms. Pisarkie¹ describes an unusual case of cervical pregnancy which advanced to 33 weeks and which was discovered at laparotomy. A live child was extracted, after which a total hysterectomy was performed.

Bleeding. In the majority of cases, intermittent vaginal bleeding is the presenting symptom. A few cases have presented with a massive haemorrhage. Usually the bleeding becomes worse while an attempt to evacuate the products of gestation is made.

Pain. Although in this case pain was a feature, this was absent in the majority of cases described.

Diagnosis and Complications

As already stated, severe bleeding usually occurs during the removal of the retained products. This can be so severe that a massive blood transfusion may be required and a laparotomy necessitated. Only then can the diagnosis of cervical pregnancy be established.

Occasionally a perforation may be found in the pregnant cervix. This can lead to profuse intraperitoneal bleeding. If a hysterectomy is performed, then considerable care must be taken to avoid the ureters which lie close to the ballooned-out cervix.

If oozing around the paracervical region persists, rather than insert stitches blindly, adequate haemostasis can usually be obtained by ligating the internal iliac artery on the side involved.

Prognosis

According to Studdiford⁵ and Mayberger⁶ the mortality in cervical pregnancy is about 20%. Death is usually due to shock from persistent uncontrolled haemorrhage.

SUMMARY

A case of cervical pregnancy is described in which, as a result of profuse vaginal bleeding, massive blood transfusion was given and a hysterectomy performed. While performing the hysterectomy, the left ureter was inadvertently caught in 2 stitches inserted in an attempt to control persistent oozing from the area alongside the cervix through which the cervical pregnancy had perforated.

The abdomen was re-opened because of further intra-abdominal bleeding, and the left internal iliac artery was tied off to effect haemostasis and the left ureter was freed.

The patient recovered without any resultant ureteric damage.

Some of the clinical features and complications of this rare and serious type of ectopic pregnancy are described.

I wish to thank Dr. R. Nurok, Medical Superintendent of Somerset Hospital, for permission to publish; Dr. H. Edelstein, who performed the second operation, for helpful advice and criticism in the drafting of this paper; Dr. L. Resnick for his advice and encouragement, and the surgical registrars and the theatre nursing staff, who helped me at a crucial moment.

ADDENDUM

Since the completion of the above paper, we have had another case of cervical pregnancy at the New Somerset Hospital.

Case Report

An African woman, aged 35 years, was admitted on 18 February 1965 at 6 p.m., complaining of persistent vaginal bleeding for the preceding 7 days. Her menstrual periods were regular except for the present one, which was 7 days overdue.

On examination the patient was anaemic with a haemoglobin of 6 G/100 ml. and a blood pressure which was unrecordable. She was mildly jaundiced. After vaginal examination a diagnosis of incomplete abortion was made and arrangements were made to evacuate the retained products, as soon as her condition permitted. During that night she was transfused with 9 pints of blood, of which 3 were un-crossmatched, group O positive, because of persistent severe vaginal bleeding. The next morning she was oliguric, her urine output for the night being 90 ml. She was examined by the consultant and diagnosed as a case of cervical pregnancy. In theatre under cyclopropane anaesthesia, the diagnosis was confirmed and the cervix was tightly packed with gauze to control the haemorrhage. However, bleeding continued, possibly due to the erosion of a large artery. Subsequently a total hysterectomy was performed under spinal anaesthesia.

Postoperatively her systolic blood pressure remained at a low level of 60 mm.Hg. In spite of blood transfusions this could not be raised. She was now anuric and the jaundice was much deeper. She was put on massive doses of hydrocortisone and antibiotics to counter the persistent shocked state. Gradually she responded to this regime and by the morning of 21 February her blood pressure was 110/60 mm.Hg. She was then transferred to the artificial-kidney unit at Groote Schuur Hospital for dialysis.

REFERENCES

1. Jeffcoate, T. N. A. (1957): *Principles of Gynaecology*, 1st ed. London: Butterworth.
2. Greenhill, J. P. (1960): *Obstetrics*, 12th ed. Philadelphia: Saunders.
3. Resnick, L. (1962): *S. Afr. Med. J.*, **36**, 73.
4. Pisarkie, T. S. (1960): *J. Obstet. Gynaec. Brit. Emp.*, **67**, 759.
5. Studdiford, W. E. (1945): *Amer. J. Obstet. Gynec.*, **49**, 169.
6. Mayberger, H. W. (1958): *Obstet. and Gynec.*, **11**, 657.