

Case Report

A TRUE HERMAPHRODITE WITH XX/XY CHROMOSOME MOSAICISM

M. A. MANUEL, M.B., CH.B.; A. ALLIE, M.B., CH.B.; AND W. P. U. JACKSON, M.D., F.R.C.P., with the technical assistance of HAWA MAKDA, B.Sc., *New Somerset Hospital and the Department of Medicine, Groote Schuur Hospital and the University of Cape Town*

The occurrence of a true hermaphrodite with 2 different cell types—a presumptive mosaic of normal female XX chromosomes and normal male XY chromosomes—is reported here. There are very few similar published case reports.¹⁻⁴ The condition is thus sufficiently rare to warrant recording the details of a further patient.

CASE REPORT

A 20-year-old African 'male' (M.F., Fig. 1) presented with mild dysenteric symptoms. His general appearance was remarkably feminine with a round, hairless face with no temporal recession of the hairline, wide pelvis, female pubic escutcheon, large breasts, and small thyroid cartilage. He had a small hypospadiac penis with an underdeveloped scrotum and partial chordee (Fig. 2). Gonads were not felt in the scrotum or inguinal region; neither prostate nor uterus was palpable per rectum. There was no vaginal opening.

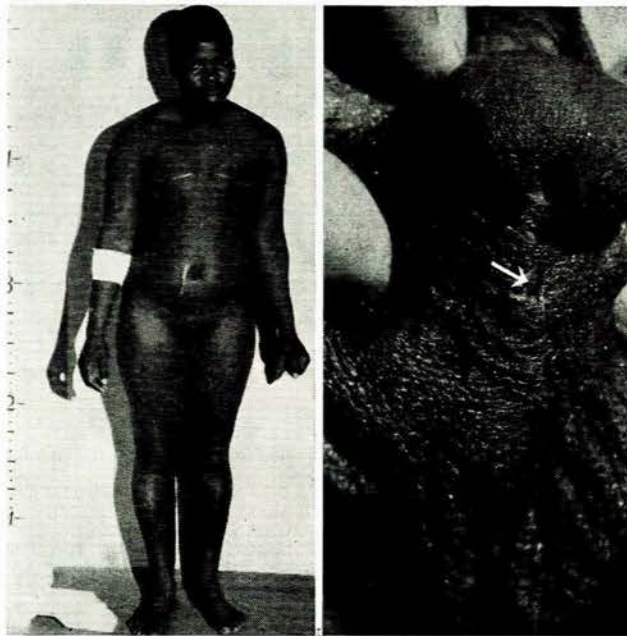


Fig. 1.

Fig. 2.

Fig. 1. Patient M.F. showing scars following bilateral mastectomy.
Fig. 2. External genitalia. Note underdeveloped penis, hypospadias, empty scrotum. Urethral opening is arrowed.

Special Investigations

X-rays of chest and skull—normal.
X-rays of pelvis—gynaecoid.
Cystogram—normal (in particular no communication with genital tract).
24-hour urinary FSH excretion—positive at 96 mouse uterine units (normal range in our laboratory: 6-48 m.u.).
24-hour urinary 17-oxosteroid excretion—18.6 mg.
24-hour urinary 17-hydroxycorticoid excretion—17.2 mg.
Buccal smear—single Barr bodies⁵ seen in 40% of cells (Fig. 3).

Peripheral blood smear—6% of polymorphonuclear neutrophils showed drumsticks (Fig. 4).

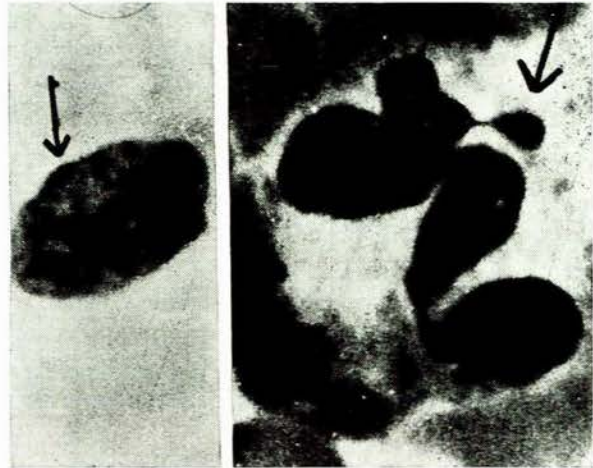


Fig. 3.

Fig. 4.

Fig. 3. Nucleus from buccal mucosal cell showing sex chromatin.
Fig. 4. Polymorphonuclear neutrophil from peripheral blood smear, with 'drumstick'.

Chromosome Culture

In peripheral blood, of 28 cells analysed, 20 showed a 46/XX (i.e. 44 autosomes plus XX sex chromosomes) (Fig. 5) pattern and 8 showed a 46/XY (Fig. 6) pattern.

In skin from the right forearm, 30 cells were examined. All showed a 46/XX pattern.

Tissue	No. of cells	XX complement	XY complement
Peripheral blood	28	20	8
Skin (right forearm)	30	30	—

Blood Groups

A, $\bar{c}\bar{c}Dee$ ($\bar{c}De/\bar{c}De$), MsNs, P+, KK, Fy^(a)+, Fy^(b)-, Lu^(a)-, Le^(a)-Le^(b)+, Jb^(a)+Jb^(b)+, Xg^(a)+, Js (a-).

Other Genetic Tests

Hp	Tf	Serum cholinesterase	Red cell enzymes
2:2	C	C _s U, I or A	Acid phosphatase G6PD
		U	B A

i.e. No evidence of mixture of any genetic markers.

Laparotomy revealed a small uterus, normal-looking fallopian tubes and bilateral gonads situated in the normal position for ovaries (Fig. 7). The gonads were removed.

The histology of each gonad showed an ovary in which was incorporated testicular tissue. The ovarian portion included mature Graafian follicles, atretic follicles and corpora albicantes (Figs. 8 and 9). It was noted that the patient had ovulated.

The testicular portion (Figs. 10 and 11) showed seminiferous tubules lined by Sertoli cells. There was no evidence of spermatogenesis. Clusters of interstitial cells of Leydig were present.

It was not possible to trace any relatives of this patient.

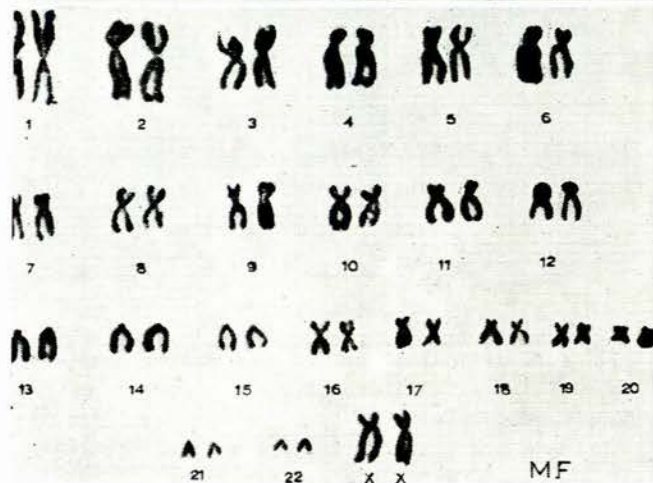
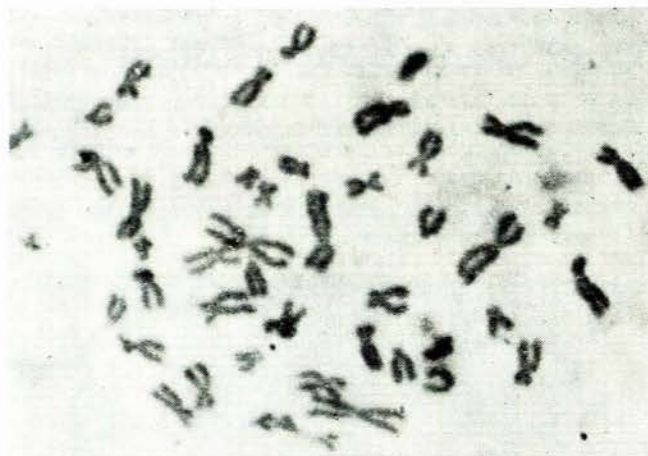


Fig. 5.

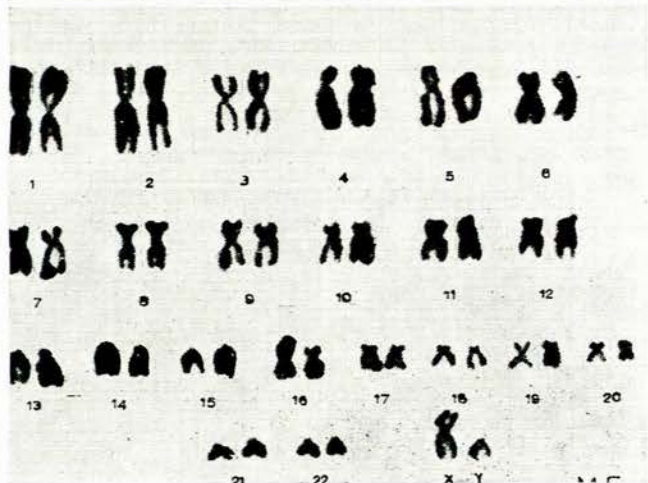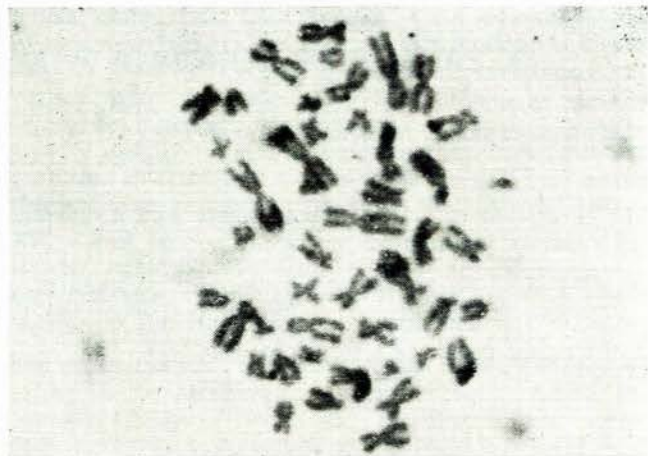


Fig. 6.

Fig. 5. Above: Chromosome analysis of patient M.F. showing XX complement. The karyotype is shown below. Fig. 6. Above: Chromosome analysis of patient M.F. showing XY complement. The karyotype is shown below.

Management

Because of language difficulties, the patient's psycho-sex could not be considered in detail. He wished to remain male. It is known that he had been reared as a male and works as a delivery boy. He has shown no homosexual tendencies. Both breasts were removed and a long-acting depôt testosterone is

being given by intramuscular injection in order to produce male secondary characteristics.

Methods

Buccal mucosal cells were obtained by scraping and were fixed in Papanicolaou's fixative. It was stained with a 0.5% solution of aqueous cresyl echt violet.⁶

Blood smears were stained with Leishman's stain for examination for the presence of drumsticks⁷ on the polymorphonuclear neutrophil leucocytes. Chromosome culture on peripheral blood was cultured by the technique of Moorhead *et al.*⁸ with slight modifications.⁹

The skin culture was done by Dr. M. J. W. Faed of the Western General Hospital, Edinburgh.

DISCUSSION

By virtue of the presence of both ovarian and testicular tissue this patient is a true hermaphrodite. Initially it was thought that true hermaphrodites might have both male and female chromosomal complements, i.e. XY and XX. This, however, has proved to be the case in very few reported patients, the remainder showing a variety of different sex chromosome patterns. The normal female karyotype, simple 46/XX, has been reported in the

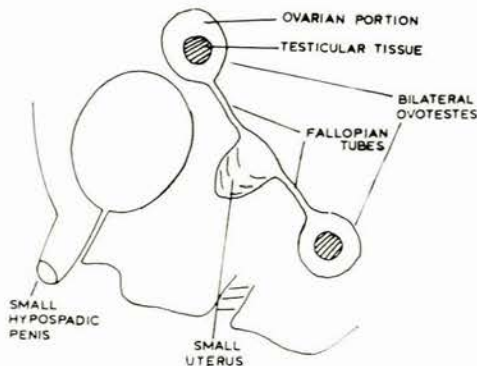


Fig. 7. Diagram of genito-urinary tract.

majority. References to 12 such reports are given by Blank *et al.*¹⁰

Sandberg, Koepf, Crosswhite and Hauschka¹¹ (1960) reported a case with the normal male 46XY complement.

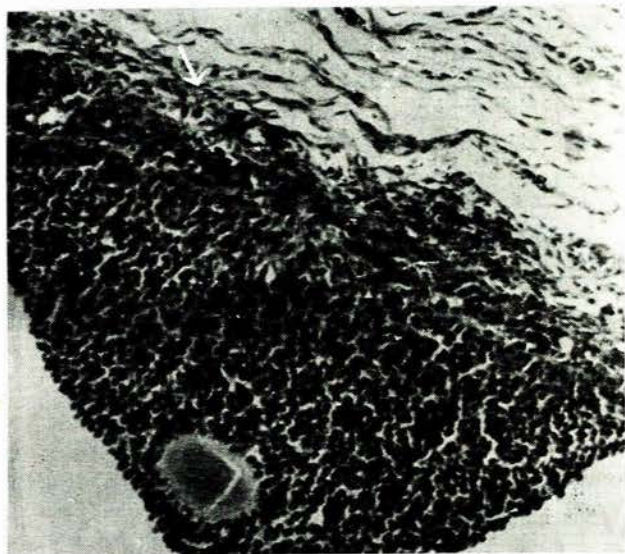


Fig. 8. Ovarian portion of gonad. Mature Graafian follicle containing ovum (or structure very closely resembling ovum) surrounded by granulosa cells. A band of non-luteinized theca interna is on the right (arrow).

Mosaicism in true hermaphrodites has been found by Ferguson-Smith *et al.*¹² (46XX/47XXX) and Blank *et al.*¹⁰ (46XX/48XXYY), while Fraccaro *et al.*¹³ observed 3 cell lines in their case (46XX/47XXY/49XXYYY). The mosaic syndrome with 46XO/46XY pattern cannot be considered to represent true hermaphroditism because of the absence of definite ovarian tissue in these cases.¹⁴ The mosaic XX/XY case reported by Gartler *et al.*¹ was that of a girl of 2 years who was brought to the doctor with an enlarged clitoris. The patient was found to be a lateral hermaphrodite with a 46XX/46XY chromosomal pattern. Our case has a similar chromosomal pattern.

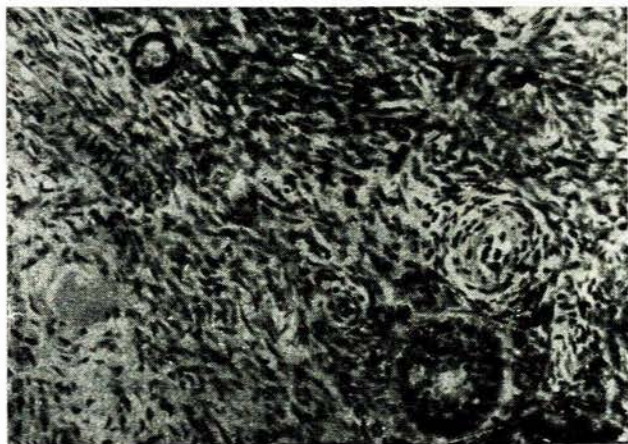


Fig. 9. Ovarian portion. Developing follicles and follicle cysts in ovarian stroma. (Corpora fibrosa were also present.)

De Grouchy and co-workers³ reported another XX/XY hermaphrodite, and a further case is mentioned by Brogger and Aagaes.⁴ Zuelzer *et al.*¹⁵ described an XX/XY mosaic with mixed blood groups, but this patient

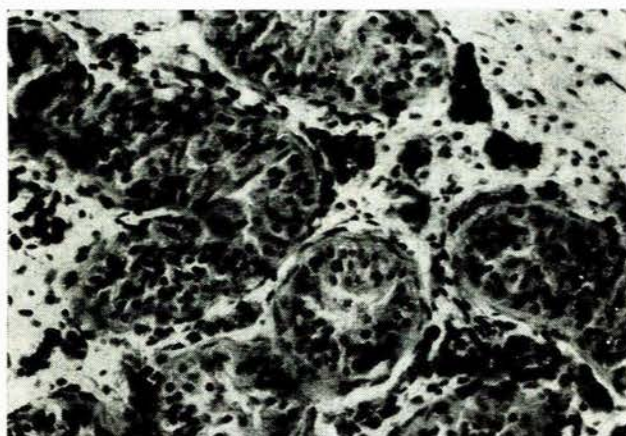


Fig. 10. Testicular portion. Low-power view. Clusters of seminiferous tubules with many clumps of mature-looking Leydig cells.

was not a hermaphrodite, and in fact had 2 normal testes with active spermatogenesis.

Genetic Explanation

At least 2 possible mechanisms could explain the existence of XX/XY mosaicism. Double fertilization, in which the foetus is derived from 2 eggs fertilized by genetically different sperm, is one possibility. This presumably is the explanation of the case of Gartler *et al.*¹ since their patient had 2 distinct red blood cell populations.

In our case it is unfortunate that evidence for mosaicism was obtained only from leucocyte culture; however, the 2 different karyotypes were completely convincing in this culture. The origin of the presumptive mosaicism is unlikely to have been double fertilization because of the

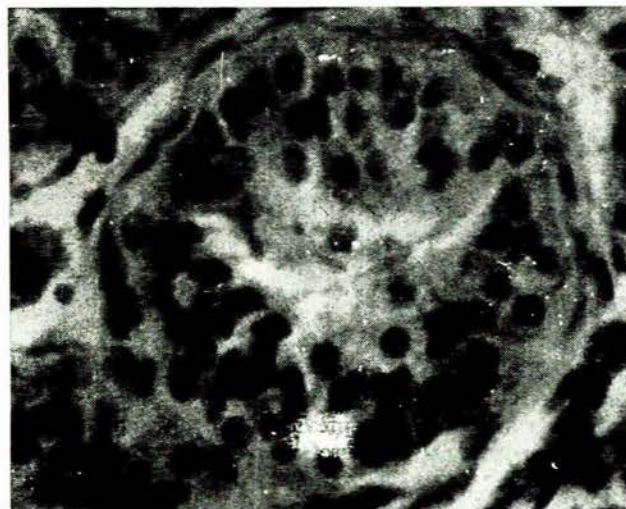


Fig. 11. Single tubule containing Sertoli cells only.

total lack of evidence of more than 1 red cell population. In the case of De Grouchy *et al.*³ there was a mixture in the haptoglobins, although not in any of the red cell antigens, but in our patient no evidence of mixing of any of the genetic markers could be found.

The simplest explanation apart from double fertilization must involve at least a double error during early cell division, in which the Y chromosome gets lost and the X chromosome must 'double up'. Assume that the patient was conceived as a normal male XY zygote. At an early division, perhaps the first one, an anaphase lag of the Y chromosome¹⁶ gave rise to a clone of XO cells. Next a mitotic non-dysjunction of X in the (first?) XO cell gave rise to XX cells.¹⁷ Thus one finds 2 stem lines of different constitution (Fig. 12).

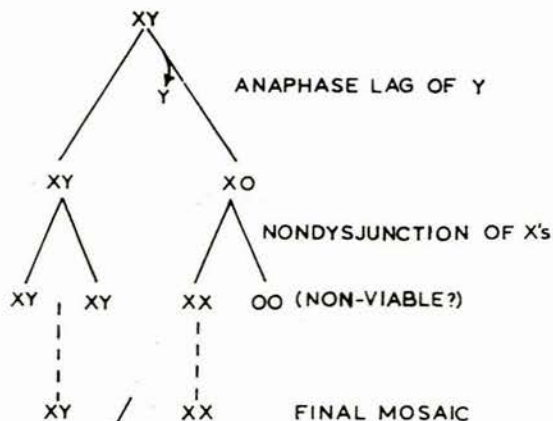


Fig. 12. Diagram showing possible origin of XX/XY mosaicism.

The absence of XY cells from the skin culture and their presence in the blood is probably due to the XY line simply dying out at some stage during the prolonged culture time needed for skin preparations. Unfortunately specimens of internal organs were not made available to us for culture.

If this account of the origin of XX/XY mosaicism is correct it would however be expected that the proportion

of XY cells would be at least equal to and probably greater than the XX cells. Either the XY cells divided less rapidly during growth or are more difficult to grow in tissue culture.⁴

SUMMARY

A true hermaphrodite with bilateral ovotestes is presented. His presumptive chromosomal constitution is a mosaic of 46 XX/46 XY cells. No evidence of double fertilization could be found.

We wish to thank the Superintendent of the Somerset Hospital for permission to publish this case; Dr. Mark Horwitz for his constant encouragement and guidance; Drs. R. Hoffenberg, M. Modlin, A. Rosenberg, Margaret Hoffman and Prof. C. J. Uys for their invaluable assistance; Dr. M. J. W. Faed, of the Western General Hospital, Edinburgh, for having done the skin culture; Dr. G. Selzer for histological examination; Dr. M. C. Botha and his staff and Dr. Ruth Sanger, of the Lister Institute, for the blood grouping; and Dr. B. Robson, of the Human Biochemical Genetic Research Unit (London), for the testing of Rhm genetic markers.

The laparotomy was performed in the Department of Surgery, Somerset Hospital, by Dr. L. Chanock.

This work was supported in part by grants from the Wellcome Trust and the S.A. Council for Scientific and Industrial Research to the Endocrine Research Group of the University of Cape Town.

REFERENCES

- Gartler, S. M., Waxman, S. H., Giblett, E. (1962): Proc. Nat. Acad. Sci. (Wash.), **48**, 332.
- Waxman, S. H., Gartler, S. M. and Burt, B. E. (1962): Proc. Soc. Exp. Biol. (N.Y.), **110**, 722.
- De Grouchy, J. *et al.* (1964): Ann. Génét., **7**, G 25.
- Brogger, A. and Aagaenaes, Ö. (1964): Lancet, **2**, 259.
- Moore, K. L. and Barr, M. L. (1950): *Ibid.*, **2**, 57.
- Ross, A. (1960): J. Med. Lab. Technol., **17**, 178.
- Davidson, W. M. and Flute, P. T. (1962): Acta cytol. (Philad.), **6**, 913.
- Moorhead, P. S., Nowell, P. C., Mellman, W. J., Batipps, D. M. and Hungerford, D. A. (1960): Exp. Cell Res., **20**, 613.
- Hirschorn, K. and Cooper, H. L. (1961): Amer. J. Med., **31**, 442.
- Blank, C. E., Zachary, R. B., Bishop, A. M., Emery, J. L., Dewhurst, C. J. and Bond, J. H. (1964): Brit. Med. J., **2**, 90.
- Sandberg, A. A., Koepf, G. F., Crosswhite, L. H. and Hauschka, T. S. (1960): Amer. J. Hum. Genet., **12**, 231.
- Ferguson-Smith, M. A., Johnston, A. W. and Weinberg, A. N. (1960): Lancet, **2**, 126.
- Fraccaro, M., Taylor, A. I., Bodian, M. and Newns, G. H. (1962): Cytogenetics (Basel), **1**, 104.
- Mellman, W. J., Kleivit, H. D., Yakovac, W. C., Moorhead, P. S. and Saksela, E. (1963): J. Clin. Endocr., **23**, 1090.
- Zuelzer, W. W., Beatie, K. M. and Reisman, L. E. (1964): Amer. J. Hum. Genet., **16**, 38.
- Ford, C. E. (1960): Amer. J. Hum. Genet., **12**, 104.
- Schuster, J. and Motulsky, A. G. (1962): Lancet, **1**, 1075.