

THE PRESENCE OF TRIPLE PATHOLOGY

T. FICHARDT, M.D., D.Sc., M.MED.(RAD.T.), D.M.R.E., F.F.R.(R.C.S.I.), AND A. G. SANDISON, M.B., CH.B., M.MED.(RAD.T.), *Department of Radiotherapy, Pretoria General Hospital and University of Pretoria*

We present this case because of the presence of triple pathology (See Figs. 1 - 4):

1. The congenital abnormality of pectus excavatum (or funnel chest) as opposed to pectus carinatum (or keeled chest).
2. The pathological gallbladder filled with opaque gallstones, and
3. The presence of carcinoma in the left breast.

The patient, Miss A.M.E., 49 years of age, was referred to us by Dr. C. A. R. Schulenburg for postoperative deep X-ray therapy for a clinical Stage II carcinoma of the left breast. He performed a radical mastectomy on her on 12 December 1962. The patient first noted a small lump in the lower and outer quadrant of her left breast in

June 1962. The lump gradually grew in size until it reached the size of a pigeon's egg. She consulted her doctor who referred her to Dr. Schulenburg. Dr. W. J. Pepler reported as follows on sections of the specimen prepared for histological examination: 'The tumour of the left breast shows the presence of an infiltrating duct carcinoma, and the medial and central group of axillary lymph nodes show metastatic involvement'.

On 21 January 1963 we commenced a course of deep X-ray therapy which was completed on 8 February 1963. The patient has been followed-up regularly and was last seen on 16 October 1964 in fairly good health except for flatulent dyspepsia. There was no evidence of metastases. The patient refuses any further surgical treatment.

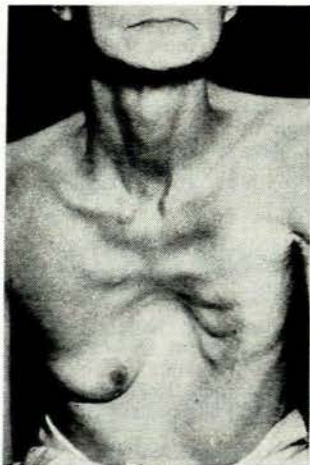


Fig. 1.

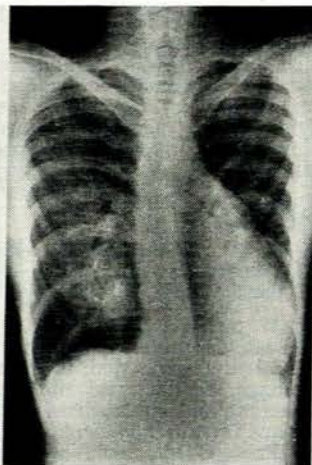


Fig. 2.

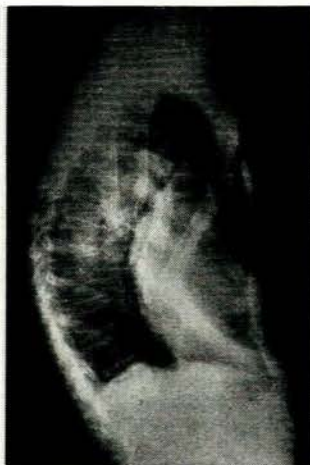

Fig. 3.

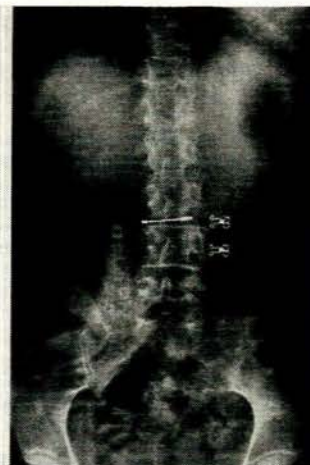


Fig. 4.

Figs. 1 - 4. See text.

11TH INTERNATIONAL CONGRESS OF RADIOLOGY, 1965

The 11th International Congress of Radiology will be held in Rome on 22 - 28 September 1965. Profs. S. F. Oosthuizen and J. Kaye, and Drs. M. Weinbren and M. Denny have been appointed the official delegates of the Radiological Society of South Africa

(M.A.S.A.). Application forms for enrolment can be obtained from Dr. O. P. Charlton, Hon. Secretary of the Society, 101 Medical Centre, Jeppe Street, Johannesburg. The closing date for enrolment is 30 NOVEMBER 1964.