

## A CASE OF FEMALE HERMAPHRODITISM WITH ASSOCIATED CONGENITAL DEFECTS: REVIEW OF SOME AETIOLOGIC PROBLEMS

G. M. B. BERGER, B.Sc., M.B., B.Ch., *Department of Pathology and Microbiology, University of the Witwatersrand,*  
and SARAH KLEMPMAN, M.B., B.Ch., *South African Institute for Medical Research, Johannesburg*

Female hermaphrodites may be classified into two main categories (Table I), viz. (A) those in whom the *aetiological factors are known*, i.e. excessive androgenic stimulation from a known source, and (B) those in whom the *causal factor or factors are unknown* (idiopathic variety).

TABLE I. FEMALE HERMAPHRODITISM

Group A: *known aetiology*—excessive androgens

(a) *Endogenous*

(i) *Foetal origin* (congenital adrenal hyperplasia)

(ii) *Maternal origin* (virilizing tumour)

(b) *Exogenous* (synthetic progesterones administered to mother during pregnancy)

Group B: *unknown aetiology*

Class I: abnormal sexual development only

Class II: abnormal sexual development + congenital anomalies

A recent attempt at classification is based essentially on the above concepts:<sup>1</sup>

*Group A.* The large majority of cases fall into this group. Most of them are the result of congenital adrenal hyperplasia, which has been the subject of a number of recent reviews concerning both the morphological and biochemical aspects.<sup>2-4</sup> The administration of androgens and synthetic progesterones to the mother during the critical phase of foetal development accounts for some cases.<sup>5</sup> Rarely, virilization of the female foetus results from an androgen-producing tumour in the mother. In this group there is little variation in the maldevelopment, and abnormal differentiation is generally localized to the external genitalia and urogenital sinus. The internal genitalia are normal. The phallus is enlarged. A corpus cavernosum and glans may be present. Usually the urethra opens at the base of the phallus. Less commonly it may enter into a urogenital sinus or, rarely, traverse the entire length of the phallus and open in the normal male position at the tip. The labioscrotal folds show variable degrees of fusion. In patients with excessive virilization the prostate and seminal vesicles may differentiate.

*Group B.* Patients in whom aetiology is obscure form a much smaller group. The first case was reported by Haynes *et al.*<sup>6</sup> in 1941. No evidence of excessive androgenic or progestational stimulation has been noted. In many instances masculinization of the external genitalia has been associated with widespread and variable congenital abnormalities of other systems. This idiopathic variety is significant both from the point of view of its rarity and its pathogenesis, which remains an enigma.

We have recently investigated a case (infant L) which falls into this category.

### CASE REPORT

A 29-week foetus was born to a 21-year-old healthy White mother. The pregnancy was normal and at no time, as far as we could ascertain, did the mother receive any hormonal therapy. The father was a 33-year-old healthy White male.

Because of foetal distress early in the second stage of labour an episiotomy and forceps extraction were performed. The amount of amniotic fluid was not recorded. Examination of the infant showed abnormalities of the limbs and incomplete masculinization of the external genitalia which precluded sex assignment. The baby was markedly cyanosed and respiratory efforts were poor. In spite of energetic treatment the infant succumbed after 4½ hours.

As the possibility of intersex was suspected, blood smears were submitted to the laboratory for nuclear sex determination.

*Family history.* The father had 3 children by a previous marriage. The first and third are normal and healthy. The second child, a girl, had a severe atrial septal defect with marked pulmonary hypertension and died at the age of 2½ years. An autopsy was not performed and no further information concerning the cardiac lesions or the existence of associated congenital abnormalities was available. The patient was the first and to date the only child of the present marriage. On neither the paternal or maternal side of the family is there any history of abortions, stillbirths or deformed offspring.

*Laboratory investigations.* Examination of the blood smear showed the presence of 3 drumstick appendages per 100 polymorphonuclear leucocytes, which is consistent with the female pattern. Unfortunately chromosomal analyses of the infant's tissues were not performed. However both parents were investigated; the findings are presented below. Owing to the

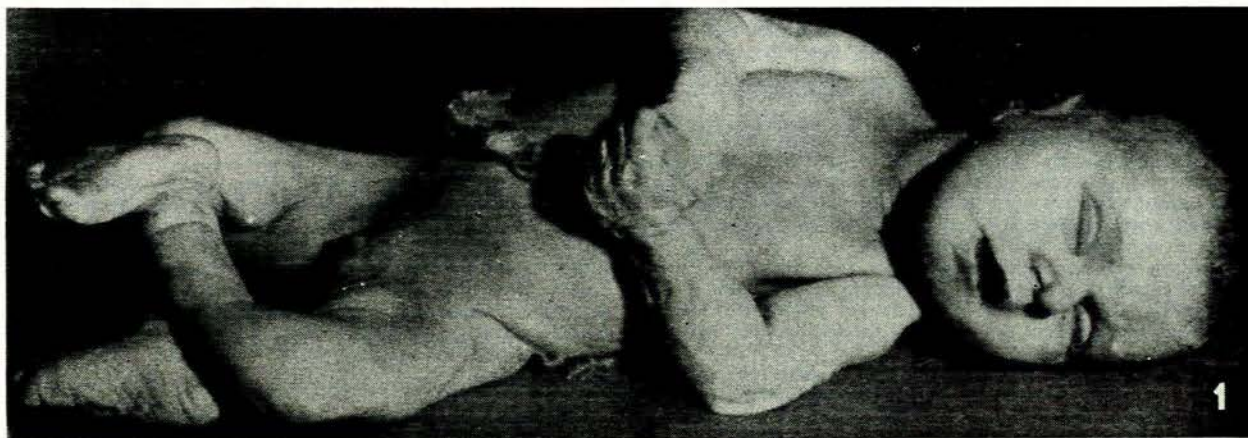


Fig. 1. Infant L.

rapid demise of the patient estimations of urinary 17-ketosteroids and pregnanetriol could not be performed.

#### Autopsy Findings

The baby weighed 5 lb. 9 oz. The face showed the abnormalities described by Potter<sup>7</sup> in association with severe renal-tract anomalies. The ears were low slung and the pinnae larger than normal. A prominent medial epicanthic fold was present and the bridge of the nose was somewhat depressed. The chin appeared to be slightly receding. The legs showed marked in-bowing and there was talipes equinovarus of the left foot (Fig. 1).

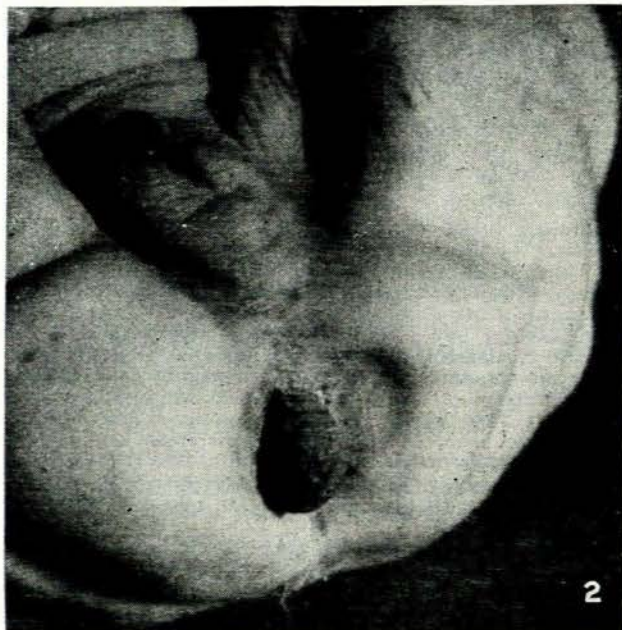


Fig. 2. External genitalia and anal skin tag (the apparently large size of the anal tag is due to photographic distortion).

The external genitalia were predominantly masculine. The phallus was enlarged, measuring 2 cm. in length. No glans or prepuce was present. A meatus was present at the tip, which was tentatively identified as the external opening of the urethra. This was later confirmed by tracing the urethra back to the thin-walled, tube-like bladder. There was complete fusion of the labioscrotal folds to form a scrotum-like structure (Fig. 2). No external vaginal orifice was found. Gonads were not located extra-abdominally. The anal orifice was normal except for a small skin tag on the outer lip.

When the abdomen was opened further extensive anomalies became evident. The right kidney and ureter were completely absent. The left kidney was present but situated ectopically at the level of the pelvic brim. The ureter was present on this side; it appeared hypoplastic but was patent and entered both the kidney and bladder normally. On macroscopic section of the kidney a number of cysts were seen embedded in a fibrous-looking stroma. Histological examination showed tubules and thin-walled cysts lying in a vascular fibrous stroma. This form of renal dysgenesis is well documented.<sup>8</sup>

The uterus was unicornuate, only the right side being present. The cervix was normally developed. The vagina terminated blindly and contained a translucent jelly-like material. No connection between the vagina, urethra or rectum was observed.

Both fallopian tubes were present. The right tube entered the uterus normally, but the left ended blindly in the connective tissue on the lateral aspect of the cervix.

Gonads were present in the normal ovarian position. Histological examination showed normal ovarian tissue. No testicular elements were noted in numerous sections taken (Fig. 3).

The lower bowel was normal except for a small area of thickening protruding into the anterior wall of the rectum 1 cm. proximal to the external anal orifice. Arising from this thickening was a minute diverticulum which merged into the surrounding connective tissue. Histological sections showed this pouch to be lined by a markedly stratified epithelium resembling that of the urethra.

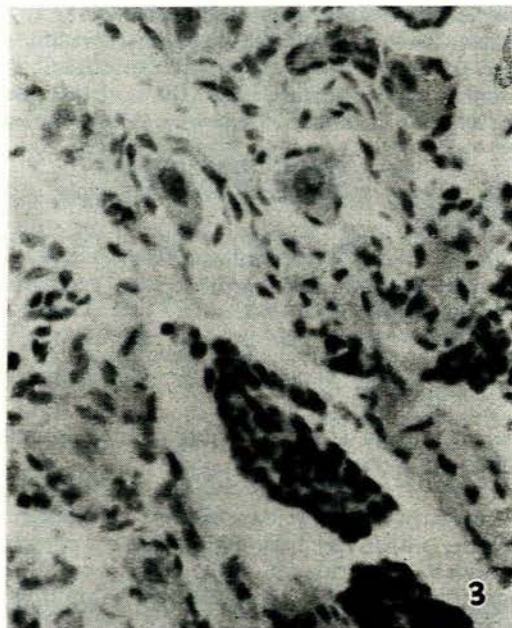


Fig. 3. Normal ovarian tissue.

The adrenals were circular and flattened in appearance. They were closely applied to the posterior abdominal wall on either side of the vertebral column at approximately the normal level. The abnormal shape is probably accounted for by the absence of mechanical pressure from the developing kidneys. Macroscopic and microscopic examination showed no evidence of adrenal hyperplasia.

The lungs were small, purplish and atelectatic. The alveoli were lined by relatively undifferentiated cuboidal epithelium.

No other congenital anomalies were found.

#### Chromosomal Analysis

Peripheral blood from both parents was cultured according to the modified method of Moorhead *et al.*<sup>9</sup> Table II supplies the detailed results.

TABLE II. CHROMOSOMAL ANALYSIS

	Under 45	45	46		47 and over	Total
			Counted	Anal.		
Father (1)	12	14	17	18	4	65
(2)	1	2	20	8	—	31
Mother	1	2	12	8	0	23

The karyotype of the mother proved to be that of a normal female 46/XX. In the first culture from the father about 40% of the metaphase plates counted showed aneuploidy. No constant abnormality was noted. In addition, in one metaphase plate morphological abnormalities of some of the chromosomes were observed. These showed breakages and apparent attachment between 2 chromosomes (Fig. 4). The second blood culture showed minimal aneuploidy and the karyotype was that of a normal male 46/XY (Fig. 5).

#### DISCUSSION

According to the classification this patient falls into group B, the idiopathic variety, which can be divided into 2 anatomical classes:

**Class I: Abnormal Sexual Development Only**

This includes patients in whom simple masculinization of the external genitalia has occurred, with, in some instances

has published a similar case (case 4) but with abnormalities of the fallopian tubes. A large umbilical hernia and interstitial fibrosis of the lungs together with masculinization was recorded by Perloff *et al.*<sup>12</sup>




Fig. 4. Mr. L. Metaphase plate.

the formation of a urogenital sinus. The morphological features of these cases are indistinguishable from those of female hermaphroditism caused by known androgenic stimulation, a fact which, among others, led Carpentier and Potter<sup>1</sup> to include them in their category of specific female pseudohermaphroditism. The number of reports falling into this category is extremely small.

**Class II: Abnormal Sexual Development and Other Congenital Anomalies**

This comprises patients in whom masculinization of the external genitalia has occurred in association with congenital anomalies of other organs, in particular the urogenital system. These cases show a marked variability with regard to their structural anomalies.

Jones and Scott<sup>2</sup> and Howard and Hinman<sup>10</sup> have both reported cases of female hermaphroditism with an enlarged phallus and vaginal and urethral urethrae. Armstrong<sup>11</sup>

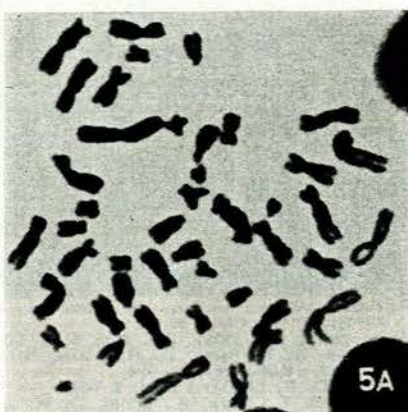


Fig. 5A. Mr. L. Metaphase plate. 46XY.

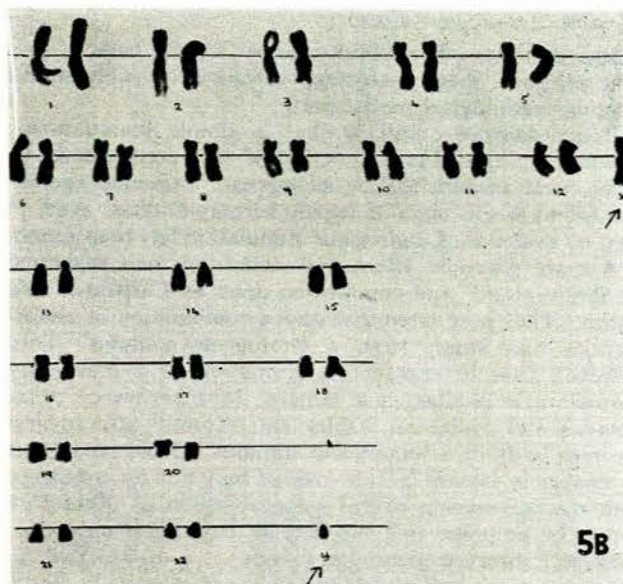


Fig. 5B. Mr. L. Karyotype plate.

In addition to the anomalies of the internal and external genitalia, many cases show extensive defects of the renal tract and other systems. Such reports have been published by Papadatos and Klein<sup>13</sup> (case 1), Atkinson and Masson<sup>14</sup> (case 3), Howard and Hinman<sup>10</sup> (case 2), Gross and Meeker<sup>15</sup> (9 cases), Sieber and Klein<sup>16</sup> (cases 1 and 2), Reilly *et al.*<sup>17</sup> (2 cases), Broster<sup>18</sup> (case 3), Carpentier and Potter<sup>1</sup> (4 cases), and Paquin *et al.*<sup>19</sup> Ashley and Mostofi<sup>8</sup> in a review of renal agenesis and dysgenesis mentioned that 5 of the females in the series had abnormal external genitalia. Although no further information was given it is possible that some, if not all, of these cases showed masculinization. Our case falls within this category.

The renal-tract anomalies reported have ranged from bilateral agenesis to variable degrees of unilateral dysgenesis, and have been extensively reviewed.<sup>8</sup> Abnormalities of the renal tract are frequently associated with anomalous facial development (Potter's facies), 'hypoplasia' of the lungs, and deformities of the lower spine and limbs. The case described by Broster<sup>18</sup> also showed extensive defects of the nervous system. It should be noted that all of the above anomalies may occur without masculinization of the external genitalia, which is a variable feature.

The anomalies of the external genitalia present a similarly heterogeneous morphological picture. Enlargement of the phallus usually has been more marked than in the other varieties of female hermaphroditism. The urethra has opened at the tip in the majority of reported cases. The labioscrotal folds have shown variable degrees of fusion to give a scrotum-like structure in many instances. Fistulae involving the urethra, vagina and rectum have been described, and Carpentier and Potter<sup>1</sup> stressed the fact that in all their cases variable degrees of imperforate

anus were present. Our case presents many of these reported features, but major defects of the bowel and defects and fistulae between the pelvic viscera were not noted.

#### Possible Aetiological Factors

It is important to establish whether, on the basis of present evidence, these anatomical categories possibly reflect different aetiological mechanisms.

It is extremely unlikely that a simple masculinizing stimulus acting at a critical period of intra-uterine development could account for the widespread congenital anomalies found in this class of female hermaphrodites. And, in fact, no evidence of androgenic stimulation has been found.

A more plausible alternative mechanism was suggested by Reilly *et al.*<sup>17</sup> and commented upon by Carpentier and Potter.<sup>1</sup> They postulated that such a combination of abnormalities may result from a teratogenic stimulus. This, however, fails to explain the formation of a practically normal male phallus in a female. In a review of renal agenesis and dysgenesis Ashley and Mostofi<sup>5</sup> also suggest the possibility of a teratogenic stimulus. Gross renal-tract anomalies in female infants may or may not be associated with masculinization of the external genitalia. Therefore it may be proposed that two distinct factors are operating. However, direct evidence in favour of a destructive 'in utero' force has not been reported. Furthermore, in case 4 of Carpentier and Potter<sup>1</sup> and that described by Perloff *et al.*<sup>12</sup> each propositus had a normal twin.

It would be equally plausible to postulate that these cases are the result of chromosomal abnormalities. Unfortunately chromosomal analyses have not been reported. There is however fairly good circumstantial and theoretical evidence to suggest a genetic mechanism. Carr<sup>20</sup> in a recent publication corroborates the findings of others with regard to a high incidence of chromosomal aberrations in abortions and stillbirths. It has been postulated that a single gene locus is responsible for meiosis,<sup>21, 22</sup> and therefore meiotic accidents of non-disjunction may be genetically determined. In such cases a family history of congenital malformations may be expected. The father of our case had a congenitally malformed infant in a previous marriage. No further suggestive family history could be elicited.

Chromosomal analysis of the paternal blood showed a high percentage of aneuploidy and occasional structural abnormalities in the first culture. Repeat cultures showed a normal male 46/XY karyotype. Although the abnormalities present in the first culture could possibly be due to *in vitro* conditions, they may reflect instability of cell division.

Nuclear sex determination of the infant's tissues was 'chromatin positive', a single Barr body of apparently normal size being present. This finding in association with morphological normally differentiated ovaries indicates a normal female sex chromosome complement XX, as found in female hermaphrodites of known aetiology (group A).

Multiple congenital abnormalities are present in the autosomal trisomy syndromes, i.e. trisomy 21/22, trisomy 17/18 and trisomy 13/15. Renal-tract defects have been reported but in no instance has there been renal agenesis, polycystic kidneys, or masculinization of the female genitalia. In addition many of the abnormalities described in

these syndromes were not noted in this patient.

If it is accepted that masculinizing genes are present on the autosomes and that sexual differentiation depends on a balance between autosomal sex genes and those on the sex chromosomes, the association of ambiguous sex differentiation and multiple congenital anomalies could be accounted for by an abnormality of one of the autosomes, which as yet has not been reported.

Although investigations of many individuals with congenital anomalies have revealed chromosomal alterations, many have not. With present techniques a minor structural defect may not be apparent. Then the possibility is also to be considered that alterations may affect a sequence of genes localized to a minute chromosomal segment. With further biochemical investigations as yet unidentified enzymatic defects indicative of abnormal foetal metabolism may be discovered.

It is possible that class I cases without congenital anomalies elsewhere are explicable by an entirely different aetiological mechanism. As pointed out above, their morphological features could be fully explained by the effects of androgen stimulation during a susceptible phase of external genital development.<sup>1</sup> In some of the reported cases the mother developed evidence of abnormal androgen metabolism during pregnancy.<sup>5</sup> However, the evidence to date remains only suggestive, indicating a line of investigation rather than establishing a pathogenetic mechanism. It is for this reason that these cases are included in the 'idiopathic' category.

#### SUMMARY

A case of female hermaphroditism with associated congenital abnormalities has been presented. The aetiology remains unexplained. Various hypotheses are discussed.

We wish to express our thanks to Dr. E. Wilton and the Cytogenetics Unit of the South African Institute for Medical Research, Mr. Ulrich of the Photographic Department of the South African Institute for Medical Research, and Mr. Shewitz of the Photographic Unit of the Department of Medicine of the University. We wish to thank Prof. B. J. P. Becker for facilities granted.

#### REFERENCES

1. Carpentier, P. J. and Potter, E. L. (1959): *Amer. J. Obstet. Gynec.*, **78**, 235.
2. Jones, H. W. and Scott, W. W. (1958): *Hermaphroditism, Genital Anomalies and Related Endocrine Disorders*. Baltimore: Williams & Wilkins.
3. Overzier, C. (1963): *Intersexuality*. New York: Academic Press.
4. Bongiovanni, A. M. and Root, A. W. (1963): *New Engl. J. Med.*, **268**, 1283, 1391.
5. Wilkins, L., Jones, H. W., Holman, G. H. and Stempfel, R. S. (1958): *J. Clin. Endocr.*, **18**, 559.
6. Haynes, E., Thomas, H. P. and Wheeler, M. S. (1941): *Med. Rec. (N.Y.)*, **154**, 307.
7. Potter, E. L. (1961): *Pathology of the Fetus and the Infant*. Chicago: Year Book Publishers.
8. Ashley, D. J. B. and Mostofi, F. K. (1960): *J. Urol. (Baltimore)*, **83**, 211.
9. Moorhead, P. S., Nowell, P. C., Mellman, W. J., Batipps, D. M. and Hungerford, D. A. (1960): *Exp. Cell. Res.*, **20**, 613.
10. Howard, F. S. and Hinman, F. (1951): *J. Urol. (Baltimore)*, **65**, 439.
11. Armstrong, C. N. (1955): *Brit. Med. J.*, **1**, 1173.
12. Perloff, W. H., Conger, K. B. and Levy, L. M. (1953): *J. Clin. Endocr.*, **13**, 783.
13. Papadatos, C. and Klein, R. (1954): *J. Pediatr.*, **45**, 662.
14. Atkinson, W. and Masson, J. C. (1934): *Surg. Clin. N. Amer.*, **14**, 571.
15. Gross, R. E. and Meeker, I. A. (1955): *Pediatrics*, **16**, 303.
16. Sieber, W. K. and Klein, R. (1958): *Ibid.*, **22**, 472.
17. Reilly, W. A., Hinman, F., Pickering, D. E. and Crane, J. T. (1958): *J. Dis. Child*, **95**, 9.
18. Broster, L. R. (1956): *Brit. Med. J.*, **1**, 149.
19. Paquin, A. J., Baker, D. H., Finby, N. and Evans, J. A. (1957): *J. Urol. (Baltimore)*, **18**, 796.
20. Carr, D. H. (1963): *Lancet*, **2**, 603.
21. Therman, E., Patau, K., Smith, D. W. and Dewars, R. I. (1961): *Amer. J. Hum. Genet.*, **13**, 193.
22. Hauschka, T. S., Hasson, J. E., Goldstein, M. N., Koepf, G. F. and Sandberg, A. A. (1962): *Ibid.*, **14**, 22.