

## A CASE OF APROSOPIA ASSOCIATED WITH ANENCEPHALY

MICHAEL LEARY,\* M.B., CH.B. (CAPE TOWN), D.A., D.C.H., D.OBST. (R.C.O.G.), *Jane Furse Memorial Hospital, Middelburg, Transvaal*

Anencephaly is the commonest foetal abnormality incompatible with survival, and the incidence has been given as 0.23% of all births.<sup>1</sup> Cyclopia in association with anencephaly is fairly common but association with aprosopia—failure of development of facial structures—appears to be rare enough to warrant the recording of the following case.

### *Case Report*

J.M., a 19-year-old White housewife, a primagravida, was first seen when 28-weeks pregnant. She had first felt foetal movements 4 weeks before. Her height was 168.75 cm; she weighed 66 kg. and her Hb. was 8.2 G/100 ml. Her blood pressure was 100/70 mm.Hg. The urine, serological tests and chest X-ray examination were normal and she appeared to be in good health.

She was next seen 4 weeks later when the urine and blood pressure were again normal, but her weight had increased by 3.5 kg. and the height of the uterine fundus was greater than that expected for the estimated period of gestation. There was evidence of slight hydramnios.

Twelve days later the patient was admitted to hospital in labour. The uterus was enlarged to the level of the xiphisternum and there was marked hydramnios. A normal first stage was followed by the rapid delivery of the anencephalic

monster which forms the basis of this report. Immediately after delivery the apex beat was palpable and the infant was observed to make inspiratory movements of the chest. After 2 minutes the heart stopped. Birth-weight was 1 kg. and the length 40 cm.

### *Autopsy Report*

Dr. H. Caplin reported: 'An anencephalic monster of most unusual type. The "head" is partly macerated, extremely small and so grossly distorted as to make it impossible to determine the landmarks with any degree of certainty (Fig. 1). There is no mouth or nose, the ears being fused together in the anterior midline; the right eye and orbit are just definable but the vault is open with soft red granular tissue projecting through it and the flat membrane bones (?parietal, ?occipital) are incompletely fused posteriorly.'

*Internal examination.* 'Neither tongue nor epiglottis can be identified. Thyroid and hyoid bones not found. Lower part of trachea and main bronchi normal. Lungs airless. Oesophagus and stomach normal. Heart normal except for patent foramen ovale and ductus arteriosus. Intestines normal.'

*X-ray examination (Fig. 2).* Postmortem radiographs of the child show that the general skeletal structure is essentially normal. The skull, however, shows marked abnormality. The medial growth of the mandible appears to have been arrested at an early stage and maxillary and nasal bones are absent, so that the sphenoid and petrous temporal bones are well seen. There is evidence of ossification of the medial wall of the right

\*Formerly House-surgeon at the Thorpe Coombe Maternity Hospital, Walthamstow, London, E17.

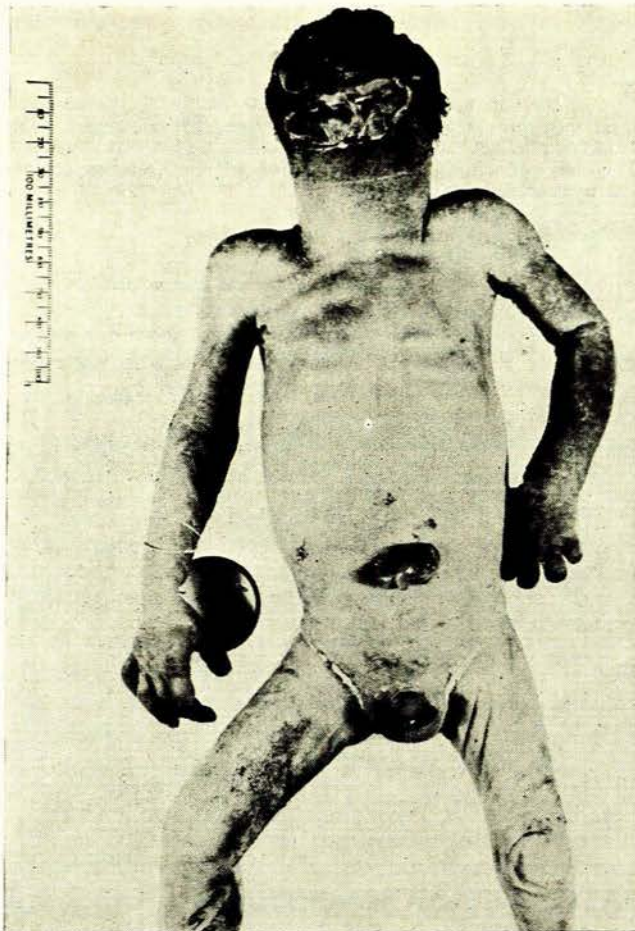

Fig. 1. Features of a case of aprosopia associated with anencephaly are shown.

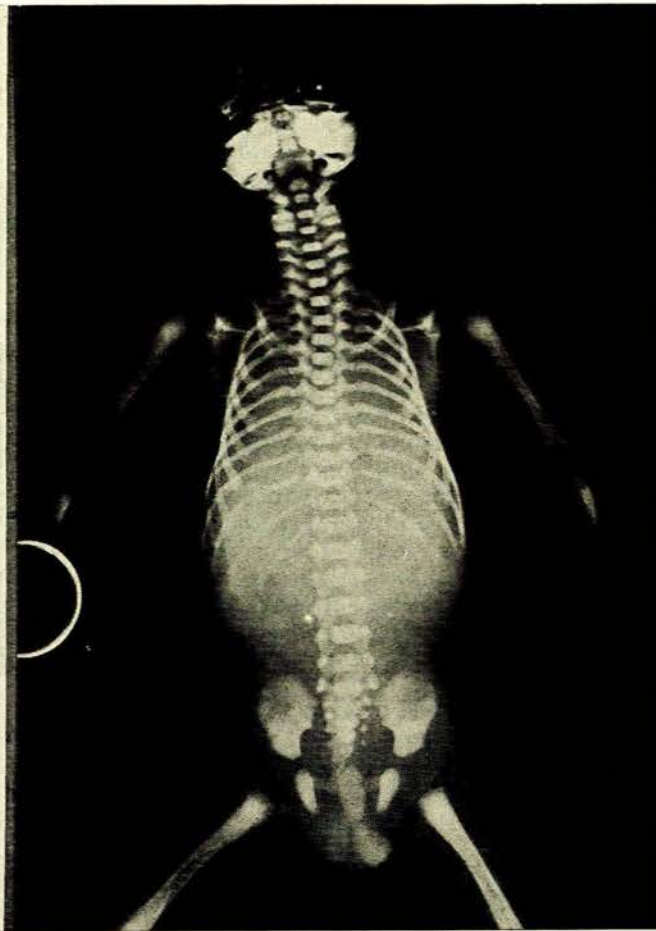


Fig. 2. Postmortem X-ray appearance indicating that general skeletal structure is normal.

orbit, and the lateral view shows the failed development of the flat membrane bones of the skull.

#### DISCUSSION

This case appears to resemble Chidterter's dog<sup>3</sup> as described by Willis,<sup>1</sup> which had no cerebrum or third ventricle, but only a rounded knob-like fused thalamic mass below which the brain stem was well formed. The external ears were fused in the anterior midline and the pharyngeal cavity was closed anteriorly. In a case described by Ballantyne,<sup>2</sup> the ears were separated laterally, presumably indicating development to a slightly later stage. Eyes, nose and mouth were absent.

The early weeks of the mother's pregnancy were, as far as could be ascertained, normal. She had felt well and had not taken any drugs. There was no family history of congenital abnormality. It was not possible to undertake chromosome studies.

#### BOOKS RECEIVED : BOEKE ONTVANG

*A Guide to Diseases of the Nose, Throat and Ear.* For general practitioners and students. By E. G. Collins, M.B., Ch.B., F.R.C.S.E. Pp. viii + 359. Illustrated. R3.60. Edinburgh and London: E. & S. Livingstone. 1964.

*Child Health in the Tropics.* 2nd ed. Ed. by D. B. Jelliffe, M.D., F.R.C.P., F.A.P.H.A., D.C.H., D.T.M. & H. Pp. v + 152. 90c. London: Edward Arnold Publishers. 1964.

*The Zymogram in Clinical Medicine.* By S. H. Lawrence, M.D. Pp. xvii + 100. Illustrated. \$5.75. Springfield, Ill.: Charles C. Thomas. 1964.

*The Clinical Examination of the Nervous System.* 12th ed. By G. H. Monrad-Krohn, M.D.(Oslo), F.R.C.P.(Lond.) Pp. xii + 474. Illustrated. R4.50. London: H. K. Lewis. 1964.

#### SUMMARY

An anencephalic foetus is described in whom facial structures were absent and the ears fused in the anterior midline. Details are given of the pregnancy and subsequent postmortem examination.

I am indebted to Dr. H. Caplin who conducted the post-mortem examination; to Dr. D. Bryson for permission to publish the case; and to Mr. C. Gurney, who took the photographs.

#### REFERENCES

1. Willis, R. A. (1958): *The Borderland of Embryology and Pathology*, 1st ed., pp. 148 and 168. London: Butterworths.
2. Ballantyne, J. W. (1904): *Manual of Antenatal Pathology and Hygiene*, Fig. 67, Edinburgh: Green and Company.
3. Chidterter, F. E. (1924): *Anat. Rec.*, **28**, 15.