

PROBOSCIS LATERALIS: A RARE FACIAL ANOMALY

T. COETZEE, M.CH. (CAPE TOWN), F.R.C.S. (ENG.), F.C.S. (S.A.), *Pietermaritzburg*

Proboscis lateralis, a congenital malformation in which a part of the nose is represented by a trunk-like appendage suspended from the upper and inner wall of the roof of the orbit, is one of the rarest of facial anomalies. The earliest recorded case is that described by Selenkoff¹ in 1884. A small number of cases have since been reported, the most recent being those of Biber² and Nessel.³

Case Report

A 9-year-old African male attended in the outpatient department at Edendale Hospital, Pietermaritzburg, in February 1959. An abnormality of the face had been present since birth. No medical advice had been sought previously. He stated that a small amount of clear mucoid fluid flowed from the opening in the appendage and that he could blow air through it. The left eye lacrimated excessively. No other member of his family showed similar or other malformations.

On examination he was found to be in good health and there was no physical abnormality apart from the facial abnormality. The right half of the nose was normal. The left side was deficient. A shallow pit was present just to the left of the upper end of the philtrum. Suspended from the roof of

the orbit, just above the inner canthus of the left eye, on a narrow pedicle, was a soft appendage reaching down to the level of the lower nasal margin and presenting in the centre of its bulbous tip a rounded opening with a drop of clear mucoid fluid in it (Fig. 1). Slight independent muscular contraction could be seen in the appendage, especially on contracting other facial muscles. The left eye was watery and pressure just medial to the inner canthus produced a regurgitation of clear fluid into the conjunctival sac. Both lacrimal puncta were present in the normal position. The upper lip and teeth appeared normal.

X-ray of the skull and sinuses showed absence of the nasal bones. The nasal septum was present. Ethmoidal cellulae were visible on the right side only. Frontal buds were just appearing. The antral regions were both opaque. An injection of lipiodol into the cavity of the appendage showed the opaque medium to penetrate only as far as its base. A probe could not be passed beyond the frontal bone. However, following the examination, slight blood-staining was noticed in the nasopharynx. On digital palpation the left posterior naris was considered to be imperforate. A lacrimal probe entered both lacrimal canaliculi as far as the lacrimal sac; no nasolacrimal duct could be demonstrated.

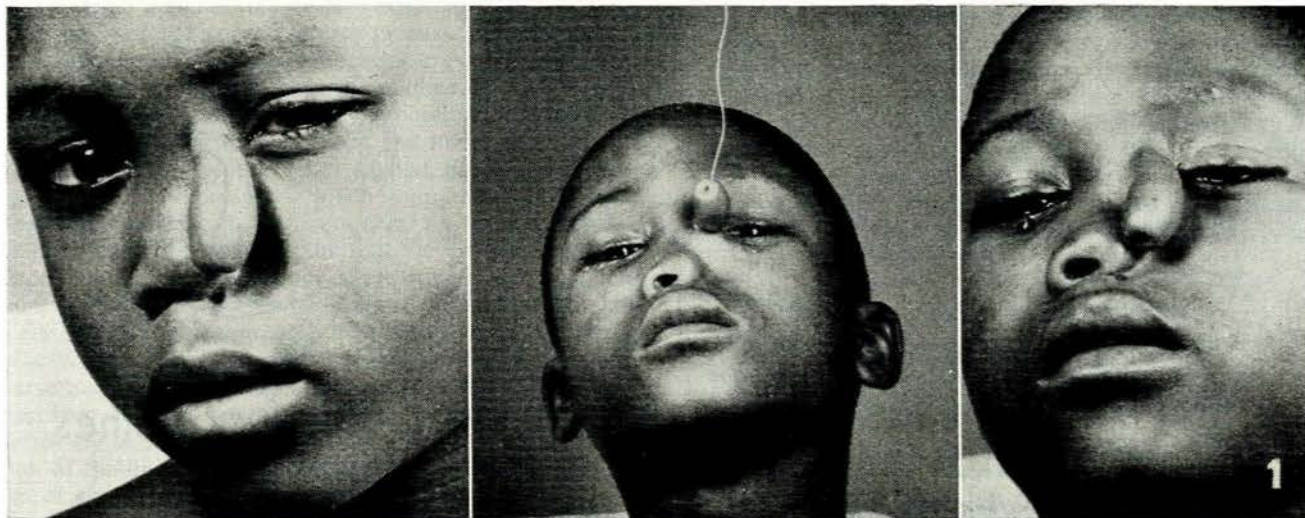
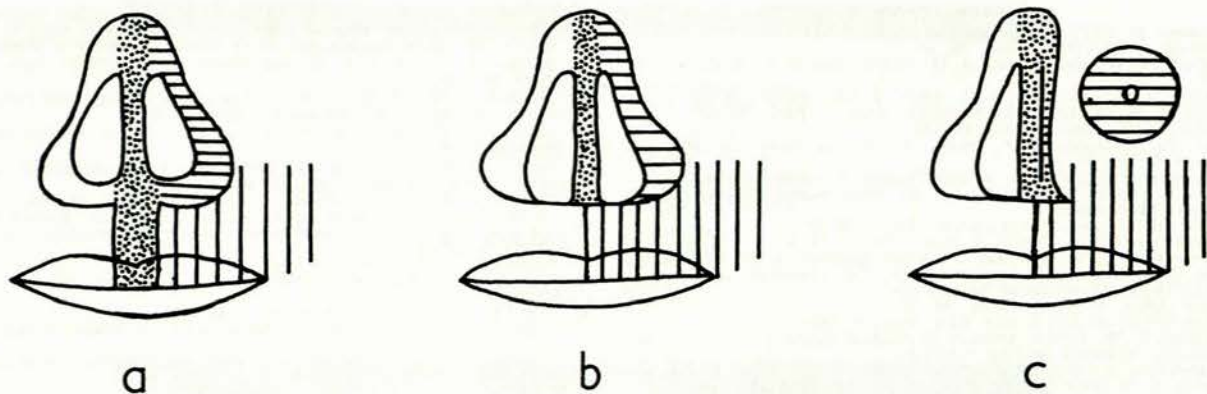


Fig. 1. Photographs of the patient showing the characteristic deformity in proboscis lateralis.



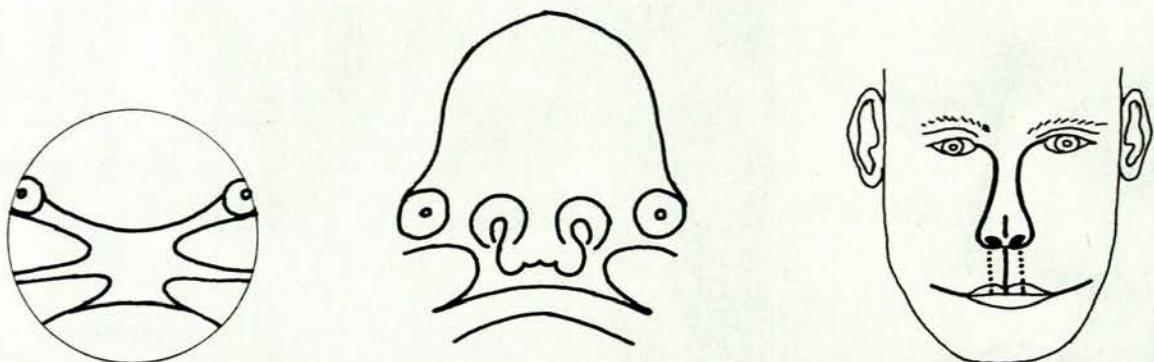
···· medial nasal process
 ≡ lateral nasal process
 ||| maxillary process

2

Fig. 2. See text.

Proboscis lateralis has been considered to fall within the large group of malformations of the face known as arhinencephaly, described by Professor Kundrat⁴ in 1882 as showing the following characteristics: at least partially separate orbital cavities, a trunk-shaped or similar deformity of the nose, based against the forehead in the region of the root of the normal nose and pointing downwards, skull usually small, with abnormal development of the forebrain and olfactory and optic nerves. Prior to 1882 Otto (quoted by Kundrat⁴) gave an incomplete description of a case with a nasal deformity as follows: 'naris sinistrae nullum vestigium adest, in sinistro latere nullum nasi cavum reperitur, cujus locum massa quaedam cartilaginea occupat . . .' As there was no trunk-like appendage in this case of Otto's and as, in addition, deformities of the ears and brain were present, it could probably not be accepted as a true example of proboscis lateralis.

Selenkoff¹ gave the first detailed description of a patient showing the characteristic deformity which he named unilateral arhinencephaly. His patient, a 34-year-old Finnish farmer, died in hospital and a necropsy was performed. He found ' . . . die rechte Nasenhälfte durch ein vom inneren oberen Rande der Orbita herabhängendes, weiches, rüssel-förmiges Gebilde ersetzt, welches durch die am unteren abgestumpften Ende vorhandene feine Öffnung bis zum Wurzel für eine Sonde durchgängig ist und bei Druck eine dünne schleimige Flüssigkeit mit Luftblasen ausströmen lässt . . .' His patient stated that the appendage grew with him. There was no philtrum. The canal of the appendage ended blindly against the frontal bone. The right posterior naris was represented by a blind depression. There were no lacrimal puncta. The right olfactory bulb was rudimentary. The right lateral mass of ethmoid, the lamina cribrosa, and the right frontal sinus, nasal bone, maxillary



a. The five processes from which the face develops.

b. Formation of the medial & lateral nasal folds.

c. The fusion lines of the face.

3

Fig. 3. See text.

antrum and vomer, were absent. A rudimentary lacrimal sac, blind at both ends, was present.

The appendage is invariably suspended from the upper and inner wall of the roof of the orbit. The canal ends blindly at the proximal end and has no connection with the incompletely developed nasal cavity on the affected side. Other associated abnormalities that have been reported include absence of an upper incisor tooth, coloboma of the iris, and cleft of the lower eyelid.² Histological examination of the appendage shows skin with sebaceous glands, striated muscle, and connective tissue, while the central canal is lined with stratified columnar epithelium proximally, and distally shows small hairs and sebaceous and sweat glands.

Embryology

The face develops from 5 processes:^{5, 6} the frontonasal process (the expanding mesenchyme between the floor of the forebrain and the roof of the mouth, with its covering ectoderm), the 2 maxillary processes (usually regarded as the rostral extension of the first branchial arch, although a separate origin of the maxillary process from the mesenchyme in the region of the nasal capsule has been inferred from a study of cases of agnathia,⁷ and the 2 mandibular processes (the caudal extension from the first branchial arch) (Fig. 2a). After the formation of the olfactory placodes in the fifth week, their progressive invagination (to form the olfactory pits) indents the stomodaeal border of the frontonasal process and divides it into lateral and medial nasal folds (Fig. 2b). The lateral nasal process is at first separated from the ventrally-growing maxillary process by the naso-optic furrow. With the fusion of these 2 processes, a solid cord of thickened ectoderm sinks into the mesenchyme. The central cells of this cord break down during the third month; in this way the nasolacrimal duct is formed. The proximal slightly dilated end of the nasolacrimal duct is the lacrimal sac and the lacrimal canaliculi arise as buds from this part, later establishing openings (the puncta lacrimalia) on the margins of the eyelids. The median nasal process projects caudally beyond the lateral fold and the mesenchyme of this extension proliferates to form the globular (premaxillary) process. The tips of the ventrally-growing maxillary processes cross the lower end of the olfactory pit to meet in the midline. In this way the fused lateral nasal and maxillary processes form the floor of the primitive nasal cavity and the lower extension of the median nasal process (the globular process) is buried by the maxillary processes, which form the whole of the upper lip, including the philtrum (Fig. 2c). This is the view of Boyd and Frazer, who claim that the innervation of the upper lip from the maxillary nerve supports this contention. By those, however, who support the view of His and Keith that the philtrum is formed wholly by the globular process, it is suggested that the distribution of a sensory nerve may not be a reliable indication of the migration of maxillary process mesenchyme. The lateral nasal process forms the side of the nose and takes no part in the formation of the upper lip. The median nasal process forms the tip of the nose, the septum of the nose (down to and including the columella) and the premaxilla. The ethmoid forms the skeleton of the nasal capsule.⁸ Its median part

forms the septum of the nose (remaining cartilaginous distally, and forming the perpendicular plate of the ethmoid proximally) and its lateral part forms the ethmoidal air cells and the upper and middle turbinate bones.

Discussion

On the basis of the nature of the deformity in proboscis lateralis, and correlating this with the facts known about the development of the face, the anomaly would appear to be the result of failure of the lateral nasal process on one side to fuse with the median process and with the maxillary process. This is Biber's opinion² (Fig. 3a). As Biber accepted the His-Keith interpretation of the embryological development of the face, this diagram has been redrawn to show the Boyd-Frazer view (Fig. 3b), while Fig. 3c shows the abnormal situation that exists in proboscis lateralis.

As a result of the separate development of the lateral nasal process, abnormal contact and fusion now occur between the maxillary process and the median nasal process. Abnormality in the formation of the frontonasal duct might therefore be anticipated. This has been present, in varying degrees, in the reported cases. Because the lateral nasal process now takes no part in the formation of the normally-situated nose, the nasal cavity on the affected side is either absent or vestigial. This is true also of the air sinuses normally in communication with the nasal cavity and the skeleton of the nasal capsule—chiefly the ethmoid bone.⁹ The absence of the cribiform plate and the rudimentary nature of the olfactory bulb could be explained on this basis. No abnormality of the nasal septum or the upper lip is to be expected, since the lateral nasal process has no part in the formation of these structures.

The shallow pit present above the upper lip in the case here reported, and clearly seen in Biber's case, represents partial formation of the primitive nasal cavity, incomplete because there is no fusion of the maxillary with the lateral nasal process in this region.

Histological examination of the appendage reveals the tissues present in the normal nose. This includes striated muscle (which explains the presence of independent muscular contraction in this case). The nature of the tissue and its liberal blood supply also suggest that the appendage itself would be the ideal 'graft' to use in repairing the defect of the nose. Its removal has been advised, e.g. by Keith,¹⁰ who suggested removal of the ipsilateral eyeball as well, to avoid the formation of fistulous communication with the inside of the skull which might lead to subsequent meningeal infection. It is now known that the canal of the appendage does not extend into the cranium.

REFERENCES

1. Selenkoff, A. (1884): *Virchows Arch. Path. Anat.*, 95.
2. Biber, J. J. (1949): *J. Laryng.*, 63, 734.
3. Nessel, E. (1958): *Hals-, Nas.- u. Ohrenarzt*, 7, 25.
4. Kundrat (1882): *Loc.cit.*¹
5. Johnston, T. B., Davies, D. V. and Davies, F., eds. (1958): *Gray's Anatomy*, 32nd ed. London: Longmans, Green & Co.
6. McGregor, A. L. (1957): *A Synopsis of Surgical Anatomy*, 8th ed. Bristol: John Wright.
7. Muller, T. (1952): *S. Afr. Med. J.*, 26, 511.
8. *Idem* (1957): *Med. Proc.*, 3, 398.
9. Shanks, S. C. and Kerley, P., eds. (1957): *A Textbook of X-ray Diagnosis*, 3rd ed., vol. 1. London: H. K. Lewis.
10. Keith, A. (1947): *Human Embryology and Morphology*. London: Edward Arnold.