

INTRACRANIAL MENINGIOMA IN A 13-YEAR-OLD MALE

M. J. JOUBERT, M.B., F.R.C.S.E.; KELMAN DRUMMOND, M.B., F.R.C.P.E.; ANSUYAH SINGH, M.B., CH.B., D.P.H. (EDIN.), AND A. MOHLAKA, M.B., CH.B. (NATAL), *Department of Medicine, Medical School, University of Natal, Durban*

This case demonstrates the presence in a young child of a large intracranial meningioma showing minimal localizing signs clinically, but with the patient deteriorating progressively into a comatose state.

Case History

The patient a male scholar, aged 13 years, was admitted to hospital complaining of right-sided headaches of 3 weeks' duration becoming progressively worse. There had been occasional fits.

Previous history. There was an episode when he had been butted on the forehead by a ram at the age of 6 years. This caused a large swelling which later subsided.

On examination, he was malnourished, afebrile, had a large head, and neck rigidity was present. Bilateral papilloedema was noted, but his cranial nerves were intact. Motor power and tone of the limbs were normal and equal on both sides. All reflexes were present and equal. No abnormalities of the sensory system were found. Coordination was difficult to test.

The chest was clear clinically and on X-ray. The cardiovascular system showed a pulse of 64/min., regular and of good volume; the heart sounds were closed; BP was 100/160 mm.Hg. No masses were felt on abdominal examination. Liver, spleen and kidneys were not palpably enlarged.

An X-ray of the skull showed widening of the coronal sutures. No intracranial calcification or erosion was noted. A diagnosis of increased intracranial pressure, probably owing to hydrocephalus, was made.

Two days later he was seen by the neurological surgeon, who suggested ventriculography and bilateral carotid angiography.

The patient became increasingly drowsy, had attacks of vomiting and the neck rigidity became extreme, to the extent of opisthotonos. In view of the rapid deterioration, the absence of lateralizing signs and the possibility of tuberculous meningitis, a lumbar puncture was performed—proper precautions having been taken to deal with any complications arising out of this procedure. CSF was clear and under pressure.

Laboratory examination showed no cells present; protein 16 mg./100 ml.; globulin not increased; chloride 780 mg./100 ml.; sugar 73 mg./100 ml.

Blood examination showed a Hb of 13.6 G/100 ml., white blood counts of 7,000/cu.mm. and blood sedimentation rate of 24 mm./hr.

Subsequent investigations. On the fourth day after admission urgent ventriculography was done under general anaesthesia. A brain biopsy done during this procedure showed normal tissue.

The ventriculogram showed ventricular dilatation and gross displacement of the lateral ventricular system from right to left. The third ventricle also appeared displaced and the findings suggested a large right-temporal or temporo-parietal tumour.

The next day a right carotid angiogram was performed showing anterior and middle cerebral vessels displaced markedly upwards and to the left, there being some herniation of the terminal branches of the anterior cerebral artery underneath the free ends of the falx. The pericollous branches of the anterior cerebral artery appeared stretched over a dilated lateral ventricle. The posterior temporal branch of the right middle cerebral artery was displaced laterally and the choroidal artery appeared to be displaced medially and slightly downwards. No pathological vessels or arterio-venous shunts were noted. The appearances were those of a large avascular space-occupying lesion in the right temporo-parietal region. This confirmed the appearance of a provisional diagnosis of a large hydatid cyst or porencephalic cyst (Figs. 1-4). It was decided to proceed with a craniotomy.

Operation—Craniotomy

The lesion was approached through a liberal right temporo-parietal osteo-plastic flap. The dura mater was found to be under extreme tension, and a brain cannula introduced into the lesion failed to get into the cyst. The lateral ventricle was entered with the brain cannula and 40-50 ml. of cerebrospinal fluid was allowed to escape. The dura mater was then opened and a large surfacing bluish tumour was encountered, extending from the temporal to the parietal region, measuring 11 cm. × 16.5 cm. The tumour was easily freed from its bed and it was noted that there was only a small attachment to the extent of half an inch to the dura mater of the sphenoidal ridge. The tumour was removed *in toto* and the attachment to the dura mater was cauterized. The dura mater was then closed and the bone flap was replaced.

The postoperative course was uneventful and the patient was discharged from hospital after 6 weeks.

At the time of discharge he was symptom-free, intellectually normal and no abnormal physical signs were present. The papilloedema was disappearing. Subsequent follow-up for the

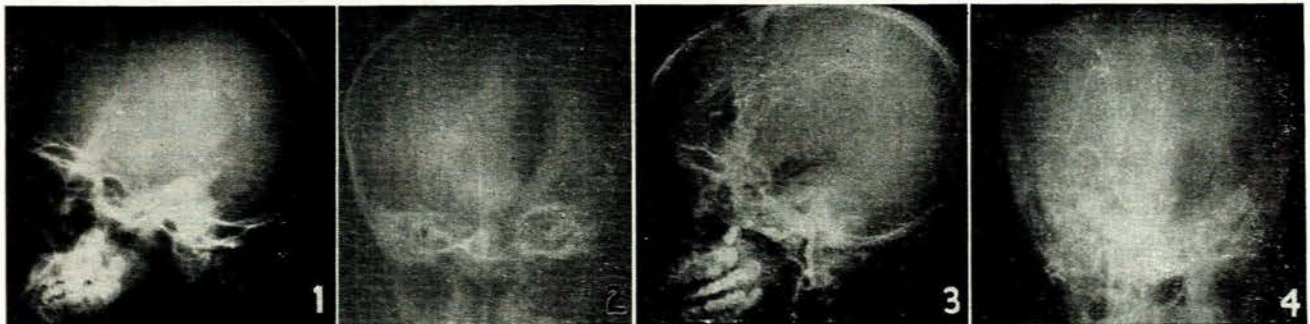


Fig. 1. Plain lateral radiograph of skull demonstrates sutural diastasis mainly of the coronal sutures. Fig. 2. P-A view of ventriculogram demonstrating a gross displacement of the lateral ventricles and the third ventricle to the left. Fig. 3. Right cerebral angiogram, lateral position, demonstrating the upward displacement and compression and stretching of the middle cerebral group of vessels with some downward displacement of the posterior cerebral artery. Fig. 4. Right cerebral angiogram, A-P position, demonstrating gross displacement of middle cerebral group of vessels in a medial direction with moderate displacement of anterior cerebral artery across the mid-line to the left side and some downward displacement of the posterior cerebral artery.

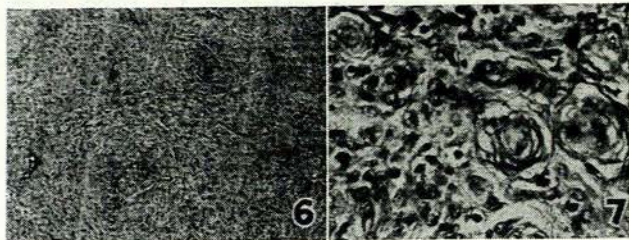
duration of 1 year showed that he was symptom-free and had returned to school.

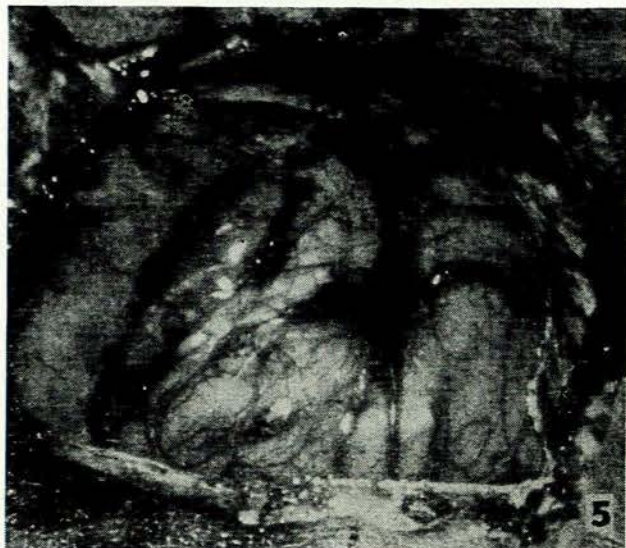

Fig. 5. The tumour as it appeared at operation.

Pathology

Histological sections showed a fibroblastic type of meningioma with occasional psammoma bodies (Figs. 6, 7).



Figs. 6 and 7. Histological appearance of tumour.

DISCUSSION

The literature on brain tumours indicates the rare occurrences of intracranial meningioma in the young. In a series analysed by Baker¹ the commonest incidence was in the second decade. The tumours are commonly large and present with minimal neurological signs in children as a result of compensatory head enlargement through separation of the sutures. Dekaban² stated that the diagnosis in the young age group is often made late when the tumour

had attained a large size and operative risks were considerable.

This patient presented with the classical triad of raised intracranial pressure—headache, vomiting and papilloedema. The minimal lateralizing signs presented in this case confirm the experience of Teng³ who, in reviewing the literature, commented upon several unusual features of intracranial meningioma in children, which were:

- (a) Enlargement of head—which may be markedly enlarged with minimal neurological signs,
- (b) The tendency to recurrence of growth,
- (c) Higher incidence of sarcomatous change than in adults,
- (d) Lack of dural attachment, and
- (e) High operative mortality.

Cushing and Eisenhardt⁴ in a series of 284 intracranial meningiomas (1938) quote 6 occurrences in the pre-adolescent age group. Cushing contends that meningiomas are the most favourable of all intracranial tumours for surgery, but present a problem for successful removal because of the large size, the great vascularity and the tendency to recurrence.

There is usually a long history of symptoms before the initial examination, but Pineda and Coe⁵ described 4 cases with rapid progression to a comatose state, with absent lateralizing signs and stressed the need to bear the diagnosis in mind when an individual is admitted to hospital in a comatose state.

An interesting finding in this case was the normal cerebrospinal fluid protein, which contrasts strikingly with the high figure for this entity commonly found.

SUMMARY

1. This case illustrates a large intracranial meningioma in a 13-year-old male.
2. Minimal neurological signs existed in spite of the large tumour mass.
3. The patient deteriorated rapidly to a critical state.
4. The tumour was removed successfully.

We thank Dr. T. E. Adnams, Superintendent of King Edward VIII Hospital, for consent to use the hospital records of the case; Prof. J. Wainwright, Department of Pathology; and Dr. H. E. Engelbrecht, of the Department of Radiology. Finally we thank Messrs. Abbotts for the filming of the operation and the photographs.

REFERENCES

1. Baker, A. B., ed. (1962): *Clinical Neurology*, 2nd ed., vol. 1, p. 495. New York: Hoeber.
2. Dekaban, A. S. (1959): *Neurology of Infancy*, p. 307. Baltimore: Williams & Wilkins.
3. Teng, P. (1961): *J. Neurol. Neurosurg. Psychiat.*, **24**, 379.
4. Cushing, H., ed. (1938): *The Meningiomas—Intracranial Tumours*. Springfield: C. C. Thomas.
5. Pineda, A. and Coe, J. E. (1961): *Tex. Rep. Biol. Med.*, **19**, 625.